

Systemic Module

MSS

“Anatomy”

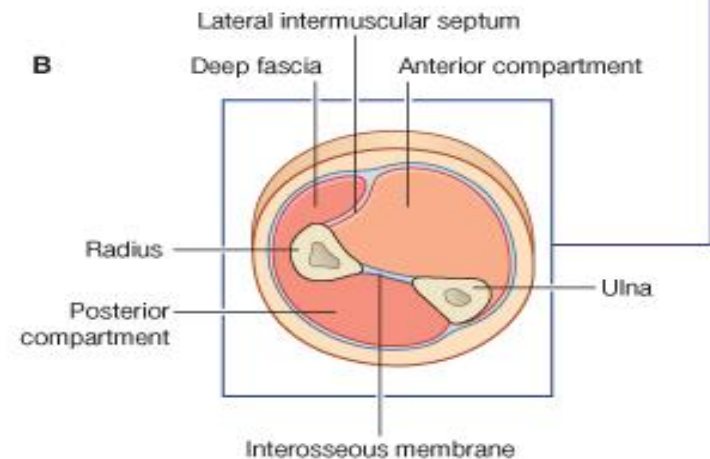
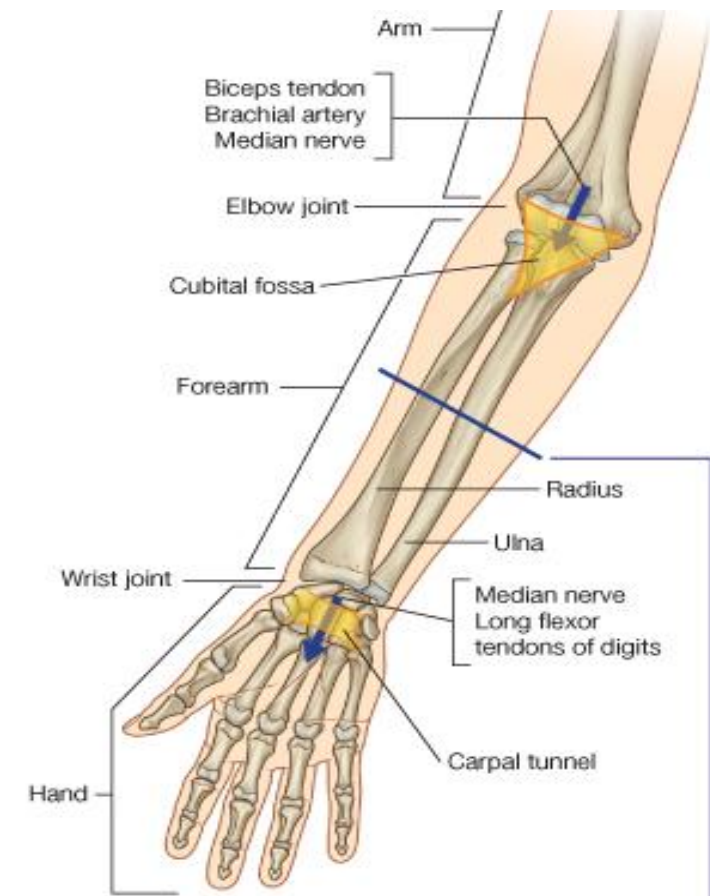
Muscles of Forearm

Dr. Ayman Alzubi

Faculty of Medicine, Yarmouk University

Compartments of Forearm

- The forearm is divided by the interosseous membrane and lateral intermuscular septum into:
 - **Anterior compartment:** contains muscles that predominantly **flex the hand and fingers**.
 - **Posterior compartment:** contains muscles that predominantly **extend the hand and fingers**.



Muscles of Anterior Compartment (Flexor compartment)

- General features for muscles of anterior compartment:
 - **Superficial** and **Deep** layers
 - **Flexors** of hand and fingers
 - Most flexors have common origin on **medial epicondyle**
 - Contains 2 **pronator** muscle

Superficial layer:

1. Pronator Teres
2. Flexor Carpi radialis
3. Palmaris Longus
4. Flexor Carpi ulnaris
5. Flexor Digitorum Superficialis

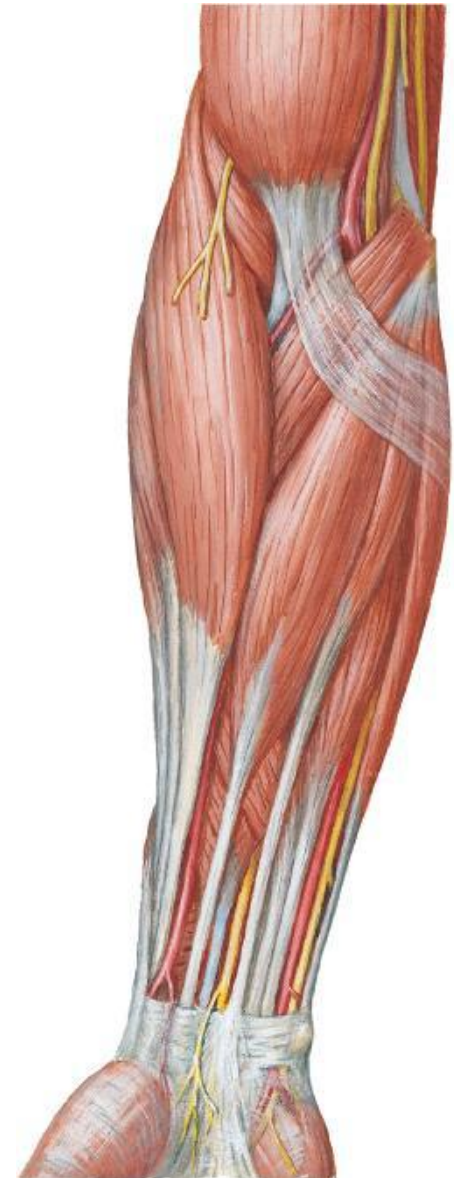
Deep layer:

1. Flexor Pollicis Longus
2. Flexor Digitorum Profundus
3. Pronator Quadratus

Nerve supply

Median
Median
Median
Ulnar
Median

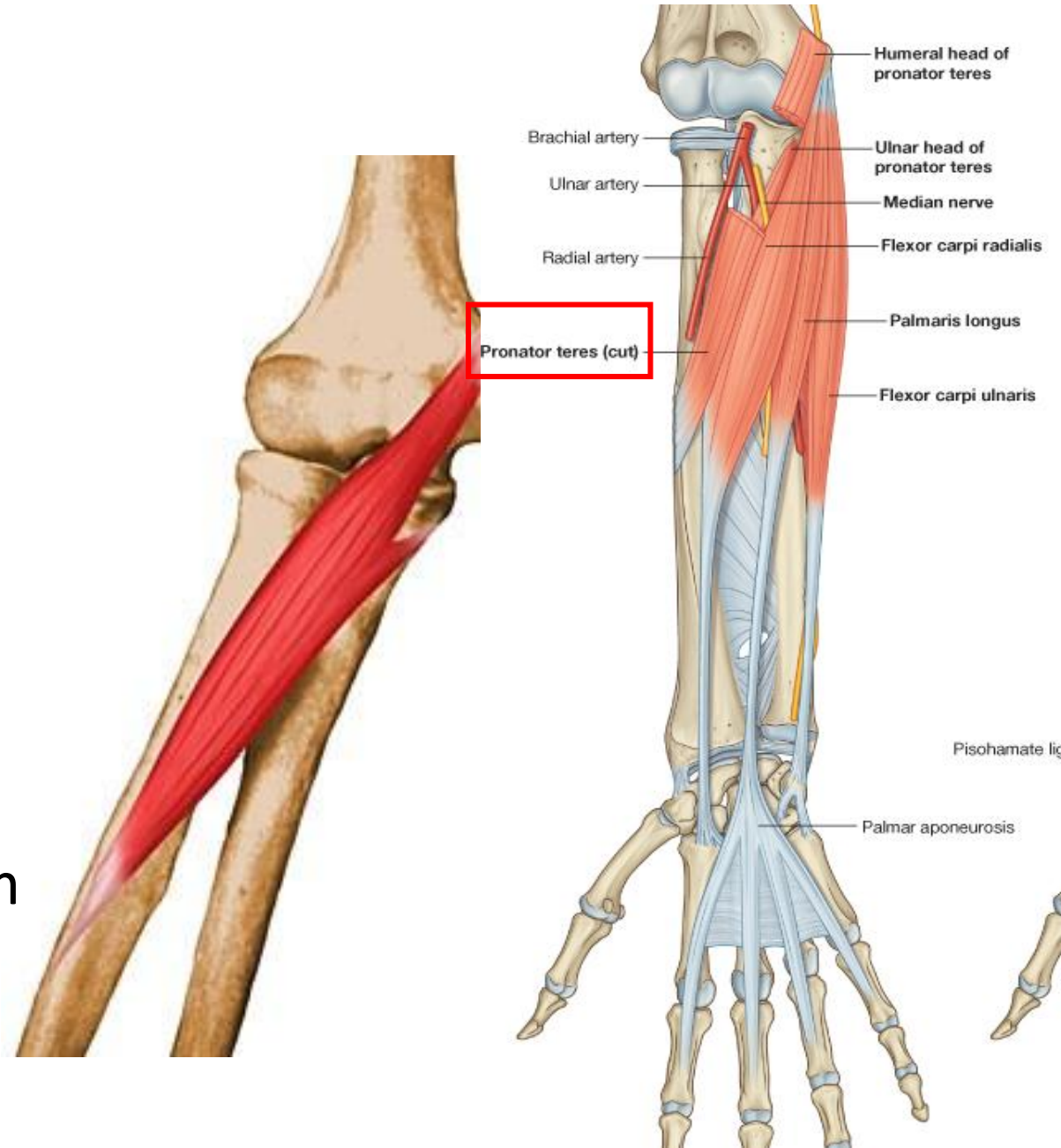
Median
1/2 ulnar, 1/2 median
Median



Superficial Layer:

Pronator Teres

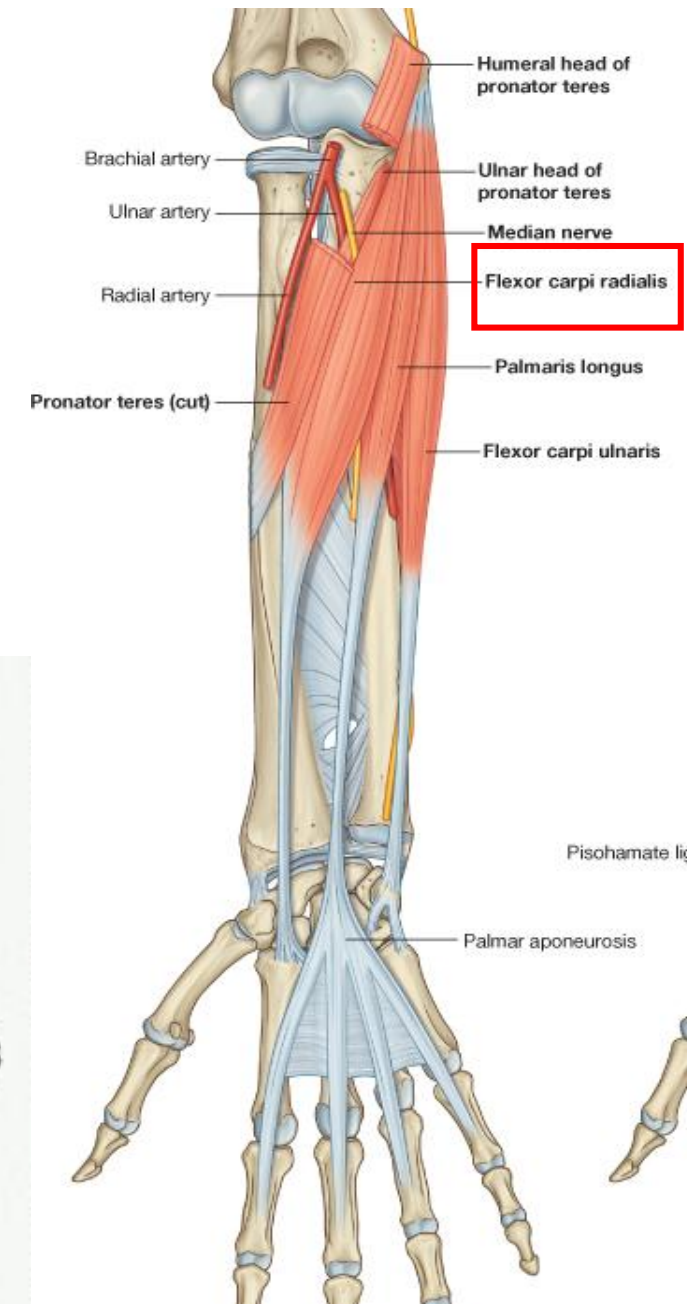
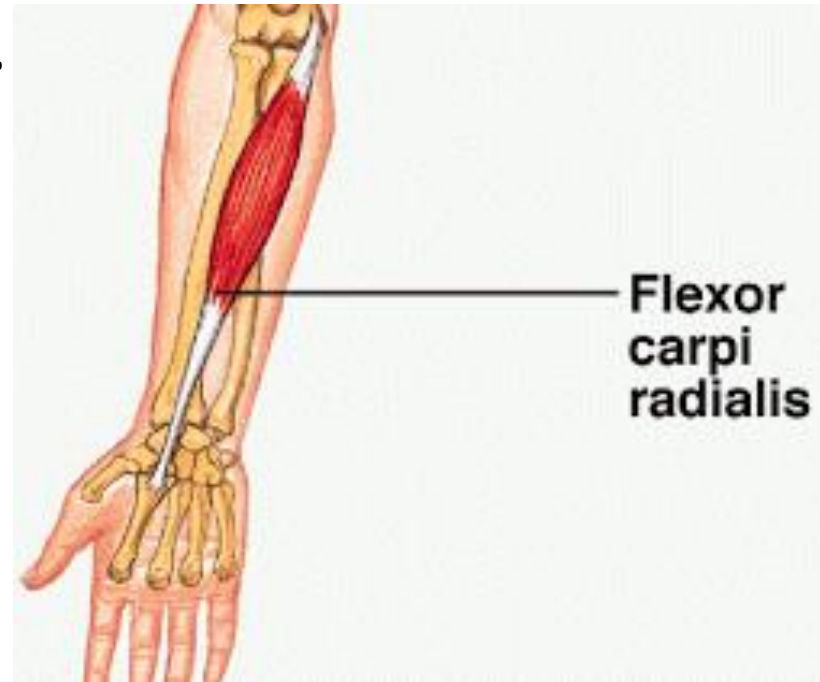
- **Origin:**
 - Humeral head: medial epicondyle
 - Ulnar head: Medial border of coronoid process
- **Insertion:** Midway long the lateral surface of the radius
- **Action:** Pronation and flexion of forearm
- **Nerve supply:** Median nerve.



Superficial Layer:

Flexor Carpi Radialis

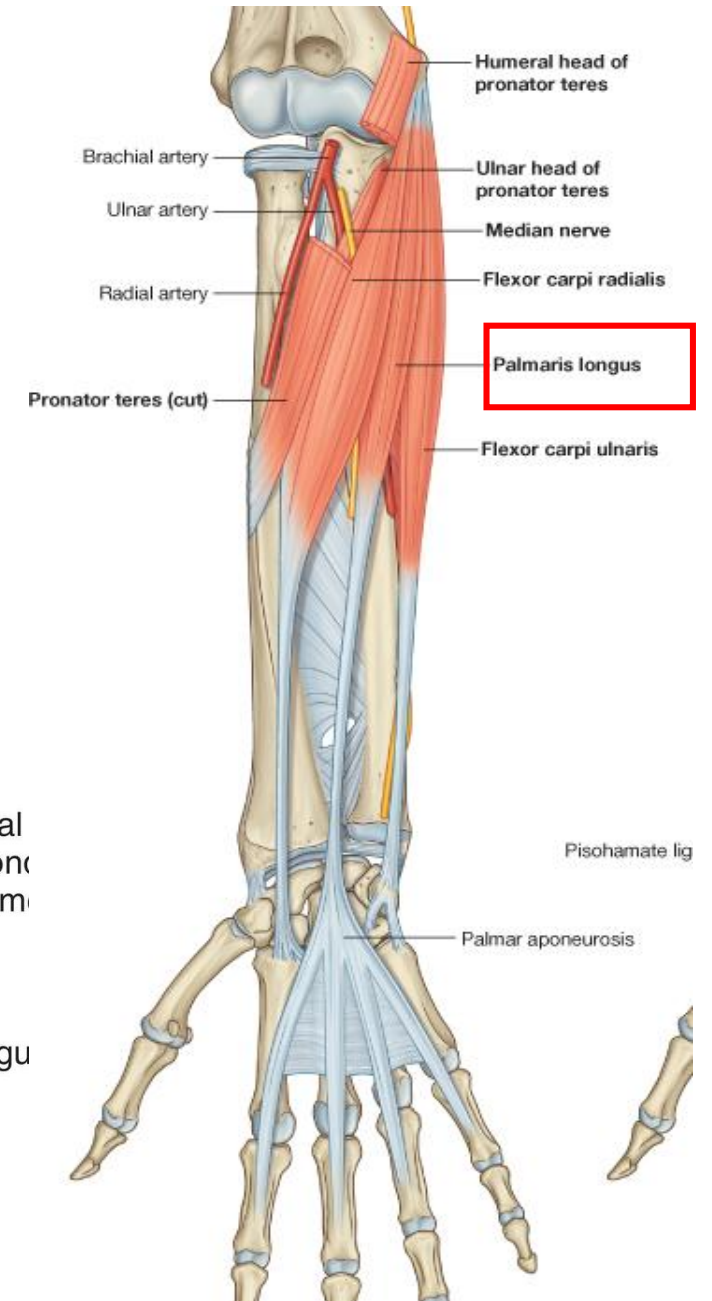
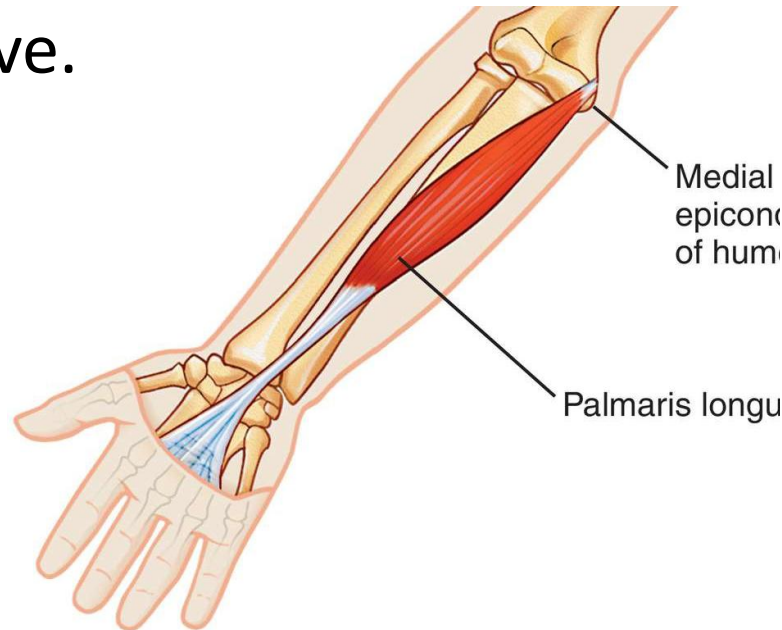
- **Origin:** Medial epicondyle of humerus
- **Insertion:** Base of second and third metacarpal bones
- **Action:** Flexion and abduction of hand at wrist
- **Nerve supply:** Median nerve.



Superficial Layer:

Palmaris Longus

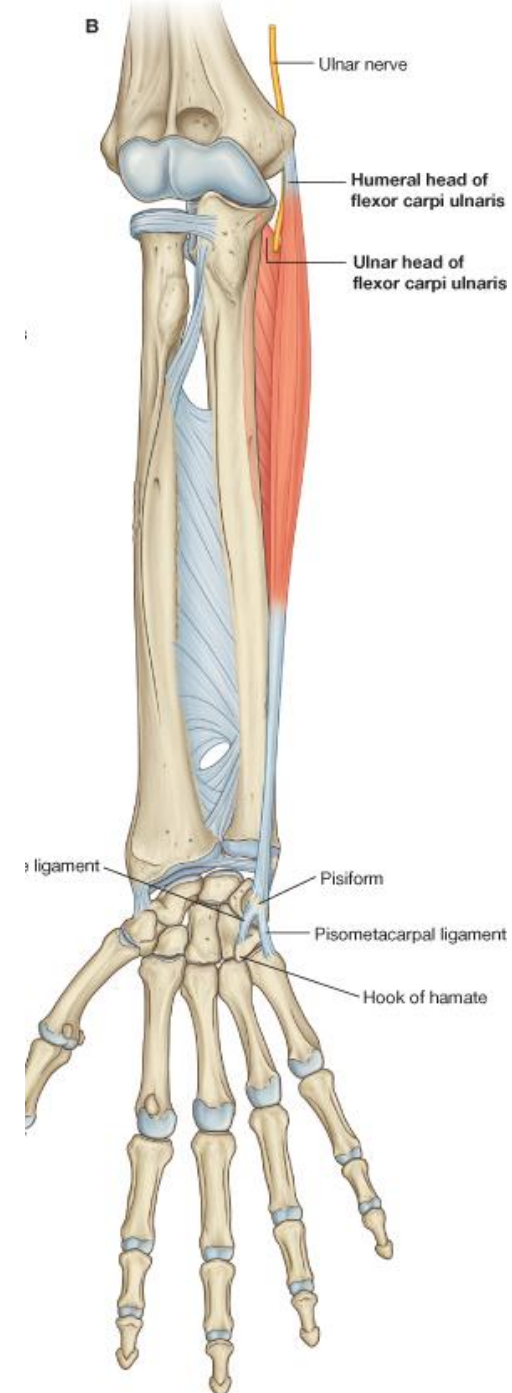
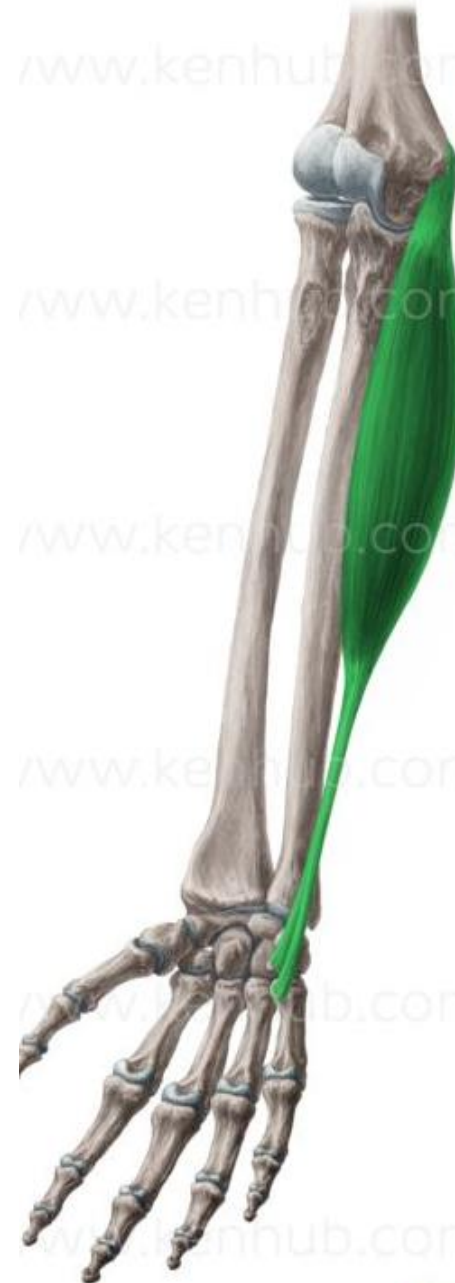- **Origin:** Medial epicondyle of humerus
- **Insertion:** Palmar aponeurosis of hand
- **Action:** Flexion of hand at wrist
- **Nerve supply:** Median nerve.



Superficial Layer:

Flexor Carpi Ulnaris

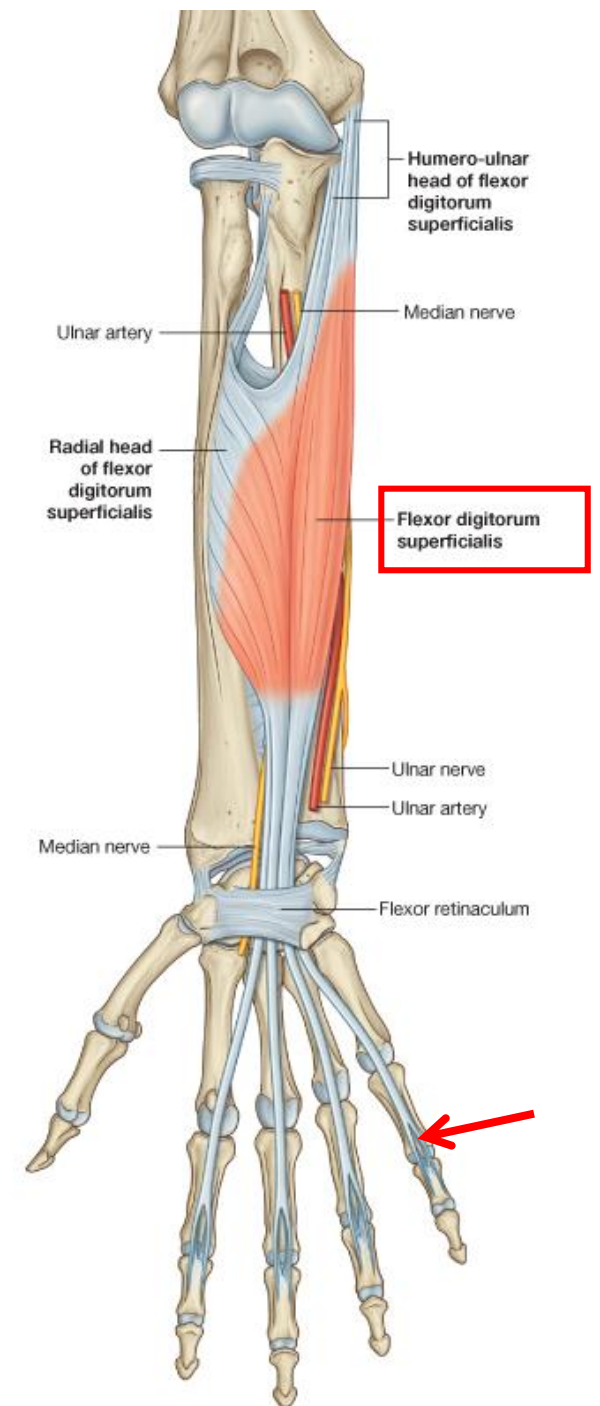
- **Origin:**
 - **Humeral head:** medial epicondyle
 - **Ulnar head:** olecranon process and posterior border of ulna
- **Insertion:** Pisiform bone, hook of the hamate, and base of 5th metacarpal bone
- **Action:** Flexion and adduction of hand at wrist.
- **Nerve supply:** Ulnar nerve.

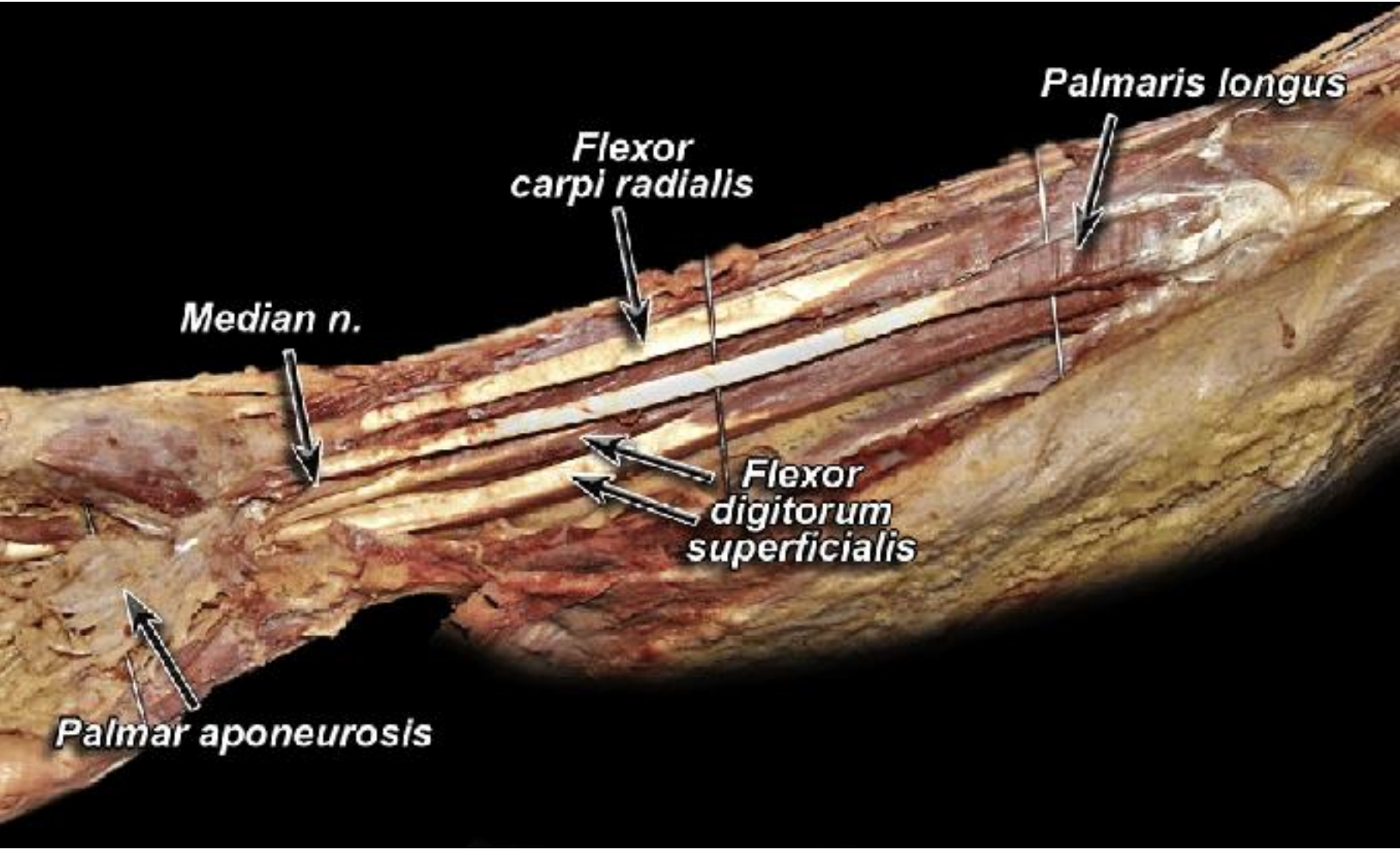


Superficial Layer:

Flexor Digitorum Superficialis

- **Origin:**
 - **Humero-ulnar head:** medial epicondyle of humerus and medial border of coronoid process.
 - **Radial head:** oblique line of radius.
- **Insertion:** Four tendons to the **palmar surfaces of the middle phalanges** of medial four fingers .
- **Action:** Flexes middle phalanx of fingers; and assist in flexing proximal phalanx and the wrist joint.
- **Nerve supply:** Median nerve.

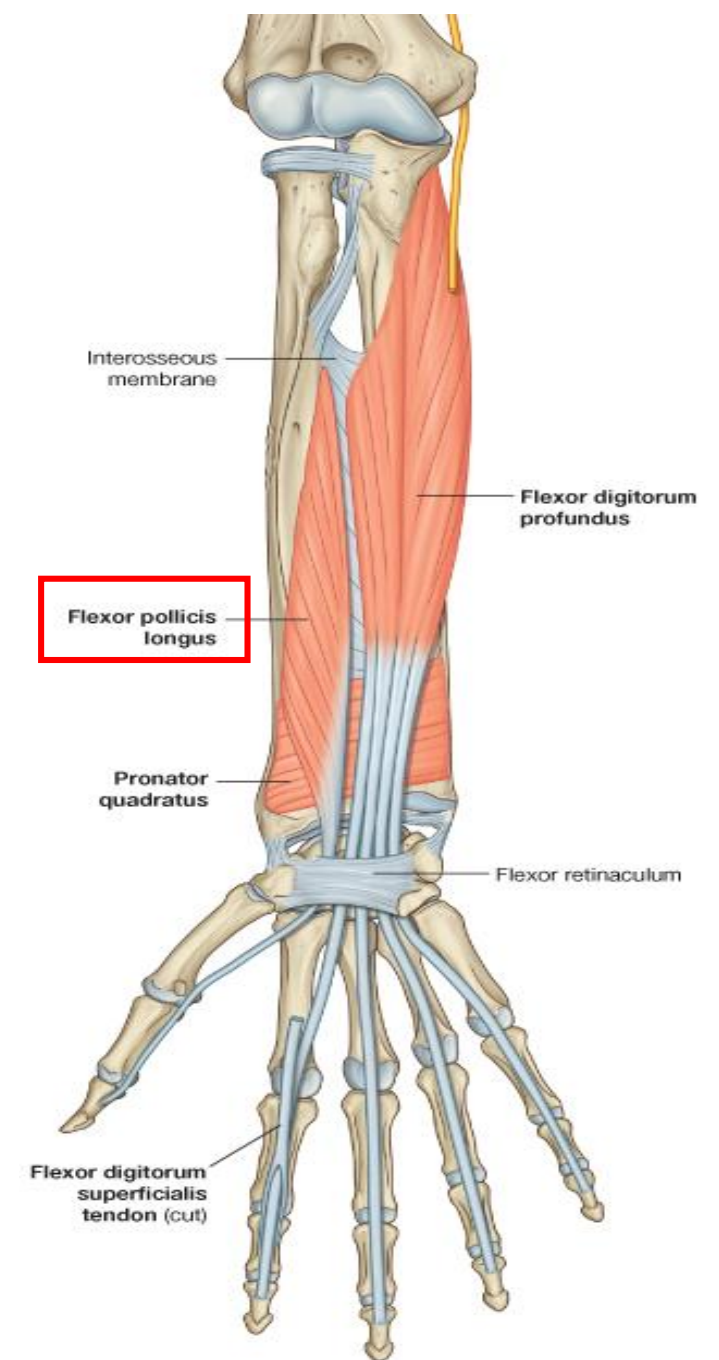




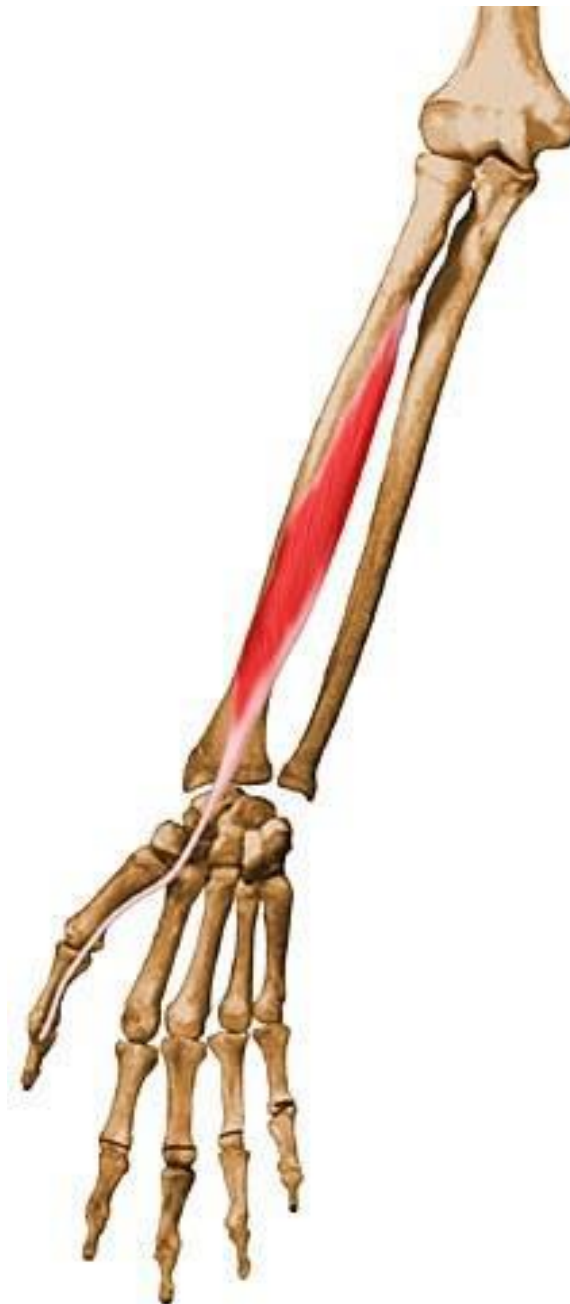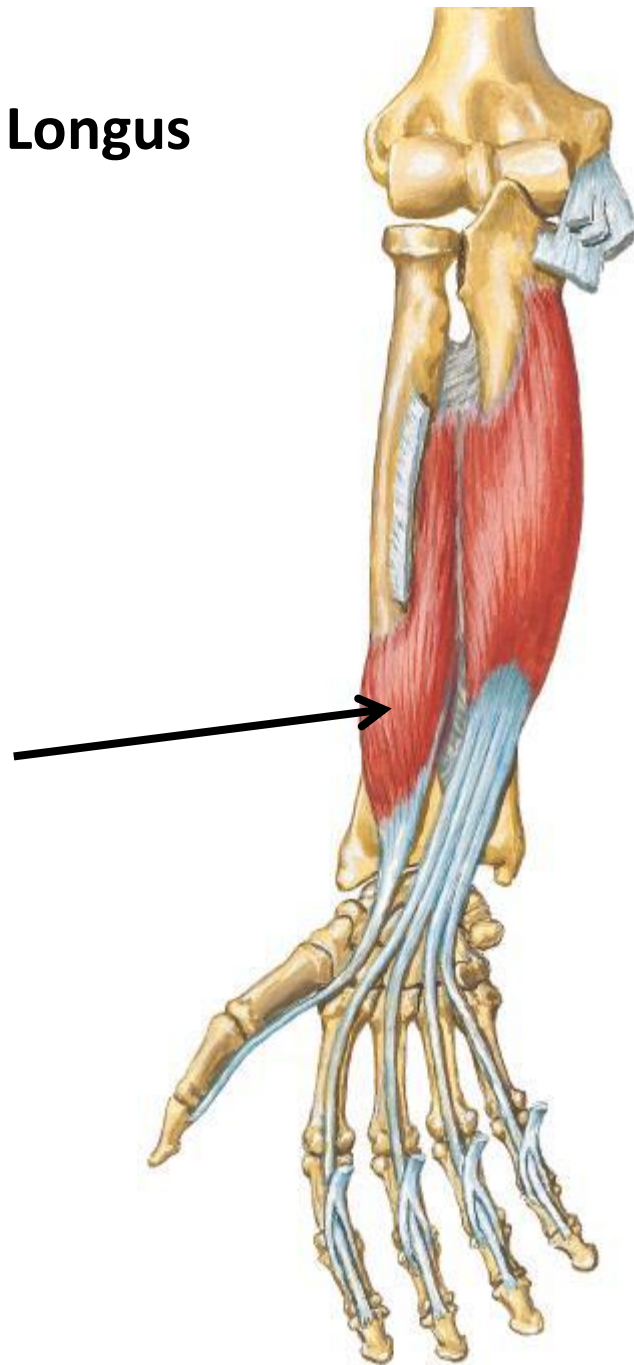
Deep Layer:

Flexor Pollicis Longus

- **Origin:** Anterior surface of shaft of radius
- **Insertion:** Distal phalanx of thumb
- **Action:** Flexes distal phalanx of thumb
- **Nerve supply:** Median nerve.



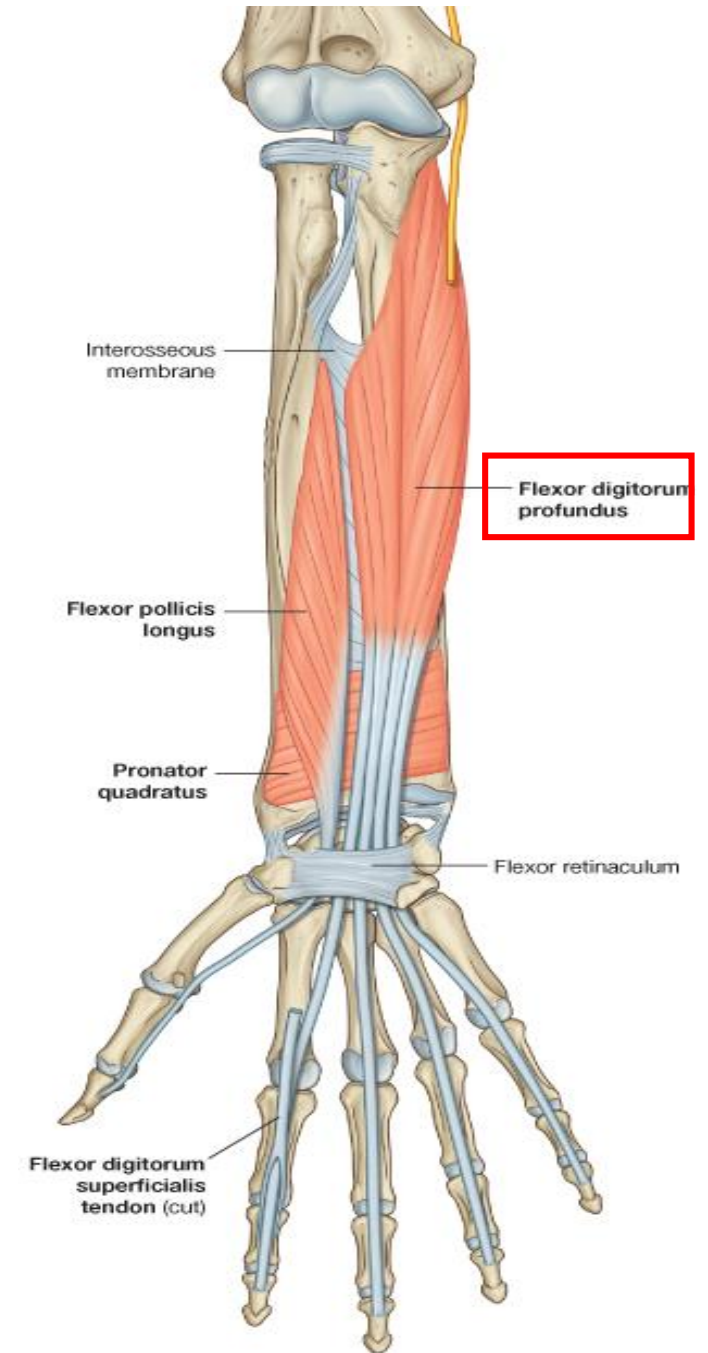
Flexor Pollicis Longus



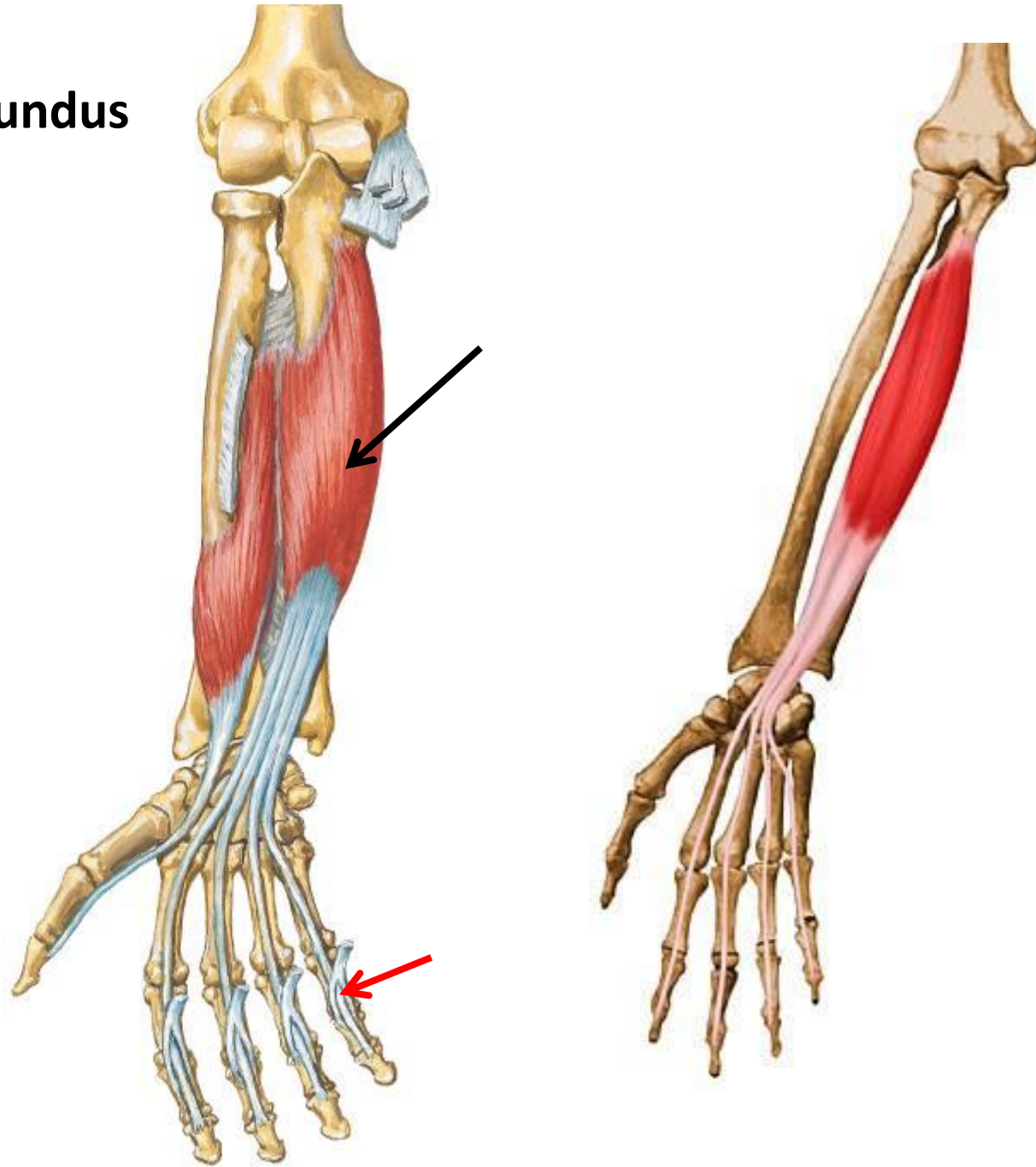
Deep Layer:

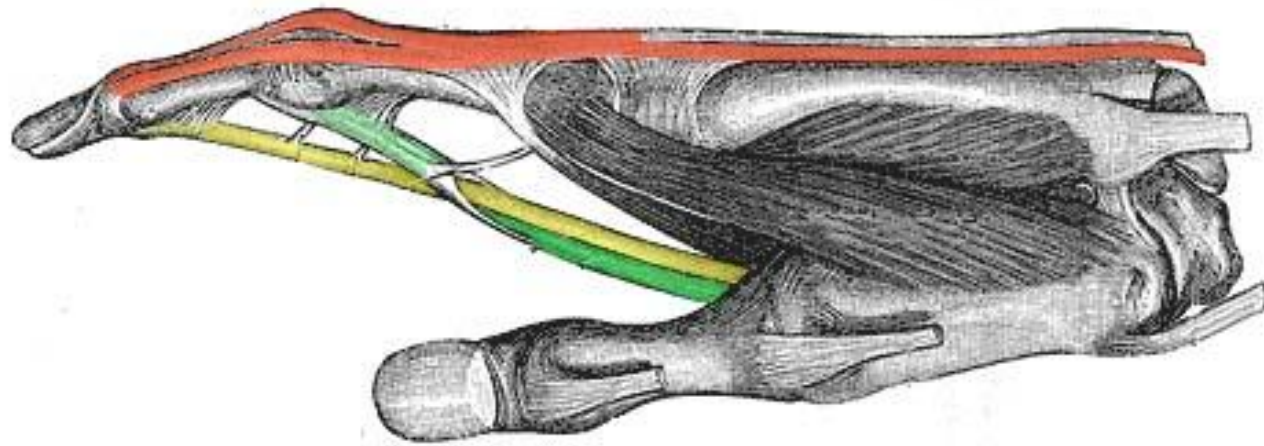
Flexor Digitorum Profundus




- **Origin:** Anteromedial surfaces of shaft of ulna and interosseous membrane.
- **Insertion:** Distal phalanges of medial four fingers.
- **Action:** Flexes distal phalanx of fingers; and assist in flexing middle and proximal phalanges and the wrist joint
- **Nerve supply:**
 - Lateral half by **median nerve**.
 - Medial half by **ulnar nerve**.



Flexor Digitorum Profundus



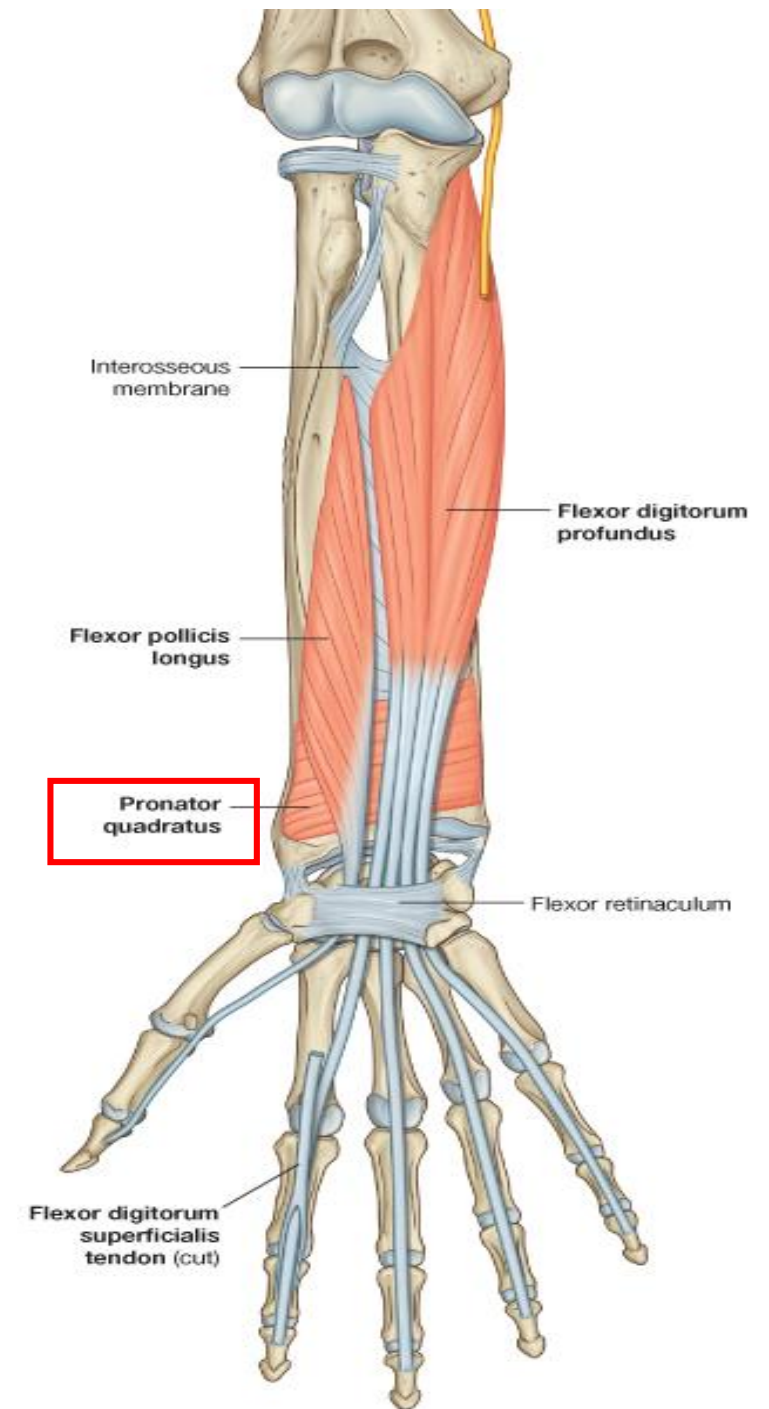


-  Extensor digitorum tendon and extensor hood
-  Flexor digitorum profundus tendon
-  Flexor digitorum superficialis tendon


Deep Layer:

Pronator Quadratus

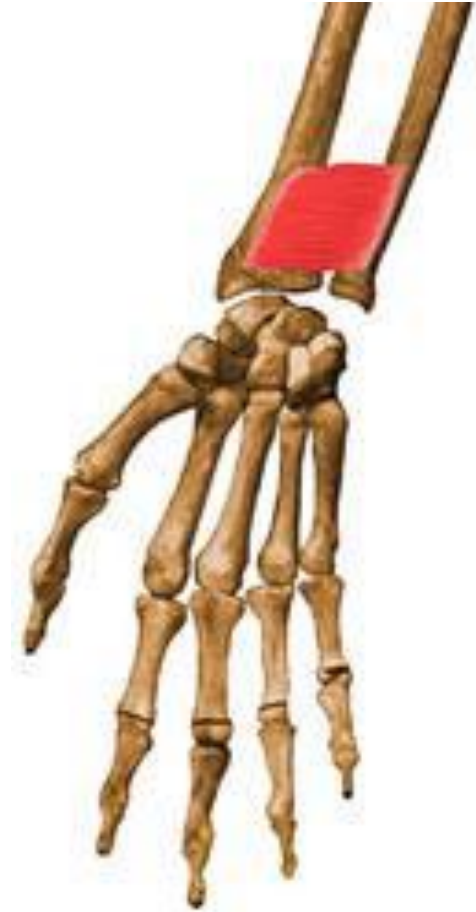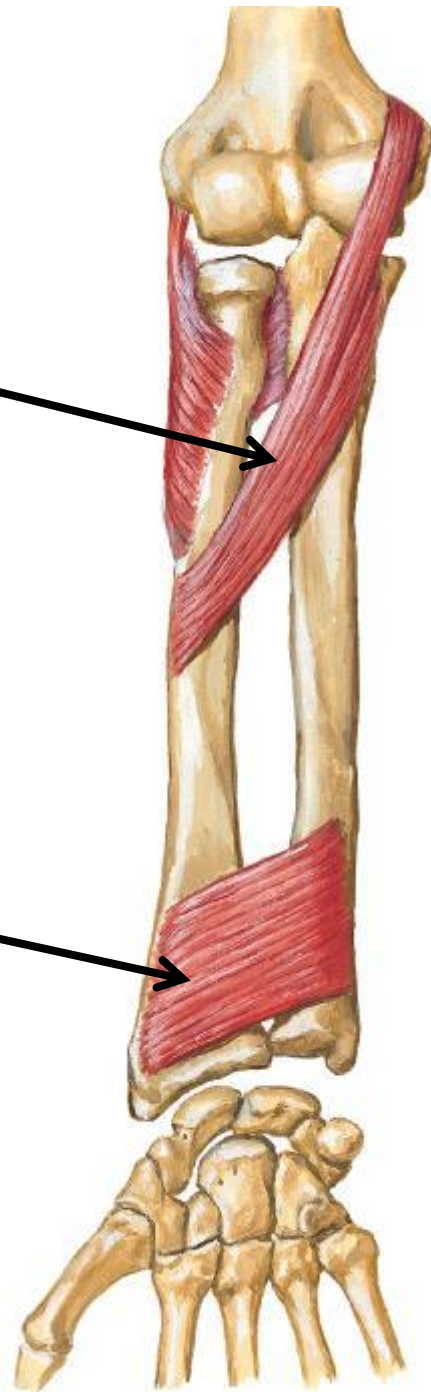- **Origin:** Anterior surface of shaft of ulna
- **Insertion:** Anterior surface of shaft of radius
- **Action:** Pronation of forearm
- **Nerve supply:** Median N.



Pronator Teres



Pronator Quadratus



Muscles of Posterior Compartment (Extensor compartment)

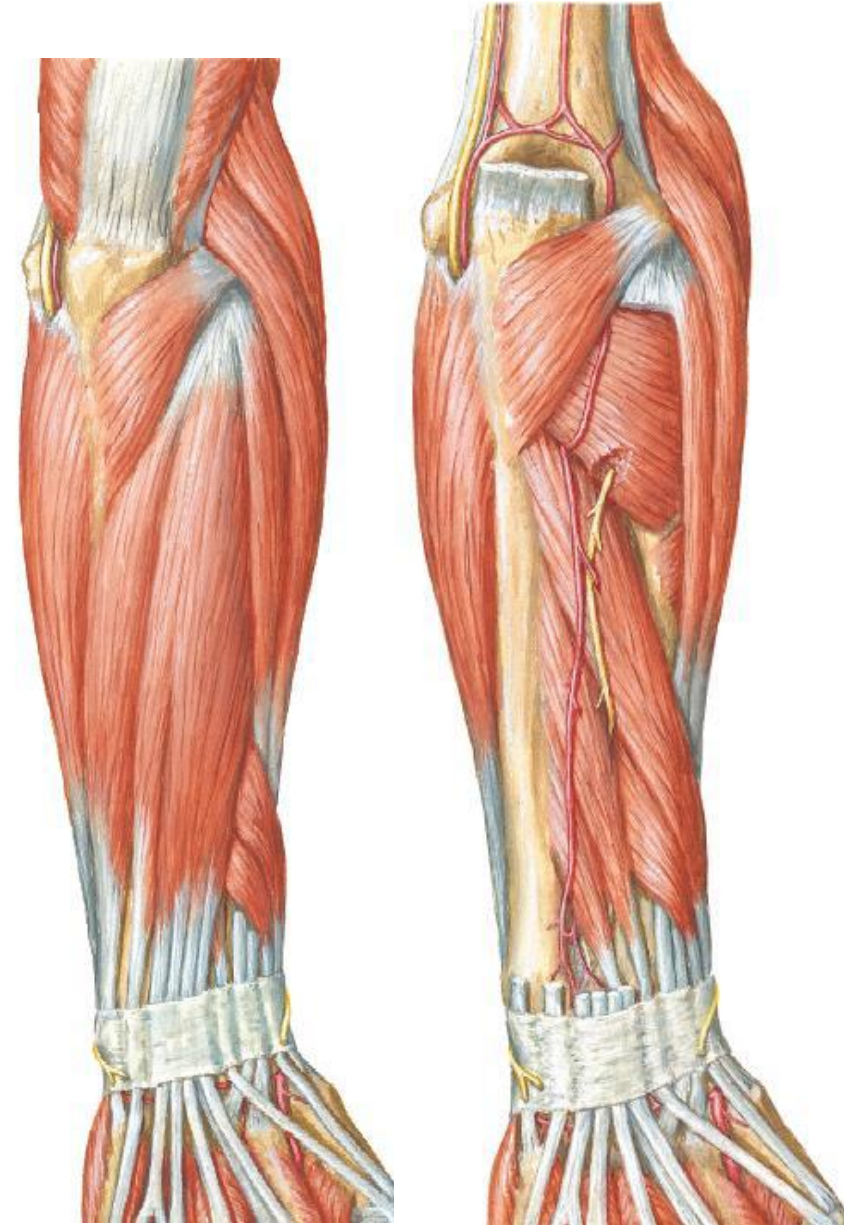
- General features for muscles of posterior compartment:
 - **Superficial** and **Deep** layers
 - **Extensors** of hand and fingers
 - Most extensors have common origin on **lateral epicondyle**
 - Contains a **supinator** muscle
 - They are innervated by the **Radial nerve**

Superficial layer:

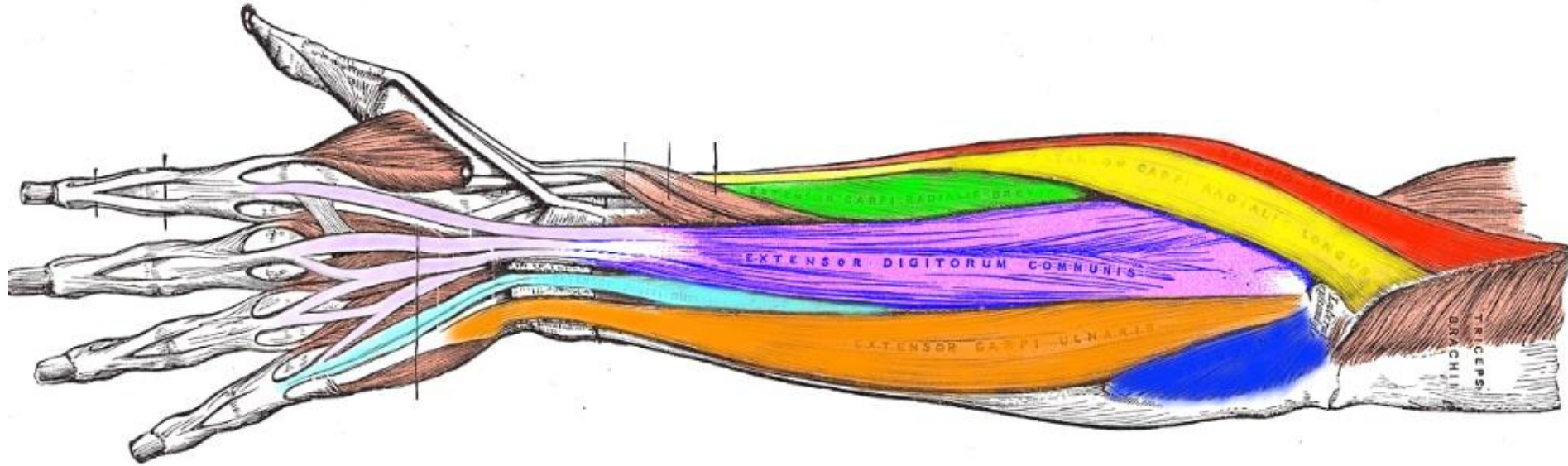
1. Brachioradialis
2. Extensor Carpi Radialis Longus
3. Extensor Carpi Radialis Brevis
4. Extensor Digitorum
5. Extensor Digiti Minimi
6. Extensor Carpi Ulnaris
7. Anconeus

Deep layer:

1. Supinator
2. Abductor Pollicis Longus
3. Extensor Pollicis Brevis
4. Extensor Pollicis longus
5. Extensor Indicis



Superficial Layer of the Posterior Compartment



● Brachioradialis

● Extensor carpi radialis brevis

● Extensor digiti minimi

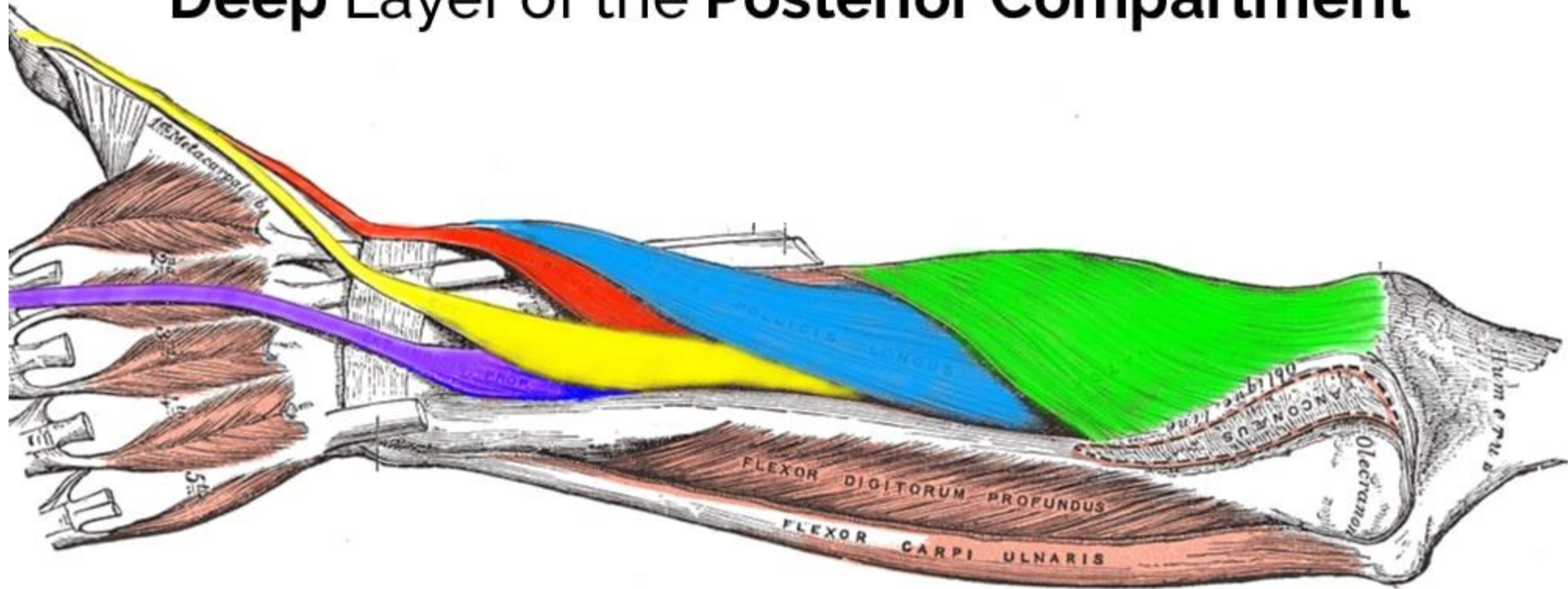
● Extensor carpi radialis longus

● Extensor digitorum communis

● Extensor carpi ulnaris

● Anconeus

Deep Layer of the Posterior Compartment



● Supinator

● Extensor pollicis brevis

● Extensor indicis

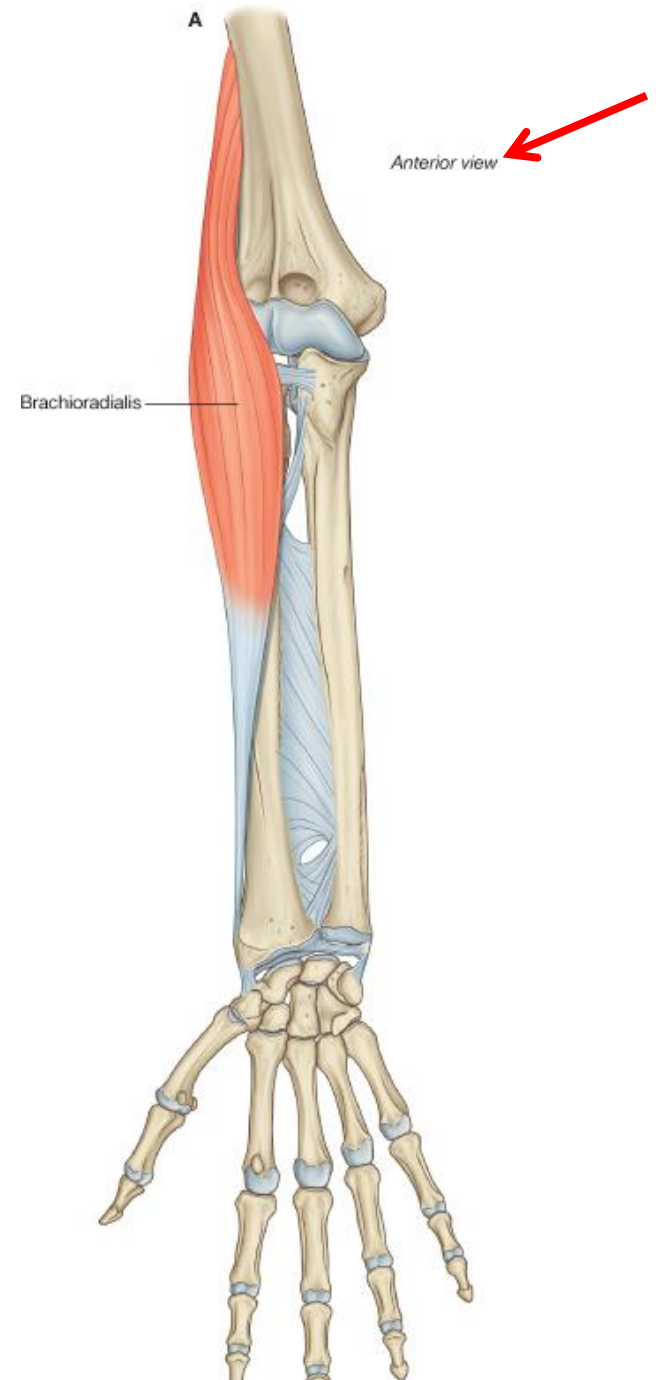
● Abductor pollicis longus

● Extensor pollicis longus

Superficial Layer:

Brachioradialis

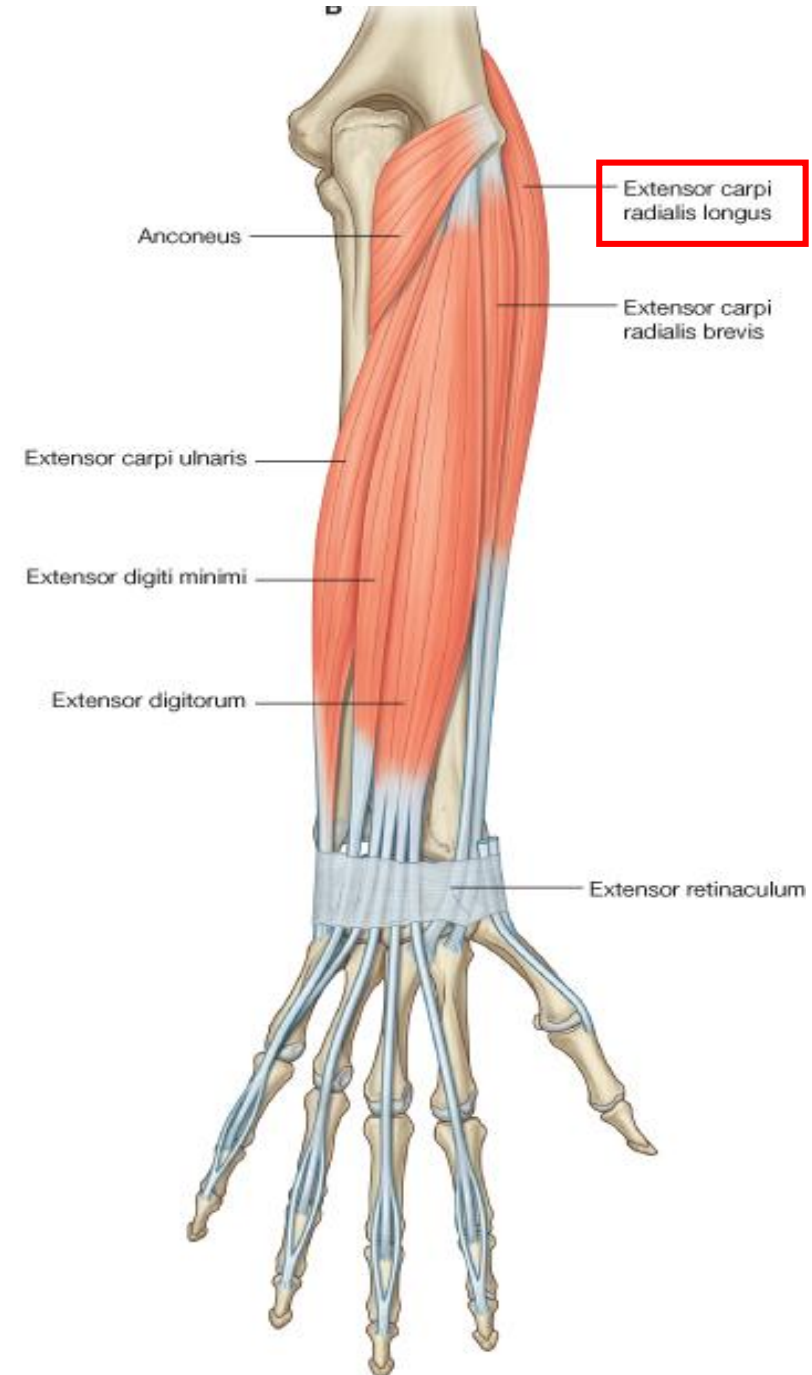
- **Origin:** Lateral supraepicondylar ridge of humerus
- **Insertion:** Base of styloid process of radius
- **Action:** Accessory flexor of elbow joint, rotate forearm to the midprone position
- **Nerve supply:** Radial nerve



Superficial Layer:

Extensor Carpi Radialis Longus

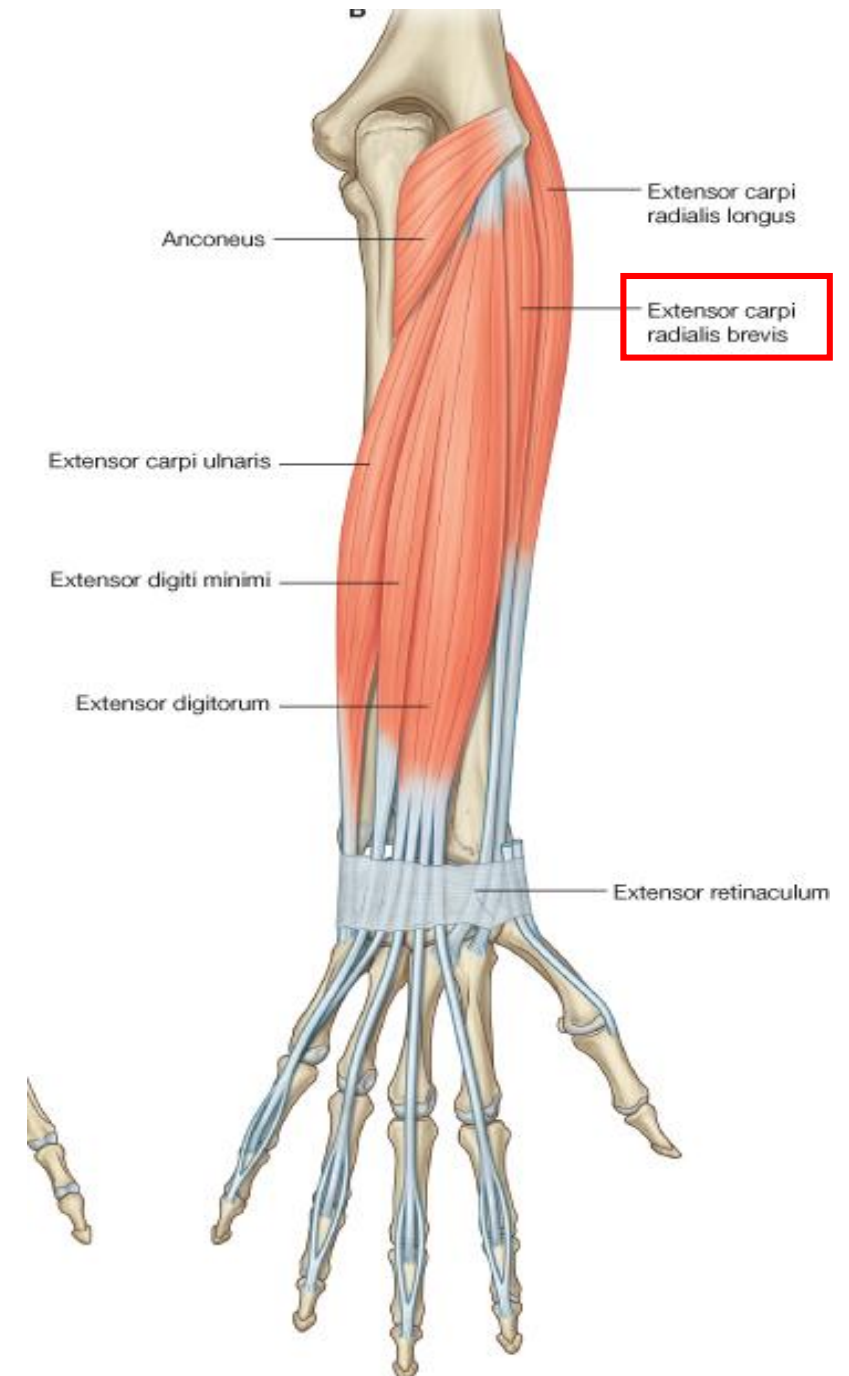
- **Origin:** Lateral supraepicondylar ridge of humerus
- **Insertion:** Posterior surface of base of 2nd metacarpal bone
- **Action:** Extends and abducts hand at wrist joint.
- **Nerve supply:** Radial nerve



Superficial Layer:

Extensor Carpi Radialis Brevis

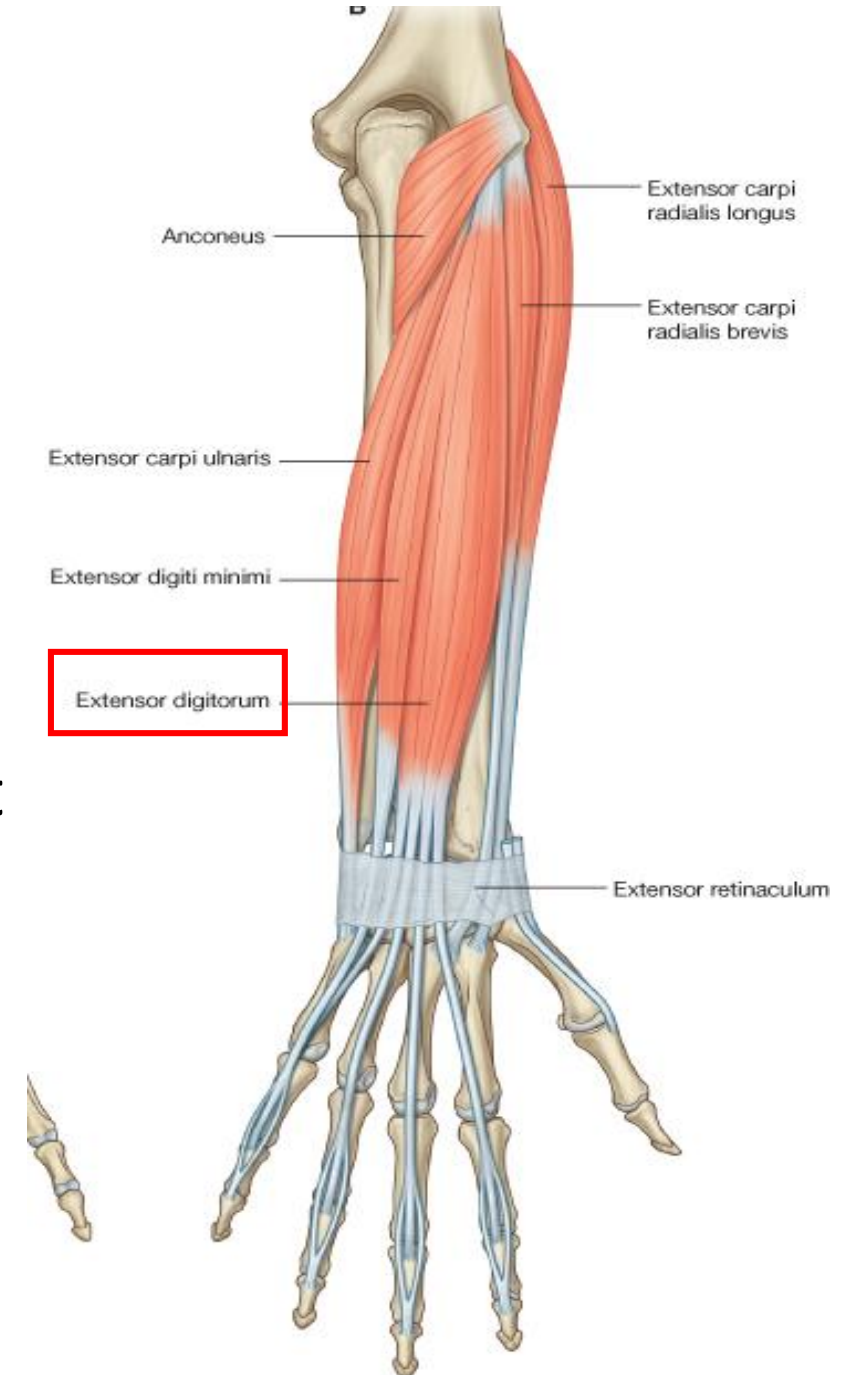
- **Origin:** Lateral epicondyle of humerus
- **Insertion:** Posterior surface of base of 3rd metacarpal bone
- **Action:** Extends and abducts hand at wrist joint.
- **Nerve supply:** Deep branch of radial nerve



Superficial Layer:

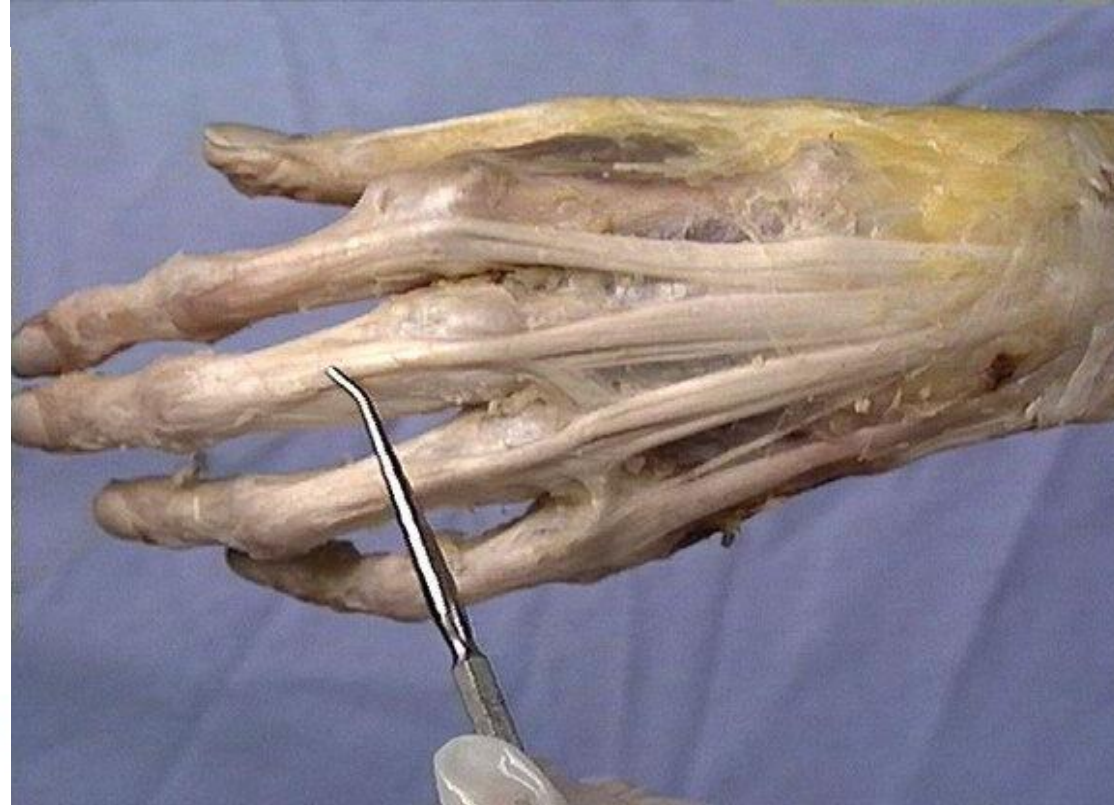Extensor Digitorum

- **Origin:** Lateral epicondyle of humerus
- **Insertion:** middle and distal phalanx of medial four fingers (Extensor expansion)
- **Action:** Extends fingers and hand at wrist joint
- **Nerve supply:** Deep branch of radial N.



On the posterior surface of each finger, the extensor tendon widens to form the **extensor expansion**. Near the proximal interphalangeal joint, the extensor expansion then splits into three parts: **central part** inserted into the base of middle phalanx, and **two lateral parts** which converge to be inserted into the base of distal phalanx.

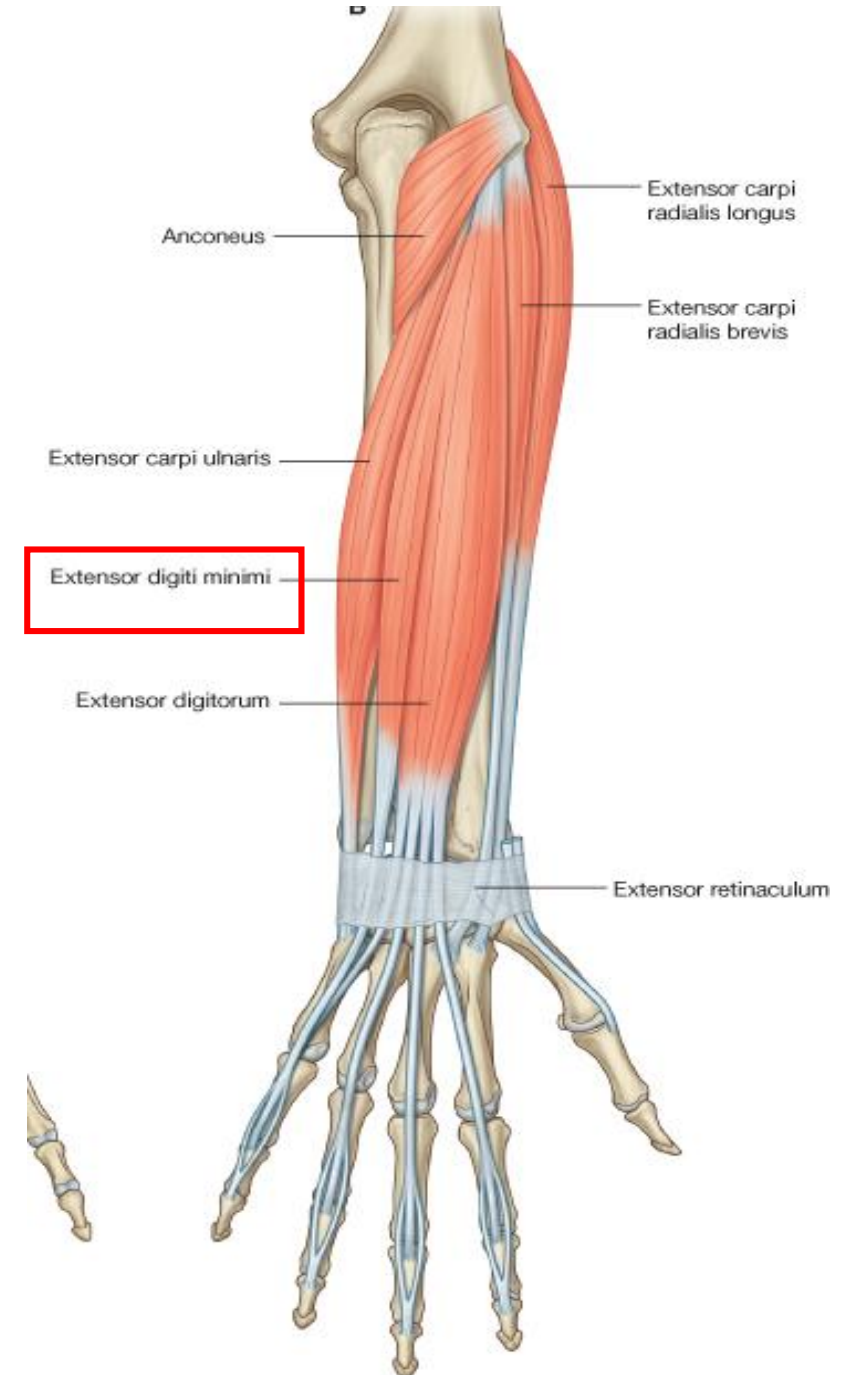
Extensor expansion



Superficial Layer:

Extensor Digiti Minimi

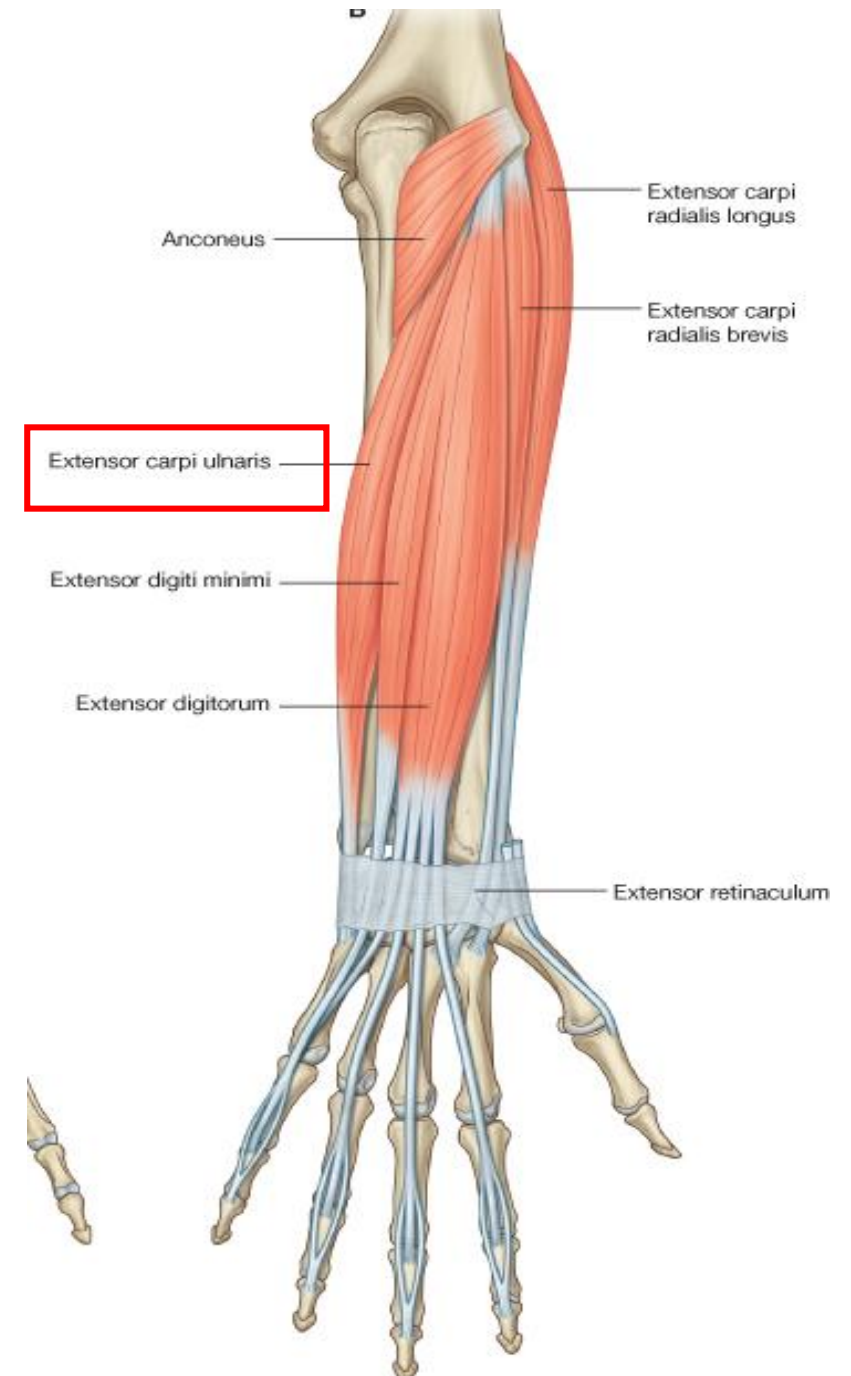
- **Origin:** Lateral epicondyle of humerus
- **Insertion:** Extensor expansion of little finger
- **Action:** Extends the little finger
- **Nerve supply:** Deep branch of radial N.



Superficial Layer:

Extensor Carpi Ulnaris

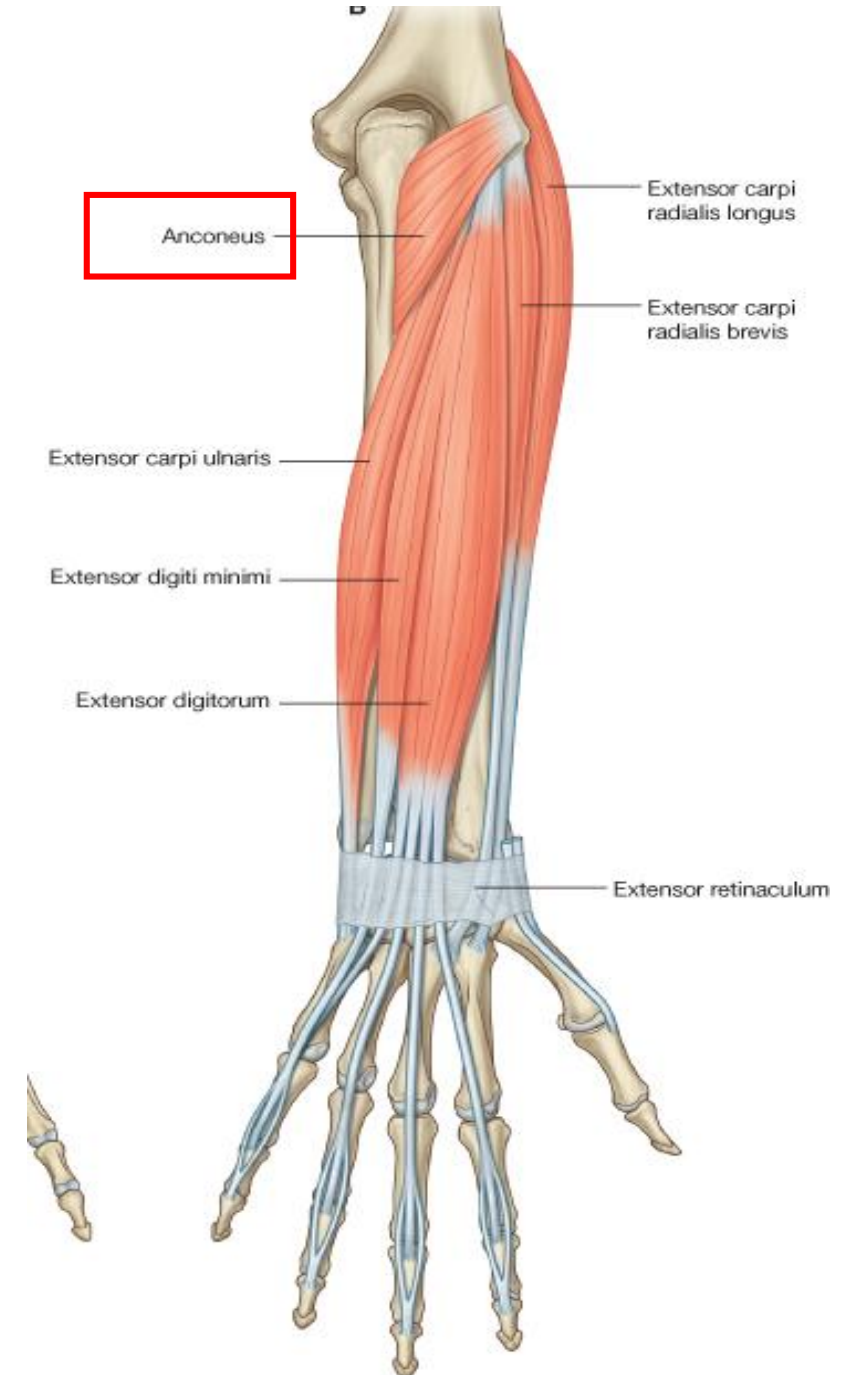
- **Origin:** Lateral epicondyle of humerus
- **Insertion:** Base of 5th metacarpal bone
- **Action:** Extends and adducts the hand at wrist joint
- **Nerve supply:** Deep branch of radial N.

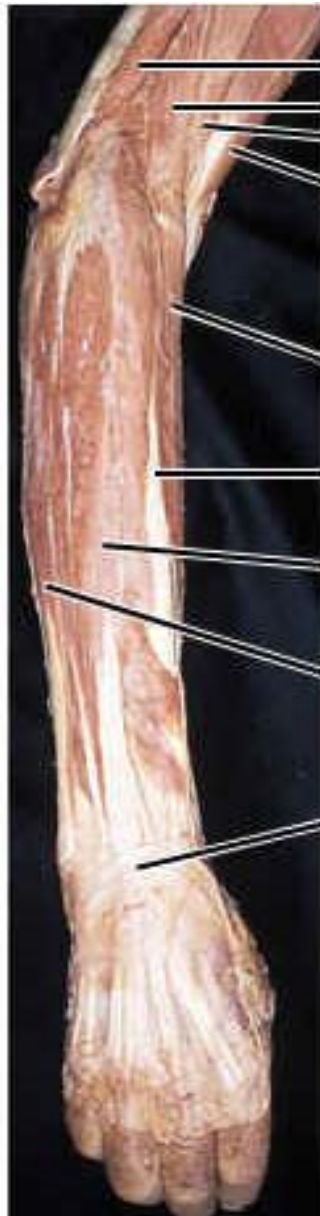

Superficial Layer:

Anconeus

- **Origin:** Lateral epicondyle of humerus
- **Insertion:** Lateral surface of olecranon surface of ulna
- **Action:** Extends elbow joint
- **Nerve supply:** Radial N.





Triceps brachii
Brachioradialis
Brachialis
Biceps brachii

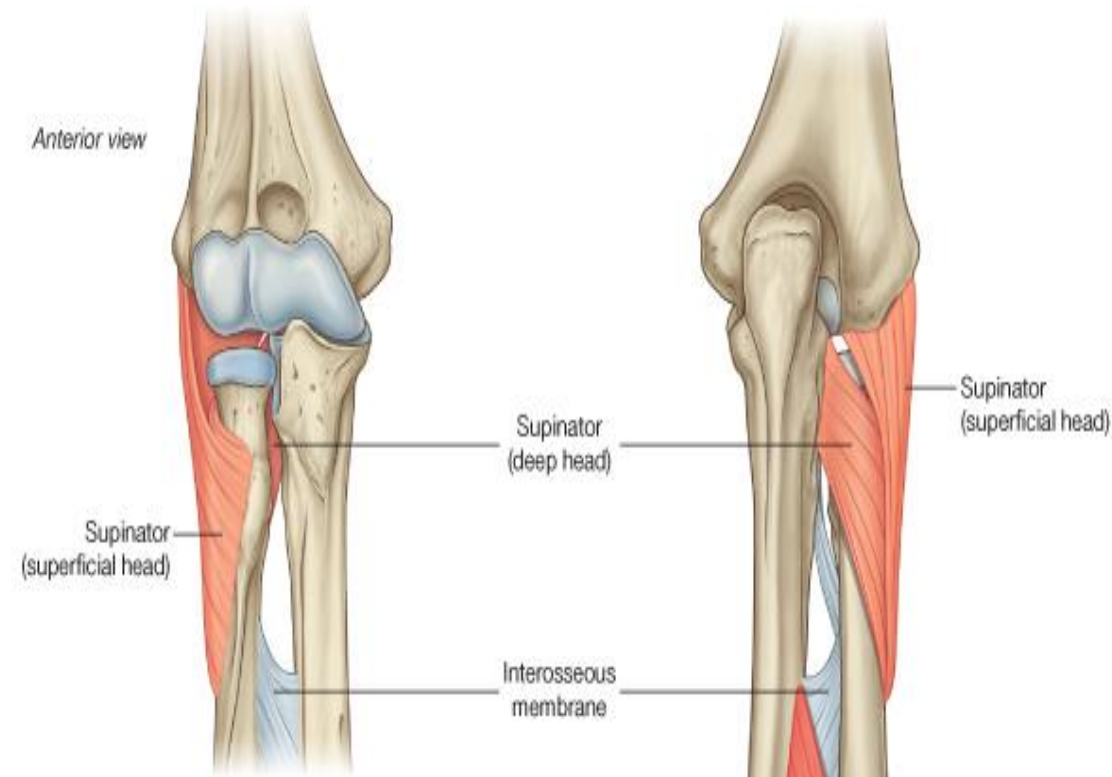
Extensor carpi radialis longus
Extensor carpi radialis brevis
Extensor digitorum
Extensor carpi ulnaris
Extensor retinaculum

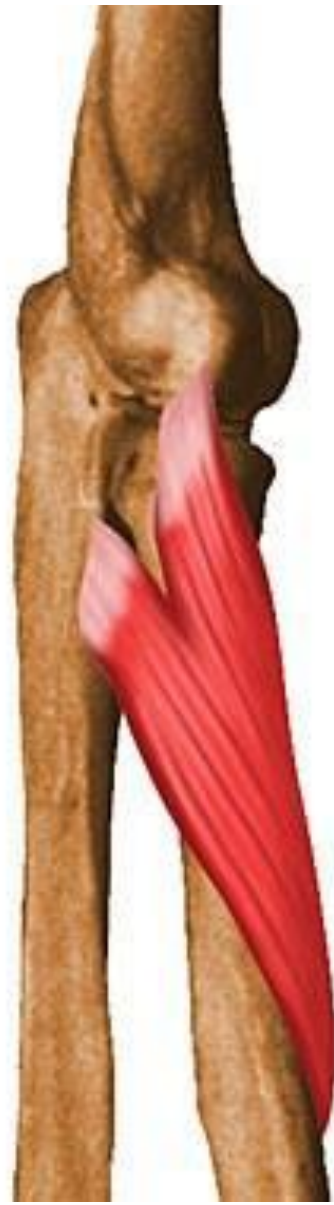**Right Forearm and
Hand — Posterior
View**

Deep Layer:

Supinator

- **Origin:**
 - **Superficial part:** Lateral epicondyle of humerus
 - **Deep part:** supinator crest of the ulna
- **Insertion:** Neck and shaft of radius
- **Action:** Supination of forearm
- **Nerve supply:** Deep branch of radial N.

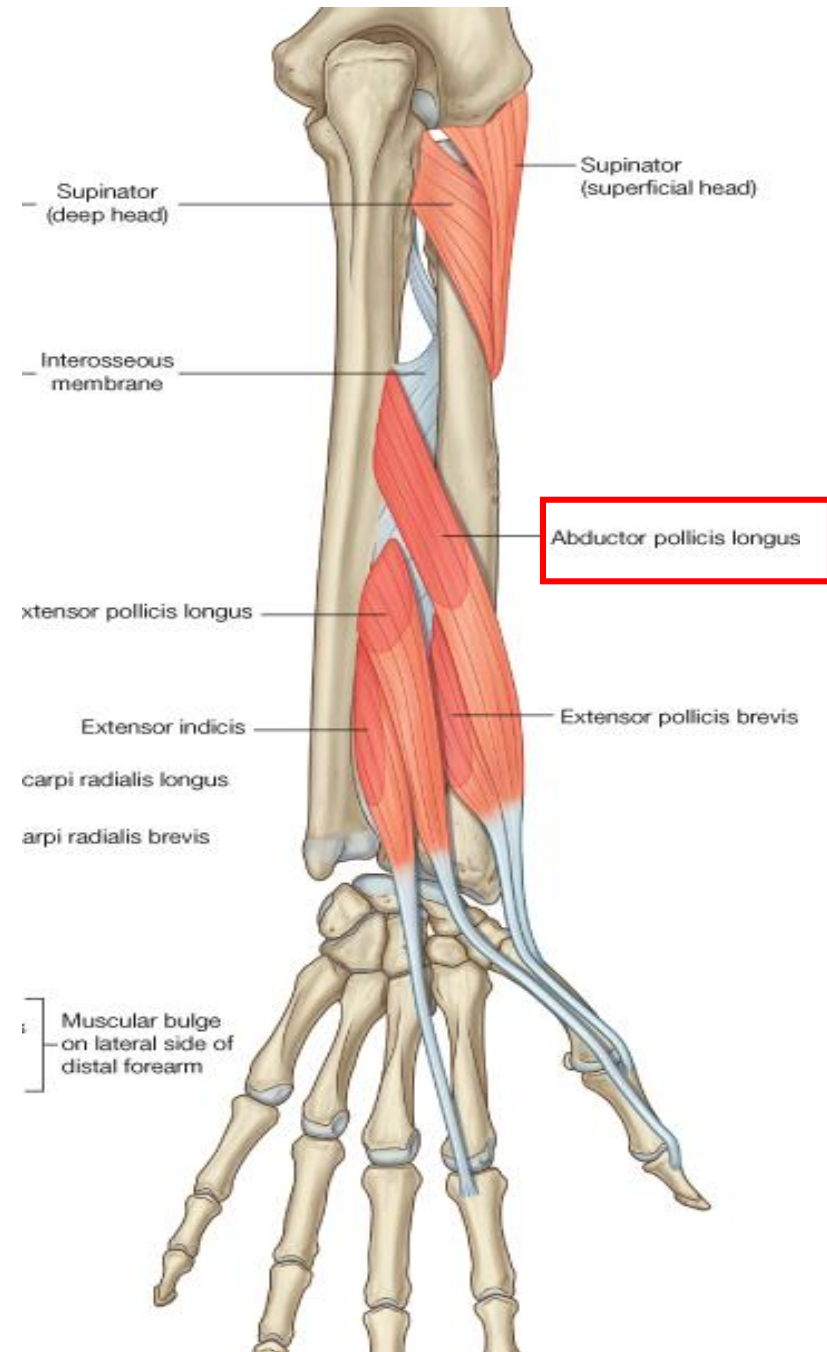




Deep Layer:

Abductor Pollicis Longus

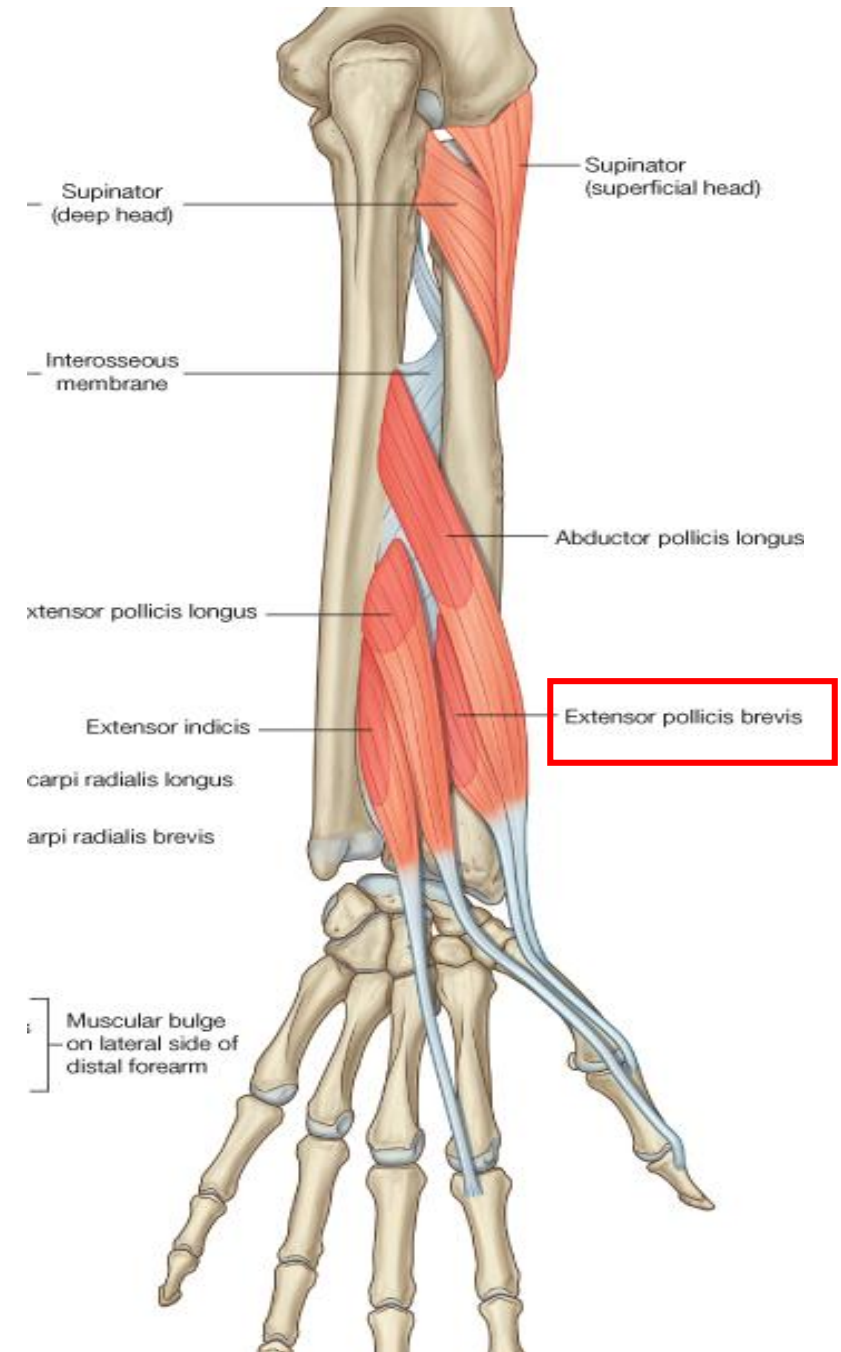
- **Origin:** Posterior surfaces of ulna and radius
- **Insertion:** base of 1st metacarpal bone
- **Action:** Abducts and extends thumb
- **Nerve supply:** Deep branch of radial N.



Deep Layer:

Extensor Pollicis Brevis

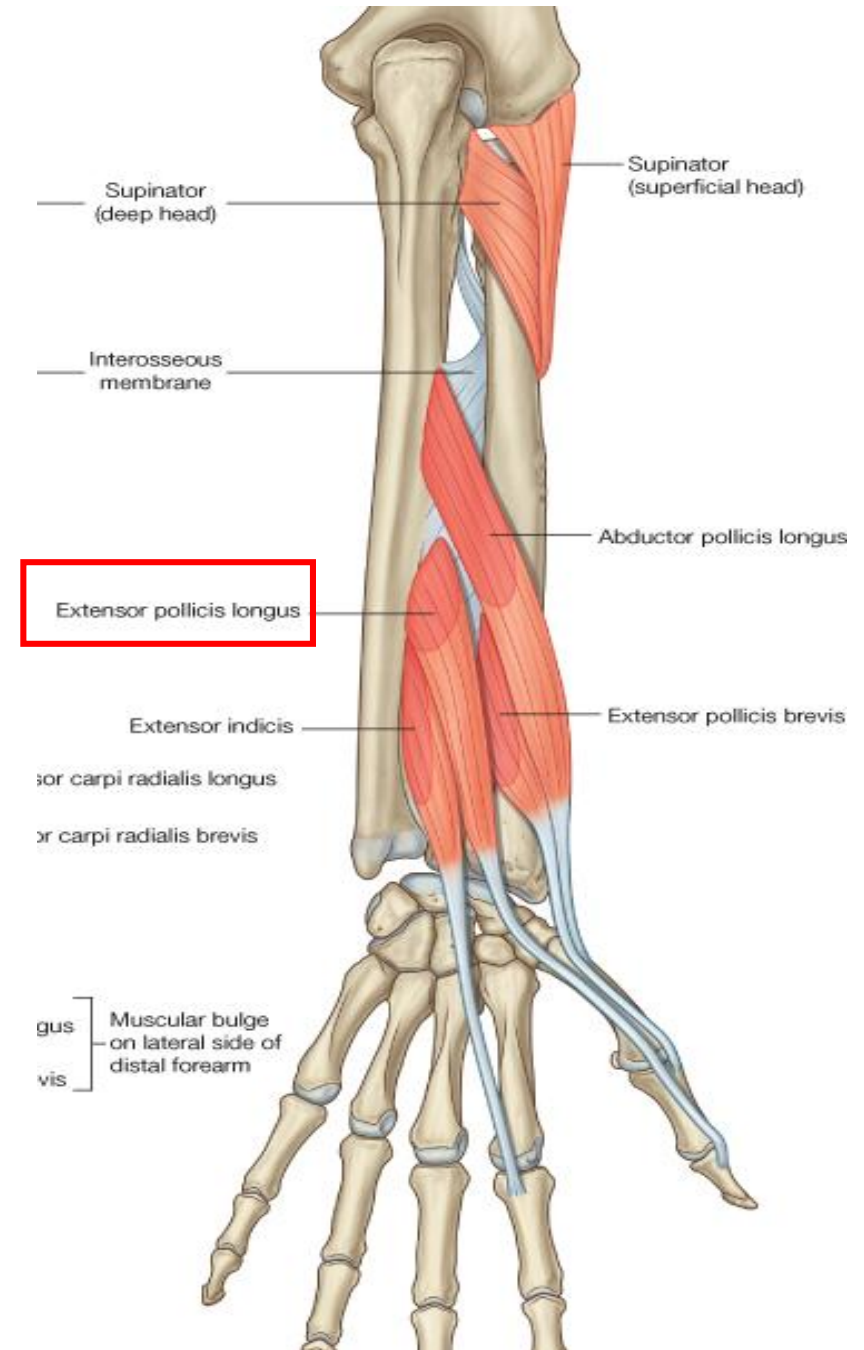
- **Origin:** Posterior surfaces of shaft of radius
- **Insertion:** Base of proximal phalanx of thumb
- **Action:** Extends metacarpophalangeal joint of the thumb
- **Nerve supply:** Deep branch of radial N.



Deep Layer:

Extensor Pollicis Longus

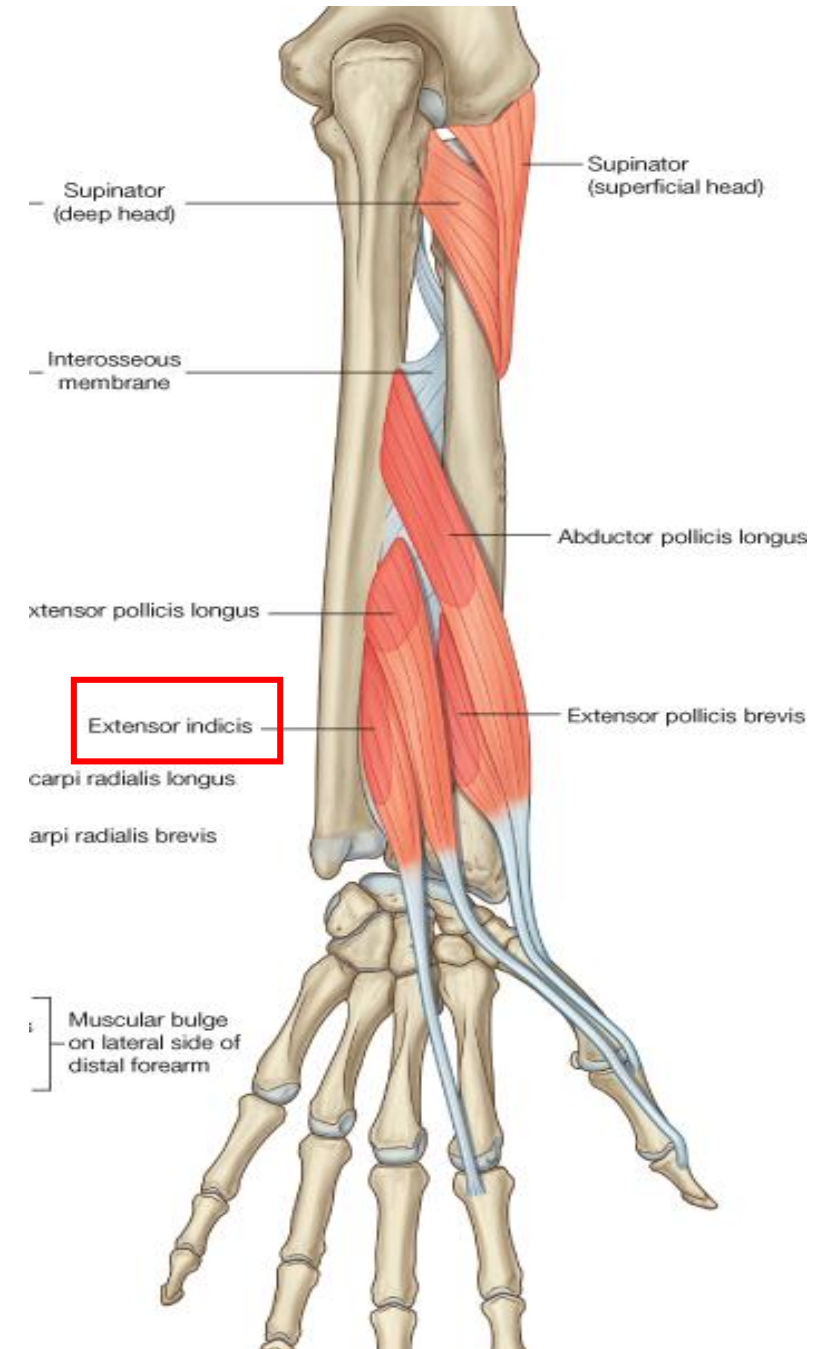
- **Origin:** Posterior surfaces of shaft of ulna
- **Insertion:** Base of distal phalanx of thumb
- **Action:** Extends distal phalanx of the thumb
- **Nerve supply:** Deep branch of radial N.



Deep Layer:

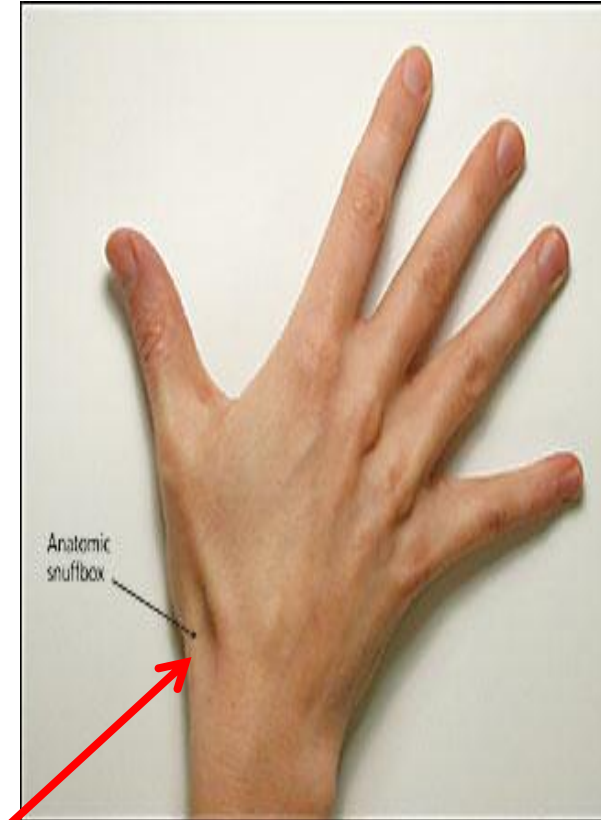
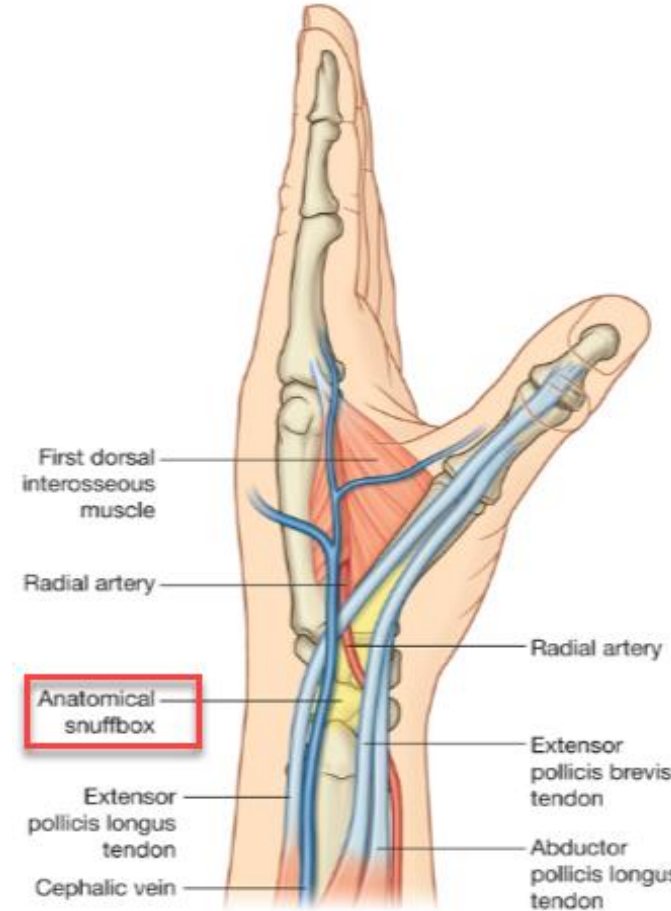Extensor Indicis

- **Origin:** Posterior surfaces of shaft of ulna
- **Insertion:** Extensor expansion of index finger
- **Action:** Extends metacarpophalangeal joint of index
- **Nerve supply:** Deep branch of radial N.



Anatomical Snuffbox

- The “anatomical snuffbox” is a term given to the **triangular depression** formed on the **posterolateral side** by the extensor tendons passing into the thumb.
- **Boundaries:**
 - Laterally (anteriorly): Tendons of APL & EPB.
 - Medially (posteriorly): Tendon of EPL.
- **Importance ??**

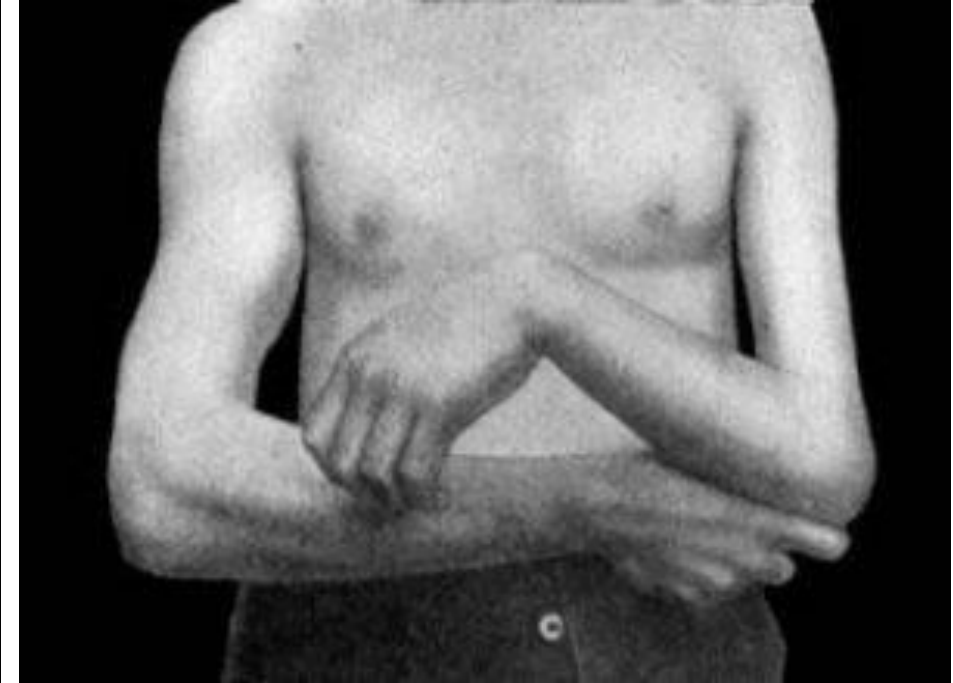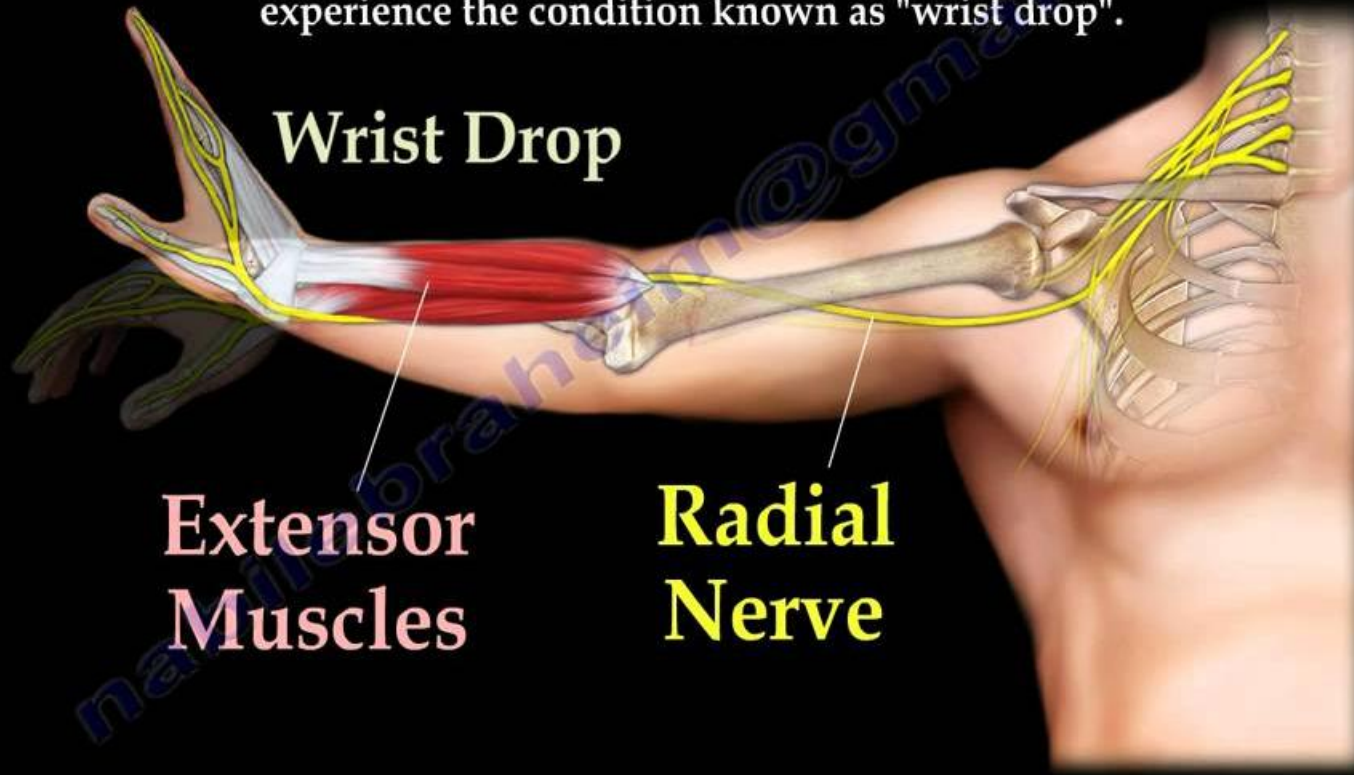


- Can be identified when the thumb is abducted and extended

Radial Nerve Palsy

The radial nerve supplies the extensor muscles allowing for extension of the wrist and fingers in addition to supplying the triceps that extends the elbow.

If the muscles are not working properly, the patient will experience the condition known as "wrist drop".



Radial Nerve Palsy

- There are two common characteristic sites of damage:
 1. **Axilla** – injured via humeral dislocations or fractures of the proximal humerus.
 2. **Radial groove of the humerus** – injured via a humeral shaft fracture.

Thank you

Ayman.alzubi@yu.edu.jo