



Musculoskeletal Systems

-Mid Exam-

Coordinator: Dr. Ayman Alzoubi

Collected by: GLORIANS TEAM

Batch: Glory - 2017



Anatomy - Histology - Embryology
Dr. Ramada - Dr. Ayman - Dr. Jamal

- 1) which of these foramina not associated with sphenoid bone?
- magnum ✓
 - spinosum
 - ovale
 - rotendum
 - lacerum
- 2) The foramen that located between crista galli of frontal and ethmoid bone?
- ceacum ✓
 - spinosum
 - rotendum
 - lacerum
- 3) cells of back الـneural crest بتعطي الجواب العبارة الغلط- في سؤال انوشو العبارة الغلط- الجواب
- 4) One of these muscles doesn't cause lateral rotation:
- Pectiues ✓
 - Gluteus Maximus
 - Obturator internus
 - Superior Gemellus
- 5) Which of the muscles isn't medial rotator:
- Gracialis
 - Biceps femoris ✓
 - Semitendinosus
 - Semimembranosus
- 6) Food drop is caused by damage to which nerve:
- deep peroneal ✓
- 7) One of Skin layers has flattened cells whose cytoplasm filled with basophilic keratohyalin granules is:
- Stratum Granulosum ✓
- 8) a patient admitted hospital with a fracture in his humerus and can't abduct his arm above 15°..and no L. rotation ,, where the fracture more likely happen :
- anatomical neck
 - surgical neck ✓
- 9) Wrist drop is caused by damage to:
- radial nerve ✓
- 10) The angle between neck of femur and shaft:
- 125° ✓
- 11) Not paired triangle:
- submental ✓

- submandibular
- muscular
- carotid
- posterior

12) A woman (who works in cleaning houses) complain from severe pain in her knee, especially when kneeling in her knee on the ground, what the affected structure:

- Prepatellar bursa ✓
- Supra patellar bursa
- Lateral menisci

13) Rotator cuff are, supraspinatus, infraspinatus, subscapularis and:

- Teres minor ✓
- Teres major

14) All of these muscles are infrahyoid except:

- Stylohyoid ✓

15) Which muscle is not part of suprahyoid Ms.:

- sternohyoid M. ✓
- mylohyoid
- digastric m

16) When occipitofrontalis contracts, the first three layers of the scalp move forward or backward, the _____ of the fourth layer of the scalp allowing the aponeurosis to move on the pericranium.

- loose areolar/ connective tissue ✓
- Dense connective tissue
- Aponeurotic tissue
- skin

17) A child with developed stage of bladder ca, he is unable to make adduction, the nerve that is mostly compressed by this tumor is:

- Femoral N
- Sciatic N
- Tibial N
- Obturator N ✓

18) A football player was injured and get hospital, a physician notice that there is a significant anterior movement of tibia along femur, What the structure mostly affected.?

- Anterior cruciate ligament .. ✓

19) One of the following is true about pectoral fascia

- separates the breast from pectoralis major ✓
- forms the axillary ligament
- it splits to surround pectoralis minor
- extent b/w pectoralis minor and the clavicle

pectoral* باقي الخيارات كلهم للclavipectoral مش ال

20) Infraglenoid tubercle of scapula is the origin for

- long head of triceps ✓

21) The anterior aspect of the scapula is occupied by

- subscapular fossa ✓

22) All of the following are muscles of the 4th layer of foot except

- flexor hallucis brevis ✓

23) Limbs rotation occurs during:

- 5th week
- 6th week
- 4th week
- 7th week ✓

24) Pt. Complain from problem in muscles of mastication, the defect in which pharyngeal pouch?

- 1st one ✓

25) All of the following cross through GS foremen except:

- Piriformis
- Inferior gluteal nerve
- Peduncul nerve
- Sciatic n
- Tendon of obturator internus ✓

26) سؤال ال capsule جوابه بترتبط بال femoral neck posteriorly مش بال intertrochanteric Crest

27) process of forming osteoblast from chondrocyte: ما كانت هيك صيغته السؤال

- intramembranous ossification ✓

28) One of the following muscles attaches to lesser trochanter:

- iliopsoas ✓
- Gluteus maximus
- Pectineus

29) كان في سؤال انه شو الطبقات الي راح تخترقها ابرة اذا راح ندخلها من الرقبة من الامام باتجاه ال parathyroid gland

Skin, investing layer, pretracheal fascia, thyroid, parathyroid ✓

30) question about shoulder joint, which one is incorrect?

- The articular surfaces are covered by hyaline articular cartilage
- the glenoid cavity is deepened by the presence of a hyaline rim called the glenoid labrum. ✓
- capsule attached medially to the margin of the glenoid cavity outside the labrum
- The capsule is thin and lax, allowing a wide range of movement.
- capsule attached laterally to the anatomic neck of the humerus.

31) When Patient asked to stand on his right leg his left pelvis dropped which nerve is damaged?

- Right superior gluteal nerve ✓

32) Sesamoid bone of the upper row of carpal bones:

- scaphoid
- triquetral
- pisiform ✓

33) Which of the following statements is true about 3rd and 4th lumbricals

- it is innervated by median nerve

- it is innervated by radial nerve
- their action is flexion on interphalangeal joints and extension on metacarpophalangeal joints
- it is originate from tendon of flexor digitorum longus ✓
- none of the above

Physiology

Dr. Hakam

34) Rigor mortis cause:

- Depletion of ATP ✓

35) All the following is true, EXCEPT :

- lack of ACh on the synaptic cleft results in sustained contraction
- all the muscle types follow the sliding filament mechanism
- repetitive innervation may elevate body T that may cause brain damage
- DHP are Ca voltage gated channels on the sarcolemmal membrane
- None of the above ✓

ال DHP صح فولتج وموجودين ع ال T tubules والتي توبولس هي invagination of the sarcolemma

36) One of the following is INCORRECT:

- repetitive innervation can't increase the number of activated muscle fibers nor the magnitude of the EPP ✓

37) EPP results from:

- K entry
- Na entry
- k & Na entry at once ✓
- Na then K entry

Pathology

Dr. Doaa

38) Sequestrum is:

- dead bone ✓
- dead soft tissue

39) Taphous Gout contains:

- foreign body granuloma

40) A 70 male complains from Severe back pain, x ray shows multiple osteolytic lesions, and they found that the vertebrae are infiltrated by anaplastic cells, the lesion most likely is:

- ewing's sarcoma
- osteoxsarcoma
- chondrosarcoma
- osteofibroma
- metastatic ca ✓

41) Which one of the following tumors show sun ray appearance on x-ray:

- osteosarcoma ✓

42) Synovial sarcoma consists of:

- spindle cells only
- epithelial like cells only
- epithelial like cells & spindle cells ✓

43) The pathogenesis of pemphigus vulgaris is;

- IgG Abs against desmoglein ✓

44) Melanoma prognosis depends mainly on:

- asymmetry
- diameter
- color
- dermis invasion ✓

45) Osteoporosis:

- Decrease normal bone mass with other structural abnormalities
- Decrease normal bone mass without other structural abnormalities ✓
- abnormal bone architecture

Microbiology

Dr. Zain

46) One of the following fungi causes infection for hair, nail and skin:

- epidermophyton
- trichophyton ✓
- microsporum
- piedra

47) Diagnosis of dermatophytes by all of the following except:

- calciflour
- culture
- pcr
- ultraviolet lamp
- gram stain ✓

48) One of the following is incorrect about onchocerciasis:

- can cause blindness
- it is the adult which causes the disease ✓
- its vector called simulium
- mazzotti test is used for diagnose
- ivermectin can be used for mass chemoprophylaxis

49) All are true except

- Folliculitis by pseudomonas aeruginosa
- Fruncles by staphylococcus aureus
- Impetigo by Group A streptococcus "GAS" ✓
- Cellulitis by Group A streptococcus "GAS"

50) All are true about diphtheroids except:

- non pathogenic corynebacterium
- commensals of the skin

- gram + non spore forming
- beta hemolytic ✓

51) Regarding leishmania and leishmanin test, which is wrong?

- L.tropica localized cutaneous: positive test
- L.tropica disseminated cutaneous: negative test
- L. Donovanii disseminated visceral: negative
- L. Brazilensis mucocutaneous: negative ✓

52) Roseollea Infantum:

- HHV 6+7 ✓

53) All of the following can cause the Exanthems except:

- EBV ✓
- Parvovirus B19
- S. pyogenes
- S. aureus

54) كان ال matching الغلط اشي مع ال trepona pallidium بس مش ذاكرة شو هو

Pharmacology Dr. Romany

55) With regard to skeletal muscle relaxants, ONE of the followings is INCORRECT:

- Cisatracurium is not dependent on renal or hepatic mechanisms for terminations of action
- The use of succinylcholine in any form of ocular surgery is unwise
- Baclofen is a direct acting relaxant prescribed for treatment of skeletal muscle spasm ✓
- Rocuronium has the most rapid onset of any non-depolarizing skeletal muscle relaxant
- Dantrolene is the drug of choice in treating malignant hyperthermia

56) Regarding therapy of rheumatoid arthritis, ONE of the followings is INCORRECT:

- Patients treated with hydroxychloroquine should have access to periodic eye examinations
- Beside its analgesic and anti-inflammatory properties, NSAIDs reduce stiffness, slow disease progression and prevent joint deformity ✓
- Anakinra is an IL-1 receptor antagonist while rituximab is a depletory of B lymphocytes
- High-dose of oral steroids may be used for several days to suppress disease flares
- Monitoring of renal and liver function tests, full blood count and chest radiography is imperative during MTX treatment

57) ONE of the followings about therapy of gouty arthritis is CORRECT

- Severe constipation occurs in patients taking high-dose colchicine regimen
- Febuxostat is used to treat gouty attacks once they occur but not to prevent them
- Probenecid is useful in gouty patients with nephrolithiasis
- Indomethacin is commonly used in acute attacks as it has an additional uricosuric action
- Using allopurinol together with mercaptopurine can increase the effects of mercaptopurine ✓

58) Concerning drugs treating osteoporosis, which ONE of the followings is TRUE

- Oral absorption of calcium citrate is decreased with PPIs
- Despite their GIT irritant effect, bisphosphonates have excellent oral bioavailability
- After discontinuation of raloxifene, bone loss returns ✓

- Calcitonin reduce risk of both vertebral and non-vertebral fractures
- Zoledronate is given as a single 5 mg IV infusion over ≥ 15 minutes, once weekly

59) A 15-year-old female presents to clinic with acne with 30-40 comedones on the forehead, cheeks, and chin, with very few erythematous papules, and no scarring. She reports that topical benzoyl peroxide is not working for her despite using it according to instructions for 6 months. She has no involvement of chest or back and has normal menstrual periods. Which of the following is the BEST addition to her acne treatment at this time?

- Oral Isotretinoin
- Oral Minocycline
- Topical antibiotic
- Topical tretinoin ✓

60) Regarding topical antimicrobial drugs, ONE of the followings is INCORRECT?

- Neomycin has excellent activity against gram negative bacteria
- Nystatin is a topical treatment for superficial *Candida albicans* infections
- Ketoconazole oral absorption increased by antacids ✓
- Valacyclovir is used orally for treating herpes zoster infections
- The antibiotics polymyxins are highly nephrotoxic and are thus only used topically

61) With regard to treatment of rheumatoid arthritis and osteoarthritis, Which ONE is INCORRECT?

- Colchicine is an effective analgesic in osteoarthritis ✓
- Adalimumab not infliximab is given subcutaneously in rheumatoid arthritis
- If pain relievers haven't worked for knee osteoarthritis, hyaluronic acid injections might do the trick.
- Tofacitinib is a JAK inhibitor interfering with the inflammatory processes in rheumatoid arthritis
- Taken orally for rheumatoid arthritis, methotrexate is typically started at a single dose of 7.5 mg given once weekly

62) Concerning treatment of psoriasis, ONE is CORRECT:

- Methotrexate is used selectively in treatment of psoriasis with liver disease
- Acetylsalicylic acid is one of the most commonly used keratolytics
- Tar is used only to help reduce the inflammation, itching and scaling of psoriasis
- Rebound flare of psoriasis can occur after abrupt cessation of topical steroid therapy ✓
- Acitretin is a topical retinoid used in the treatment of severe resistant psoriasis

Biochemistry
Dr. Mazhar

63) Sialoproteins are:

- Poly Glu ✓
- Poly Gln

64) Pompe disease:

- Causes cardiomegaly
- affect liver, muscle, heart
- deficiency in alpha 1-4 lysosomal glucosidase enzyme
- all of the above ✓

65) All the following statements are false, EXCEPT:

- collagen type V is the main bone protein
- chondroitin sulfate consists of repeated peptide units
- CS-PG III is bone specific protein ✓

Public Health

Dr. Moawiah

66) All are true except:

- annual prevalence of Back pain range 30-50%, with point prevalence 40% ✓

SGD

Dr. Doaa + Dr. Zain

67) question about carpal tunnel syndrome, which on is incorrect?

- thenar muscles affected
- superficial cutaneous part of median nerve ✓

68) Case about carpal tunnel syndrome, which one is incorrect?

- decreasing the size of carpal tunnel
- diagnosis can be done by electrophysiological studies
- Phalen's test can help in diagnosis
- The best treatment is physio therapy and steroid injection ✓

69) As a complication of Rheumatoid arthritis in Eyes:

- Glaucoma
- Cataract
- Retinal Detachment
- Kerato-conjunctiva sicca ✓

70) Which of the following joints aren't involved in RA:

- Distal interphalangeal joints ✓

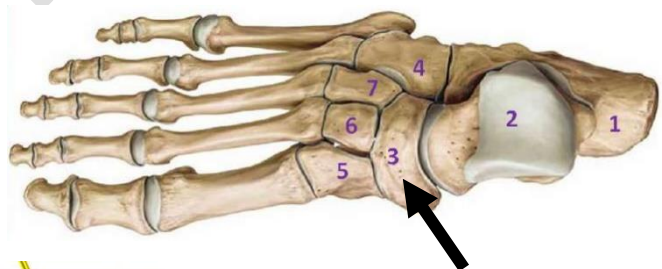
- Labs -

Anatomy Lab

Dr. Osama

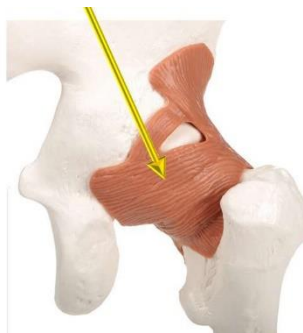71) arrow represent:

- calcaneus
- cuboid
- talas
- Navicular ✓
- cuneiform



72)

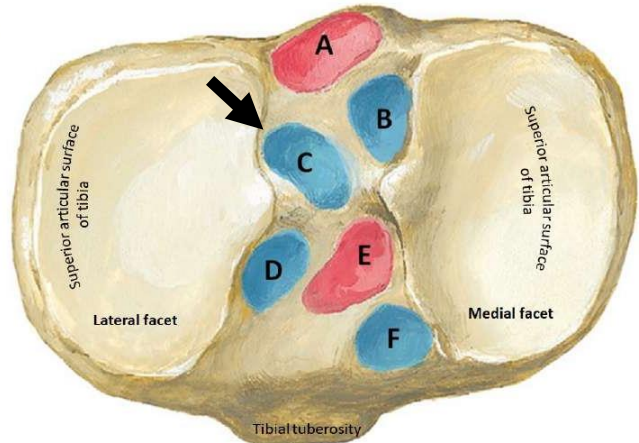
- ischiofemoral ligament ✓
- pubofemoral ligament
- iliofemoral ligament



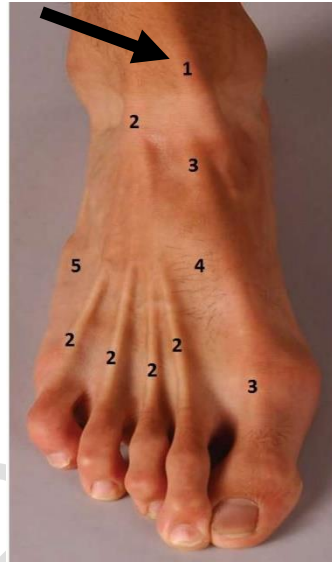nee: Interior (Superior View)

73)

Attachment of posterior cruciate ligament
Attachments of posterior horn of medial meniscus
Attachments of posterior horn of lateral meniscus ★
Attachments of anterior horn of lateral meniscus
Attachment of anterior cruciate ligament
Attachments of anterior horn of medial meniscus

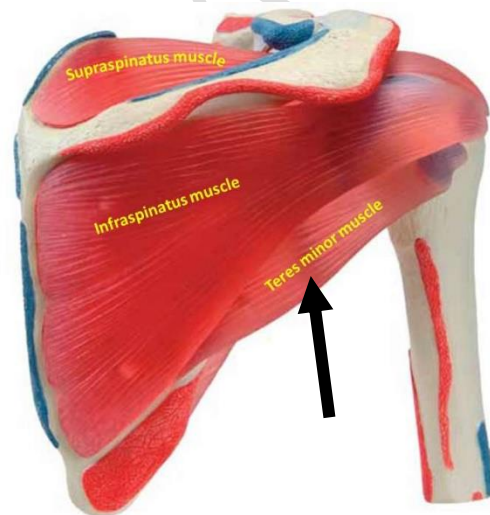


74)

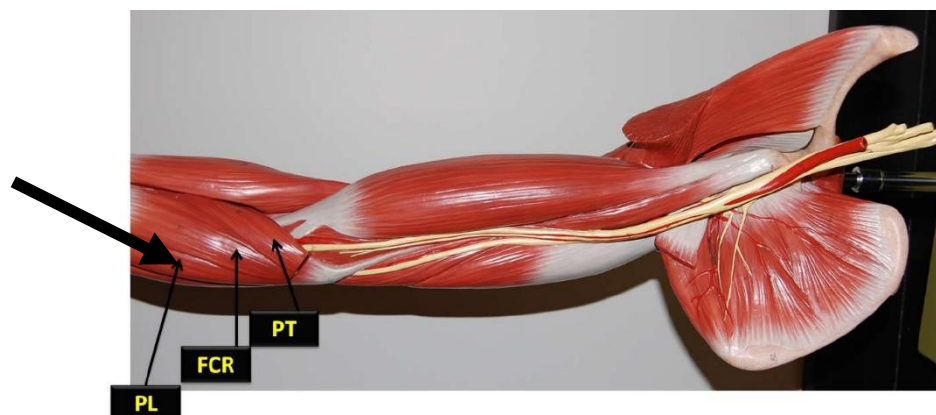


1. Tibialis anterior
2. Extensor digitorum longus
3. Extensor hallucis longus
4. Extensor hallucis brevis
5. Fibularis (peroneus) tertius

75)

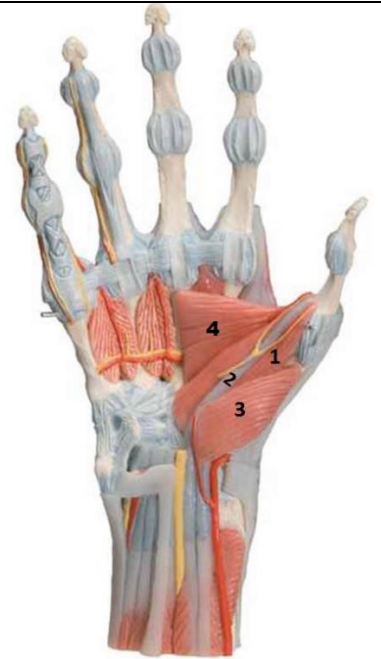


76)



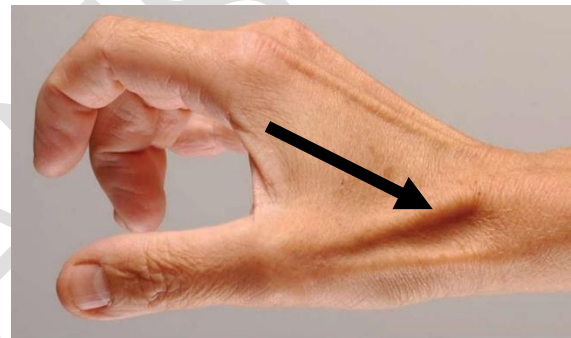
77) which flex the thumb?

- 3 only
- 4 only
- 1+2+3+4
- 1+2+3 ✓



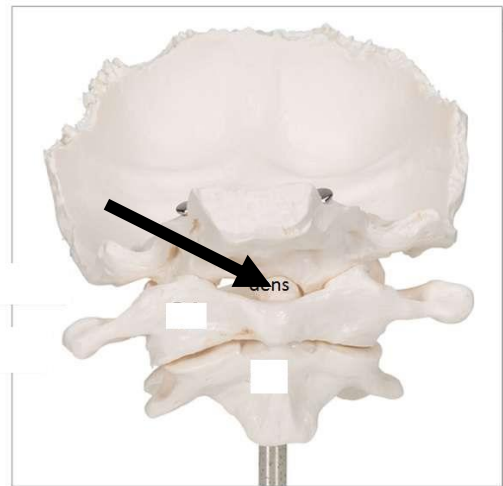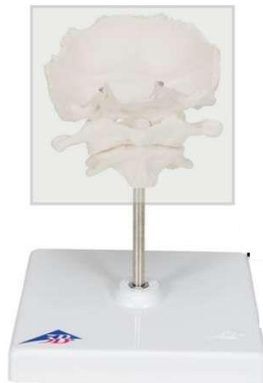78)

- Extensor pollicis longus tendon ✓
- Extensor pollicis brevis tendon
- Abductor pollicis longus tendon

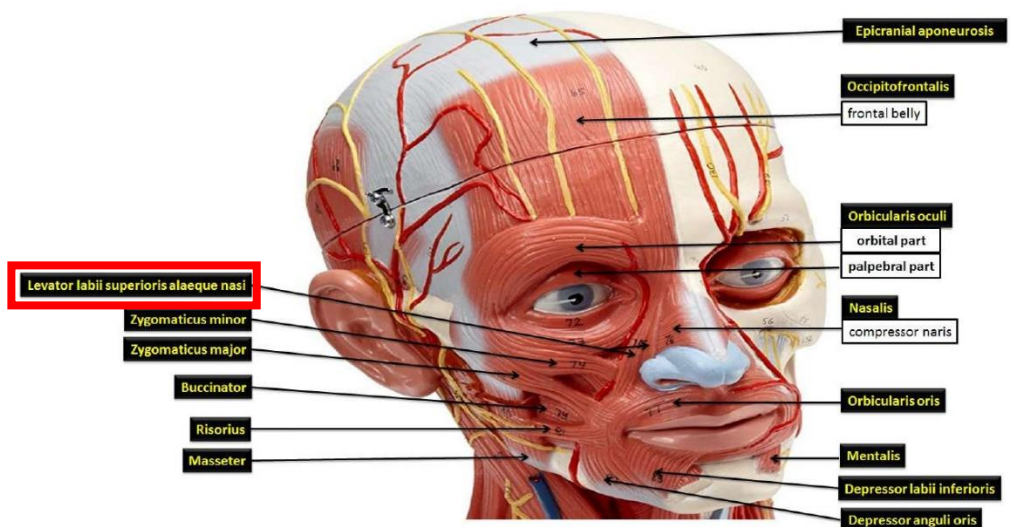


79)

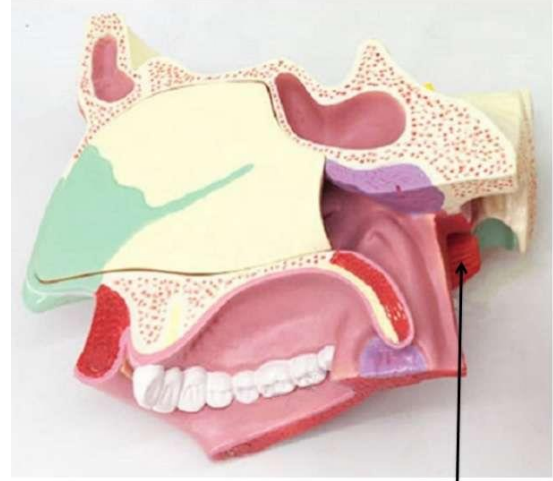
- dens ✓



80)



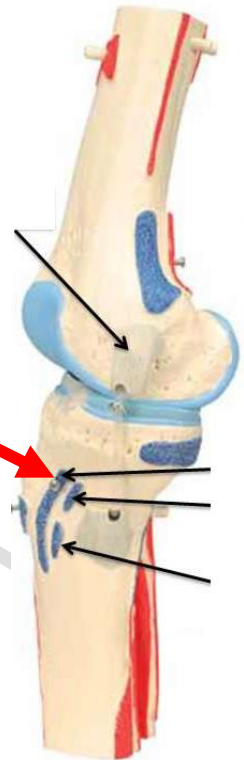
81)



Lateral pterygoid

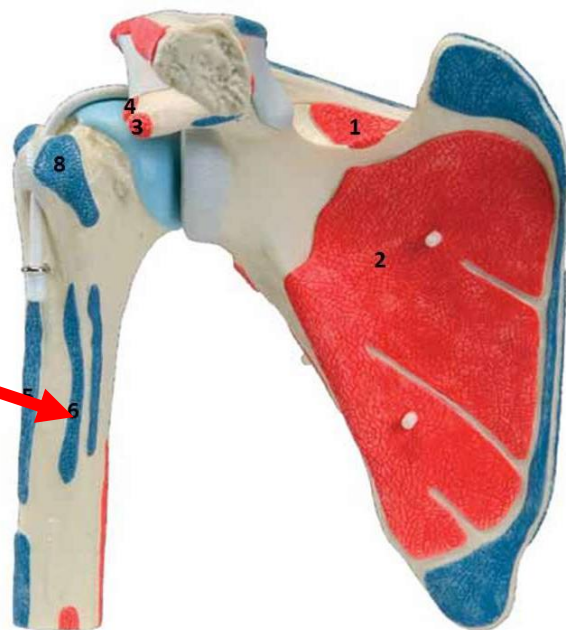
82) Red arrow?

- Insertion of Gracilis muscle
- Insertion of Sartorius muscle ✓
- Insertion of semitendinosus muscle
- Insertion of semimembranosus muscle



83)

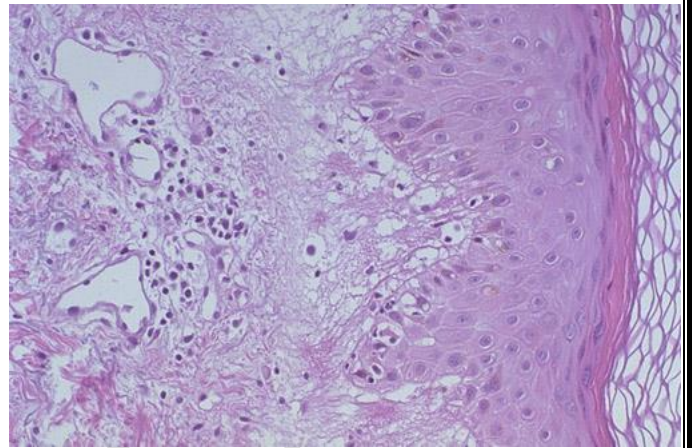
- | |
|---|
| Supraspinatus muscle, origin |
| Subscapularis muscle, origin |
| Coracobrachialis muscle, origin |
| Short head of biceps brachii muscle, origin |
| Pectoralis major muscle, insertion |
| ★ Latissimus dorsi muscle, insertion |
| Teres major muscle, insertion |
| Subscapularis muscle, insertion |



Pathology Lab
Dr. Doaa

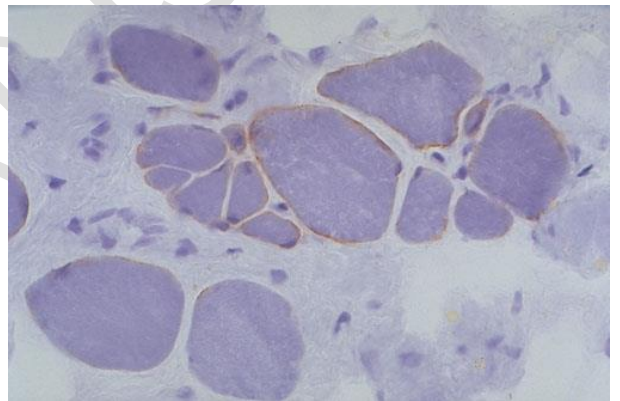
84)

- cytotoxic CD8 cell ✓



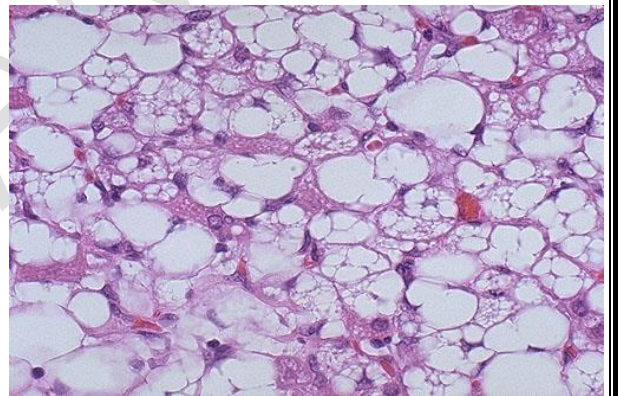
85)

- Becker type muscular dystrophy ✓



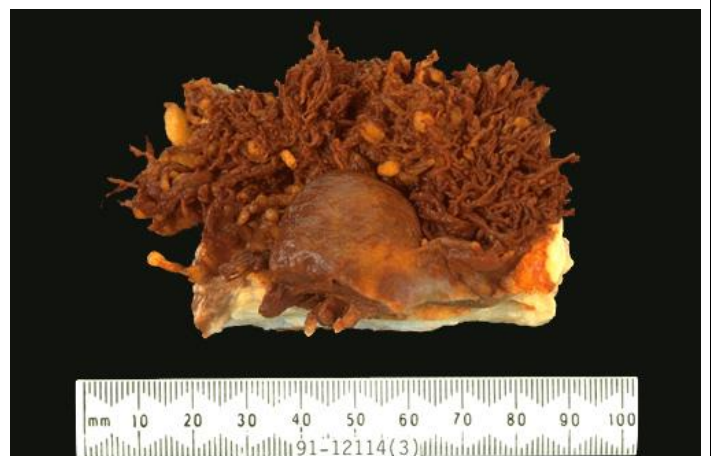86)

- lipoblasts ✓



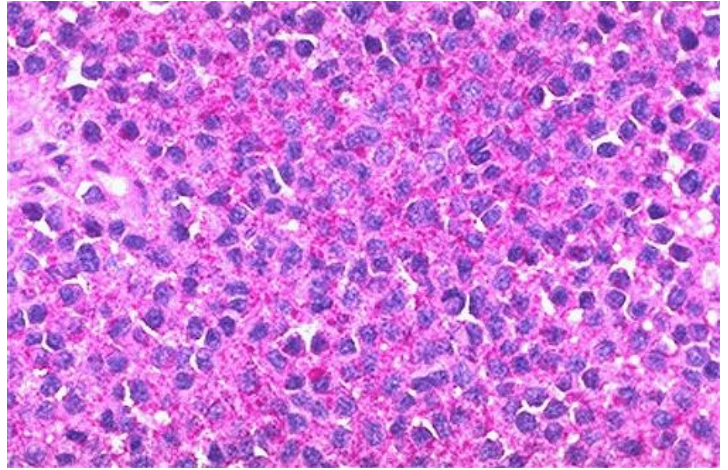
87)

- Pigmented villonodular synovitis ✓



88) here in this case PAS stain shows

- Amyloid
- Lipoblasts
- Glycogen ✓



89)

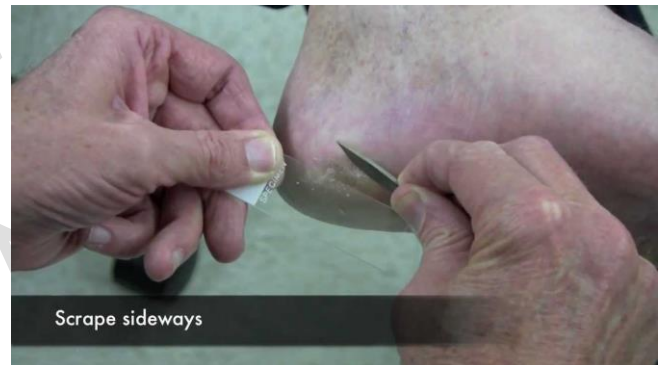- osteosarcoma ✓



Microbiology
Dr. Noor

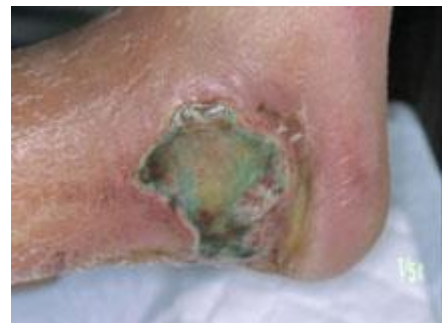90)

- Used specially with fungal infections ✓



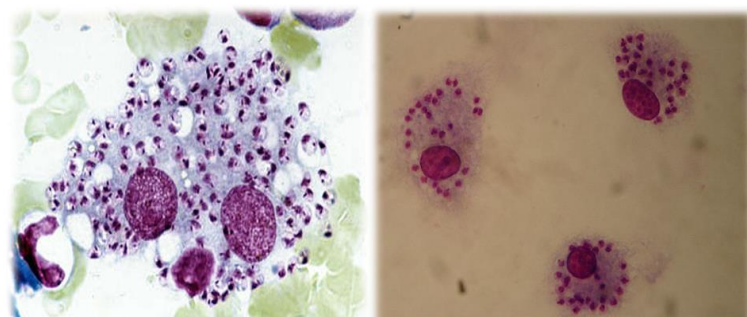
91)

- Pseudomonas aeruginosa ✓



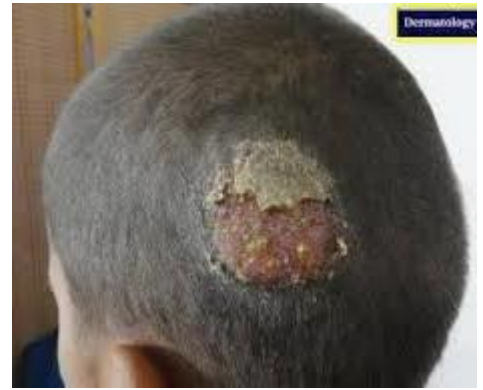92)

➔ Macrophages with intracellular amastigoite cells



93)

- Tinea capitis ✓



Sorry for any mistake

Good luck ❤️

GLORIANS
TEAM

