

ENDOCRINE SYSTEM

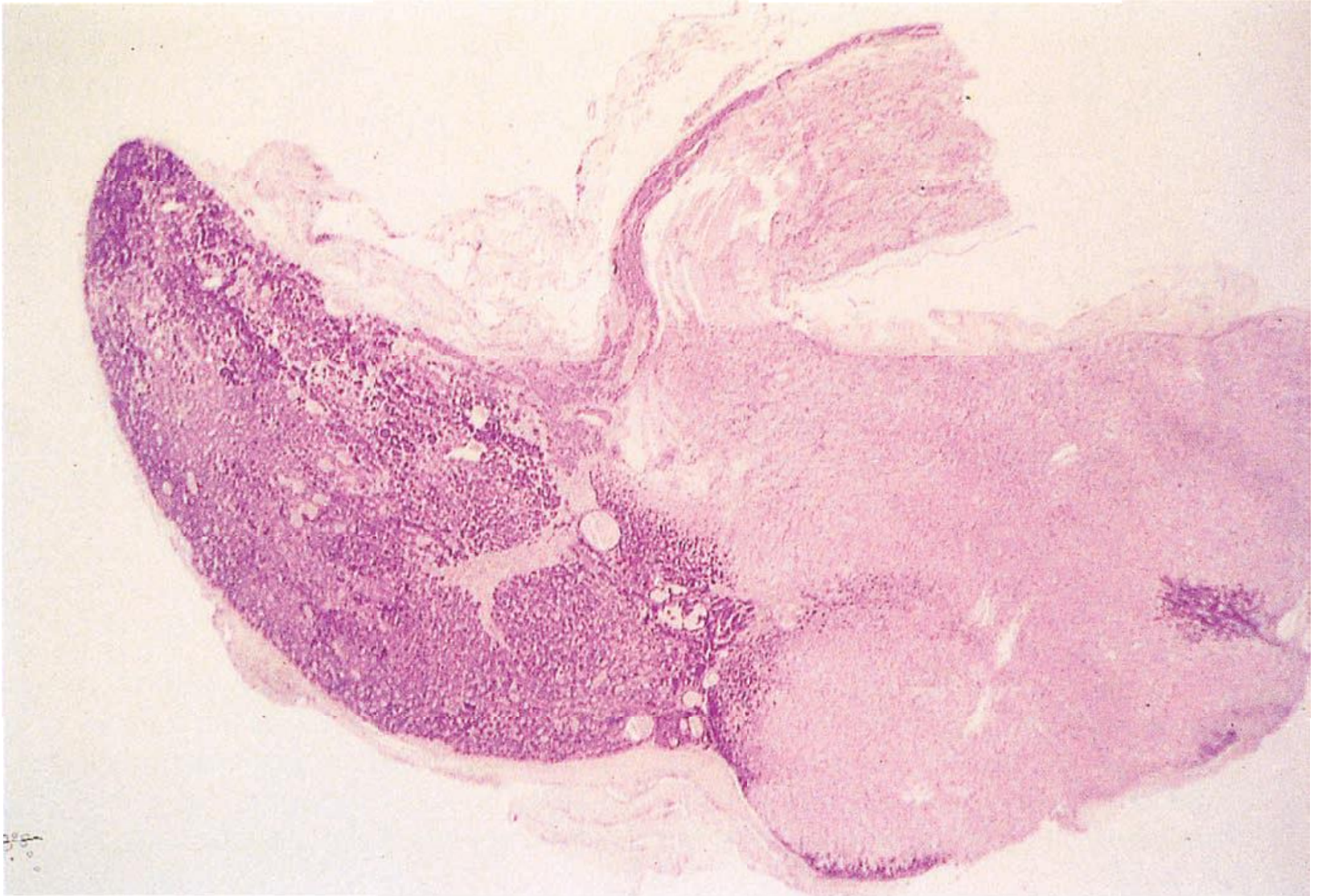HISTOLOGY LAB





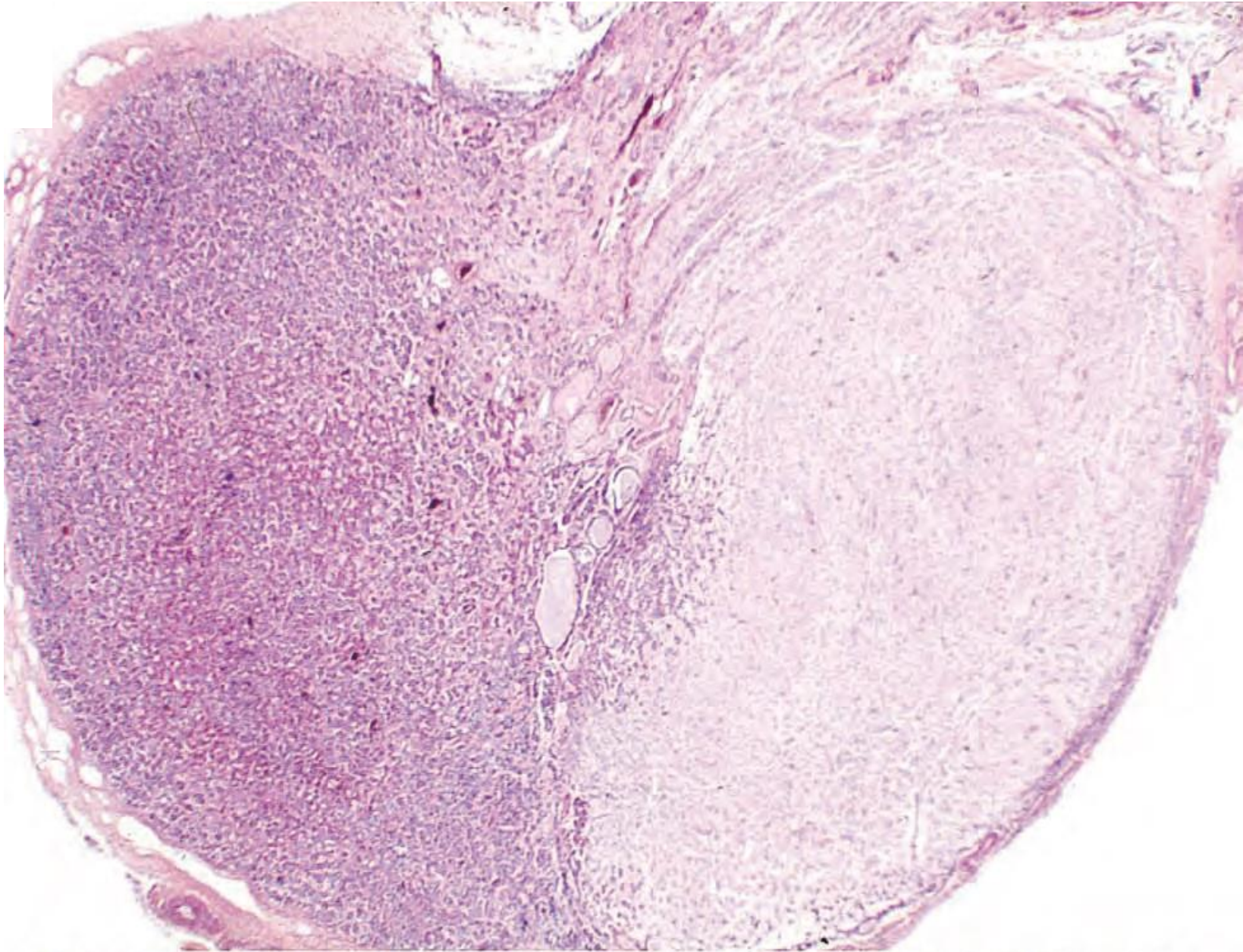
TEST

YOURSELF



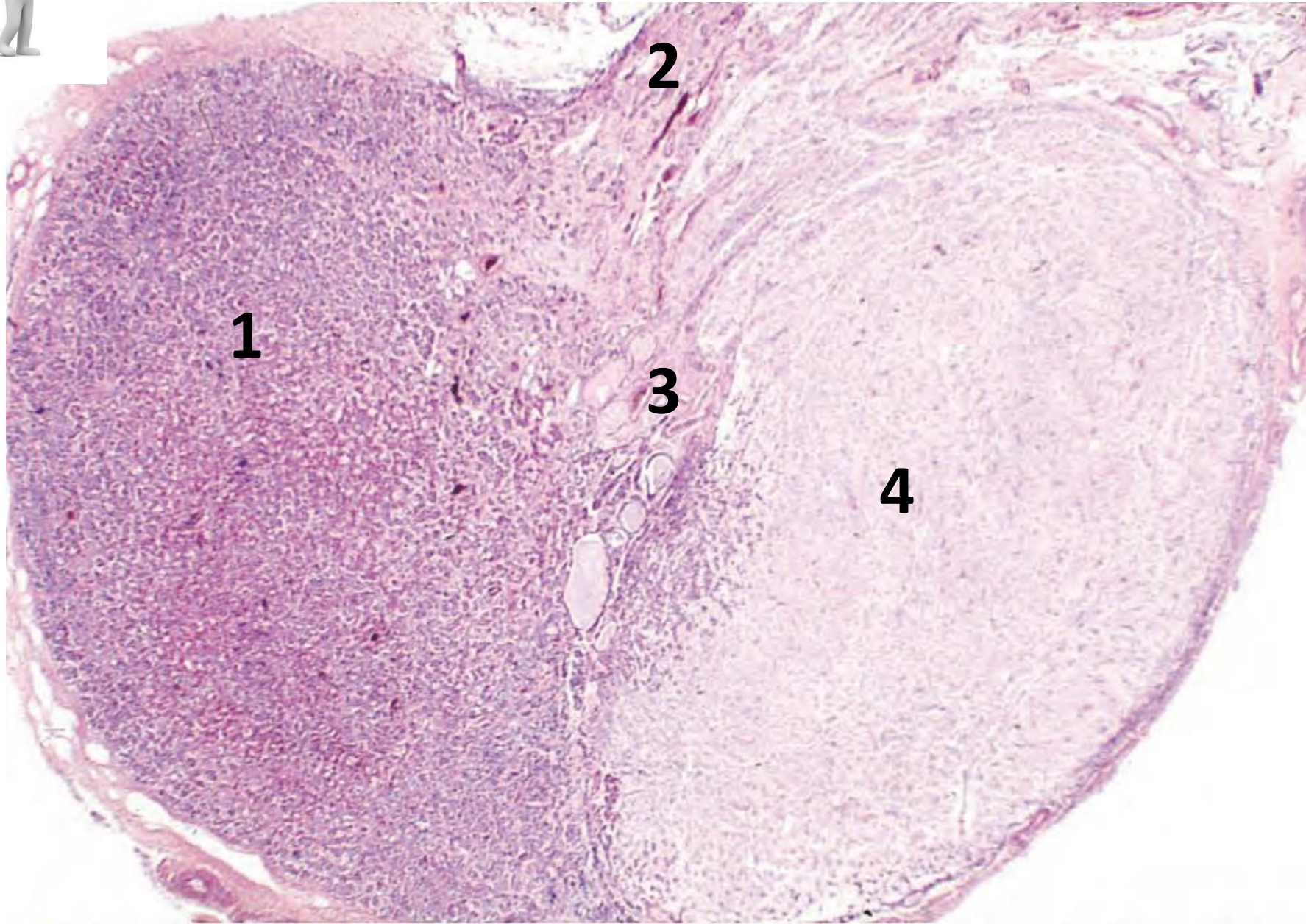


Pituitary Gland



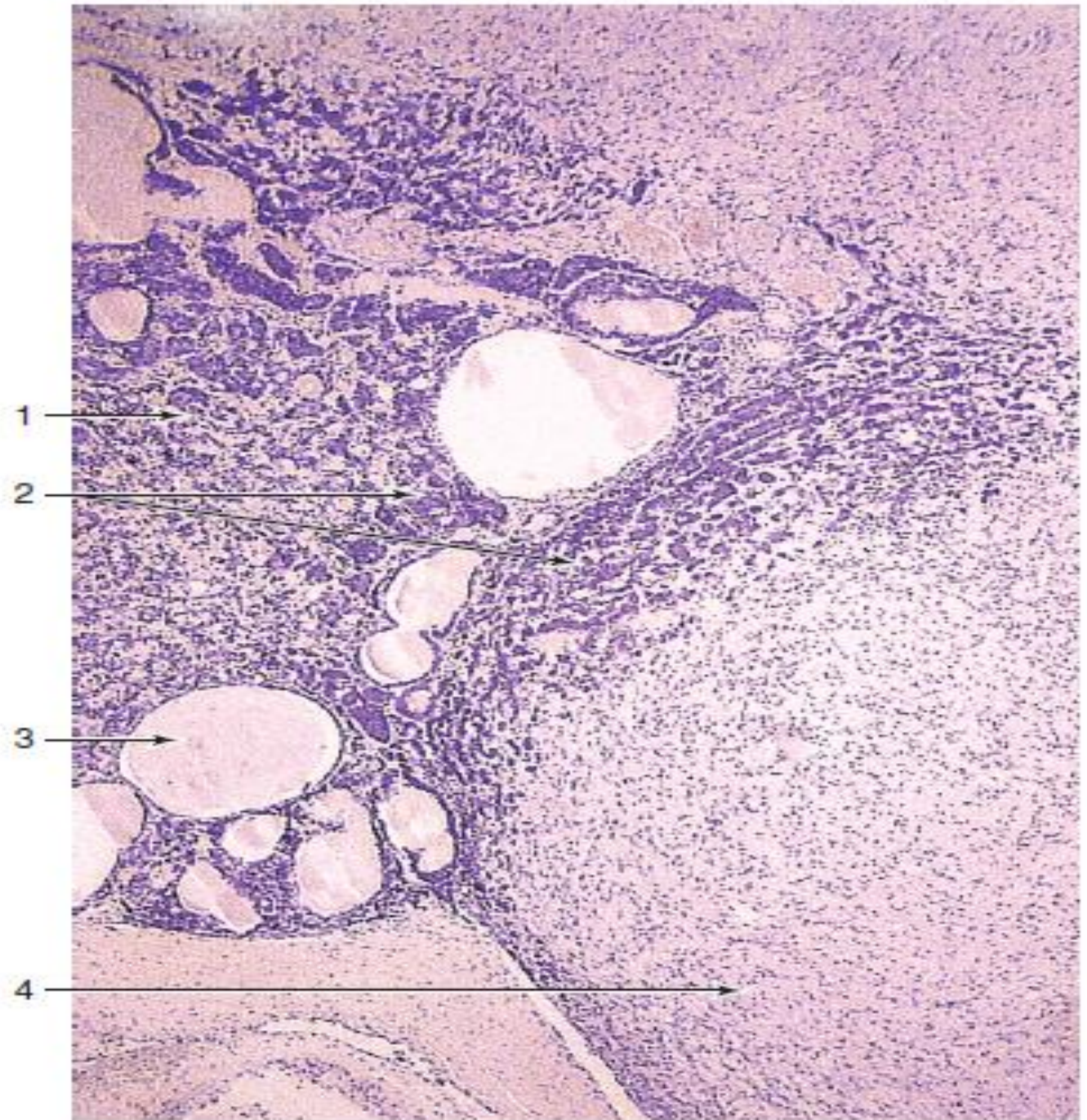


Pituitary Gland



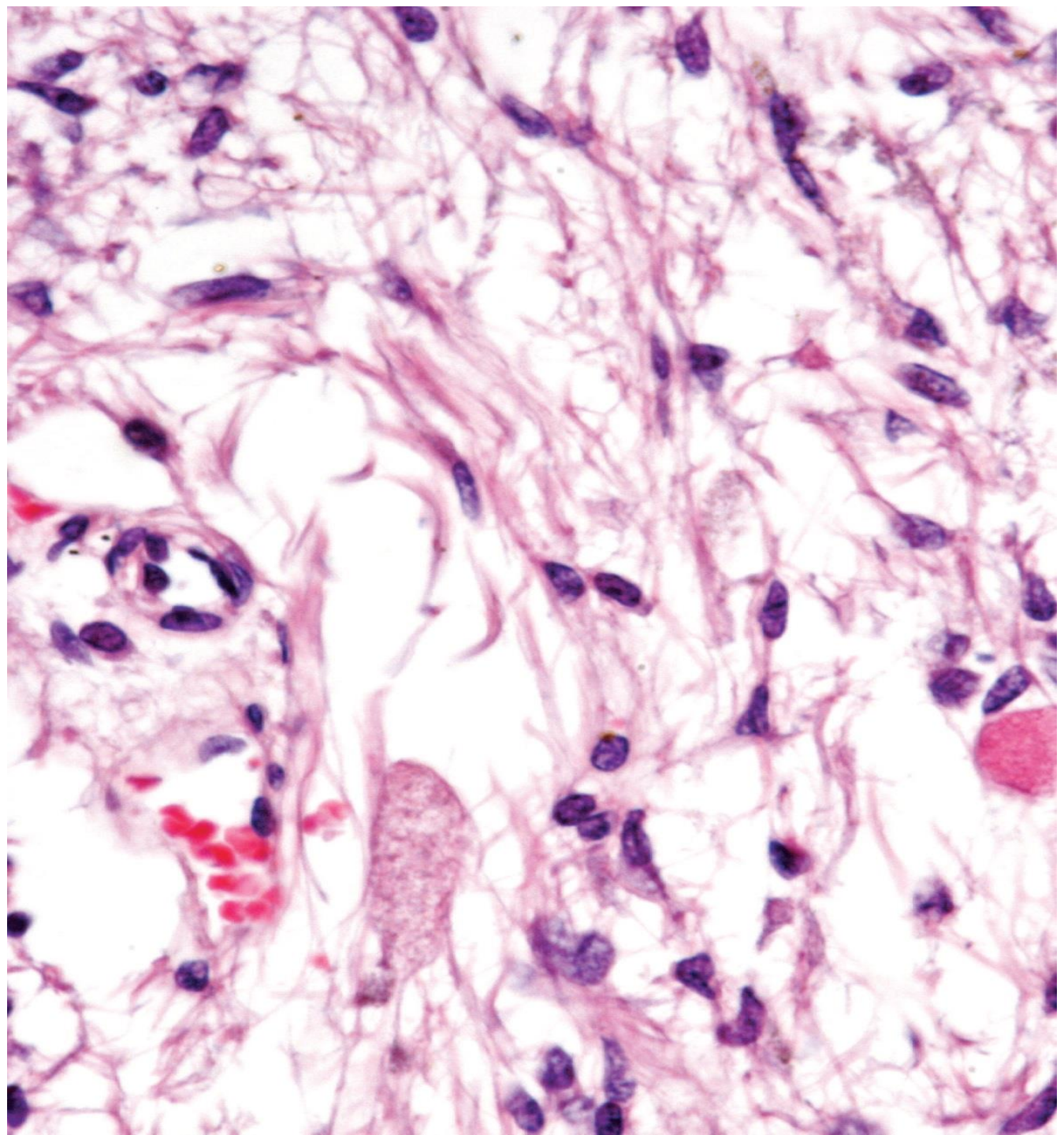


- 1- Pars Distalis**
- 2- Pars Tuberalis**
- 3- Pars Intermedia**
- 4- Pars Nervosa**



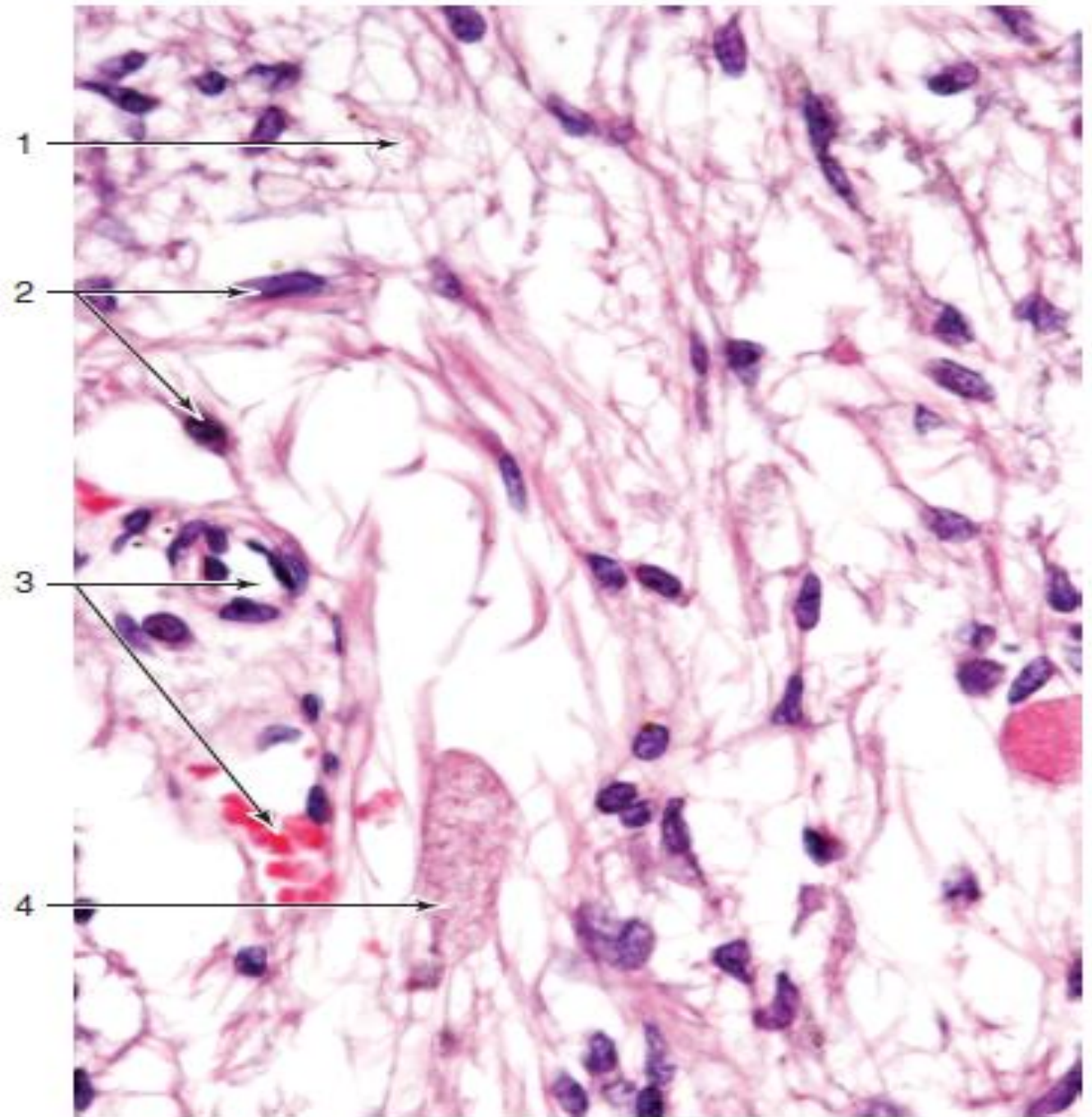


- 1. Pars distalis**
- 2. Pars intermedia with numerous basophils**
- 3. Colloid-filled cysts**
- 4. Pars nervosa**



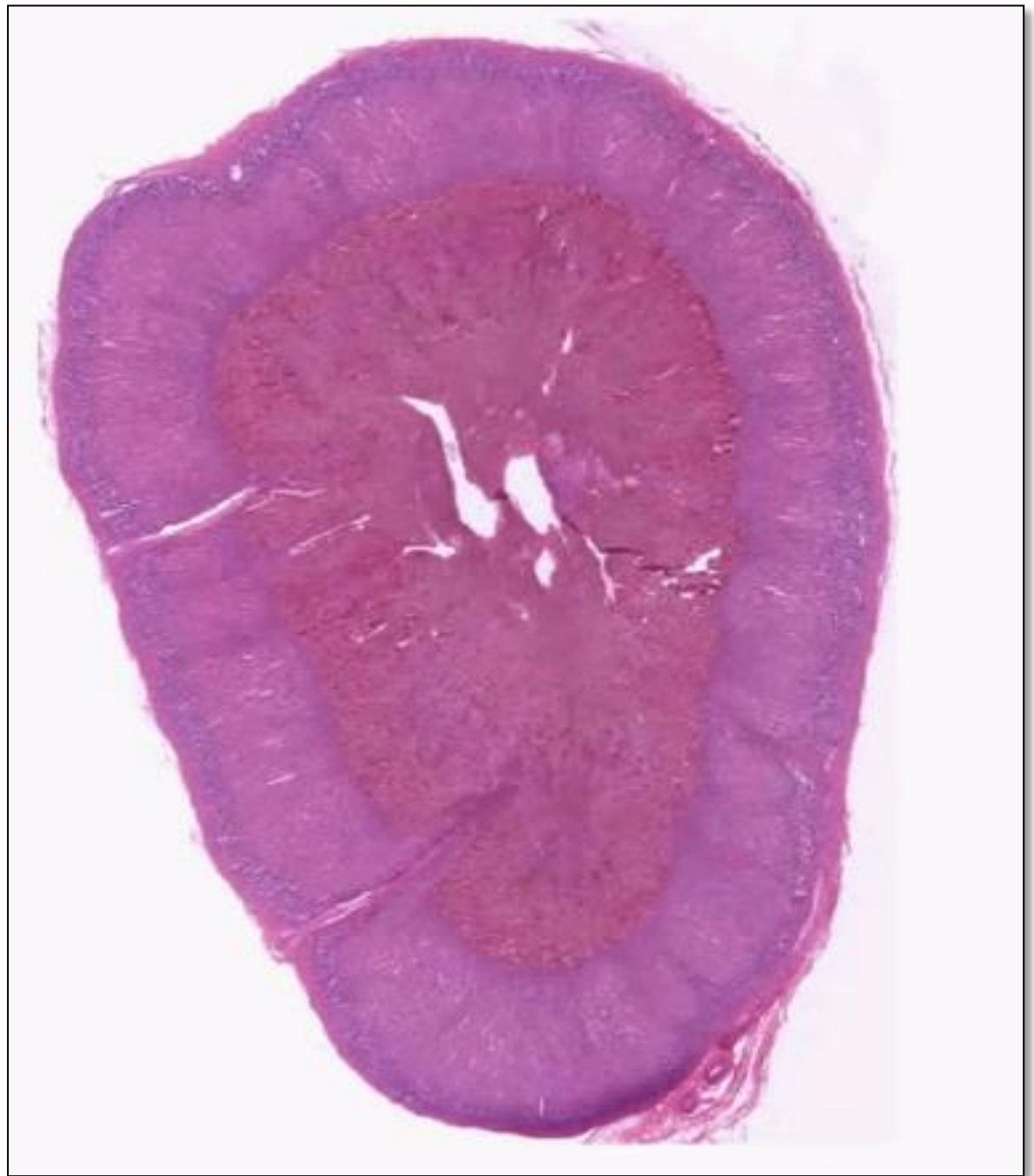

NEUROHYPOPHYSIS



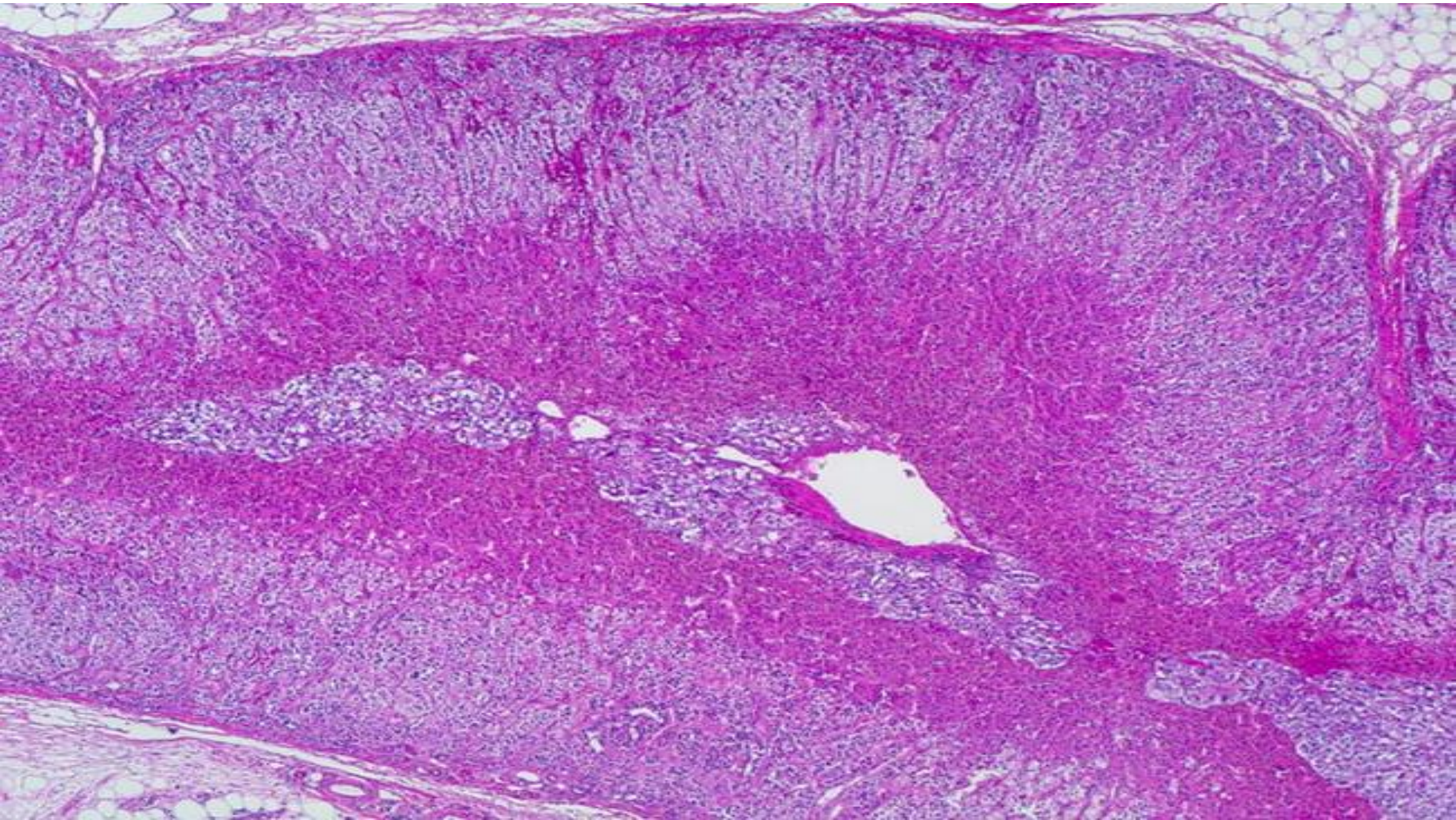


- 1. Axons from hypothalamus**
- 2. Pituicyte**
- 3. Capillaries**
- 4. Neurosecretory (Herring) body**



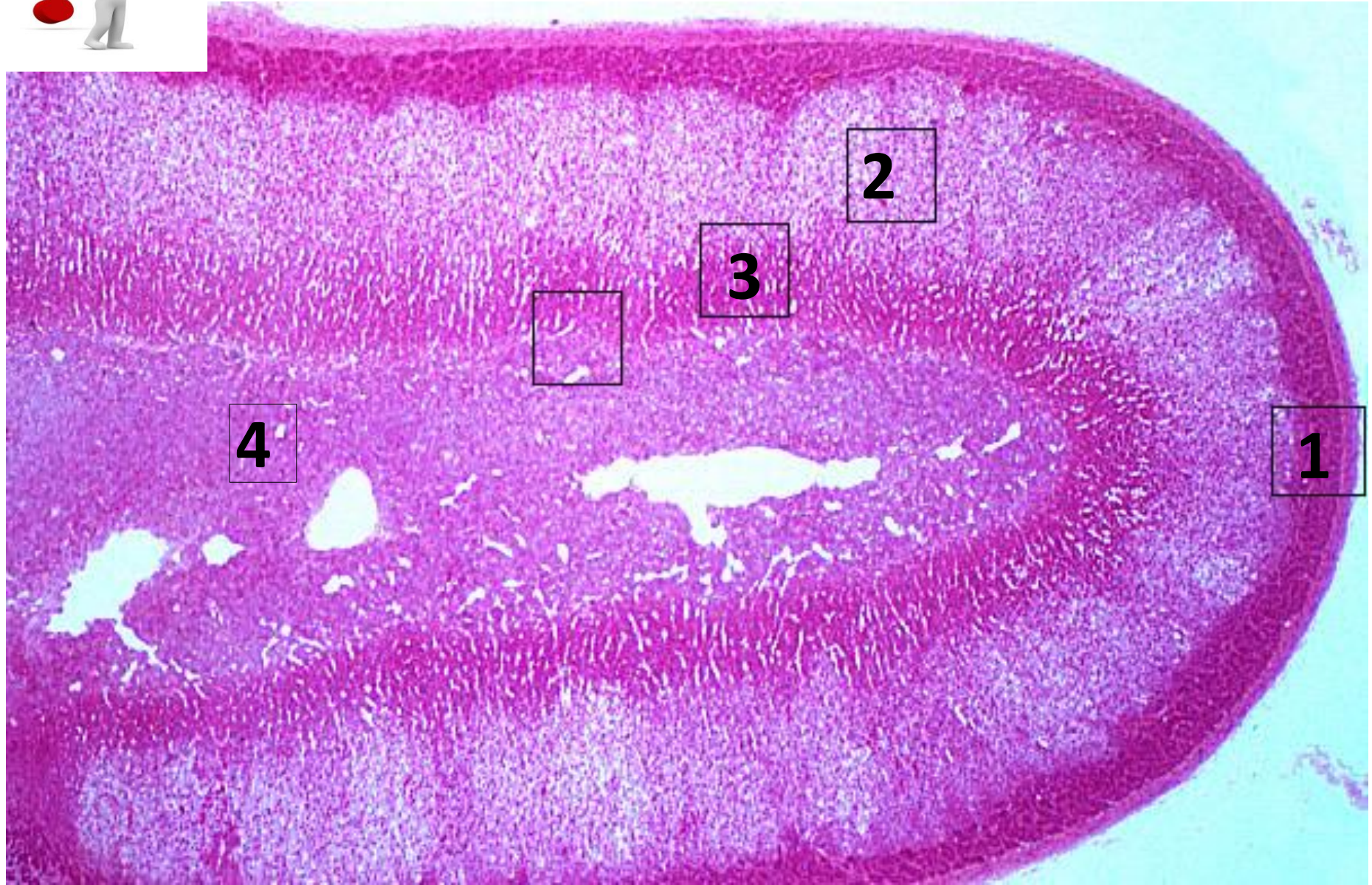


Adrenal Gland



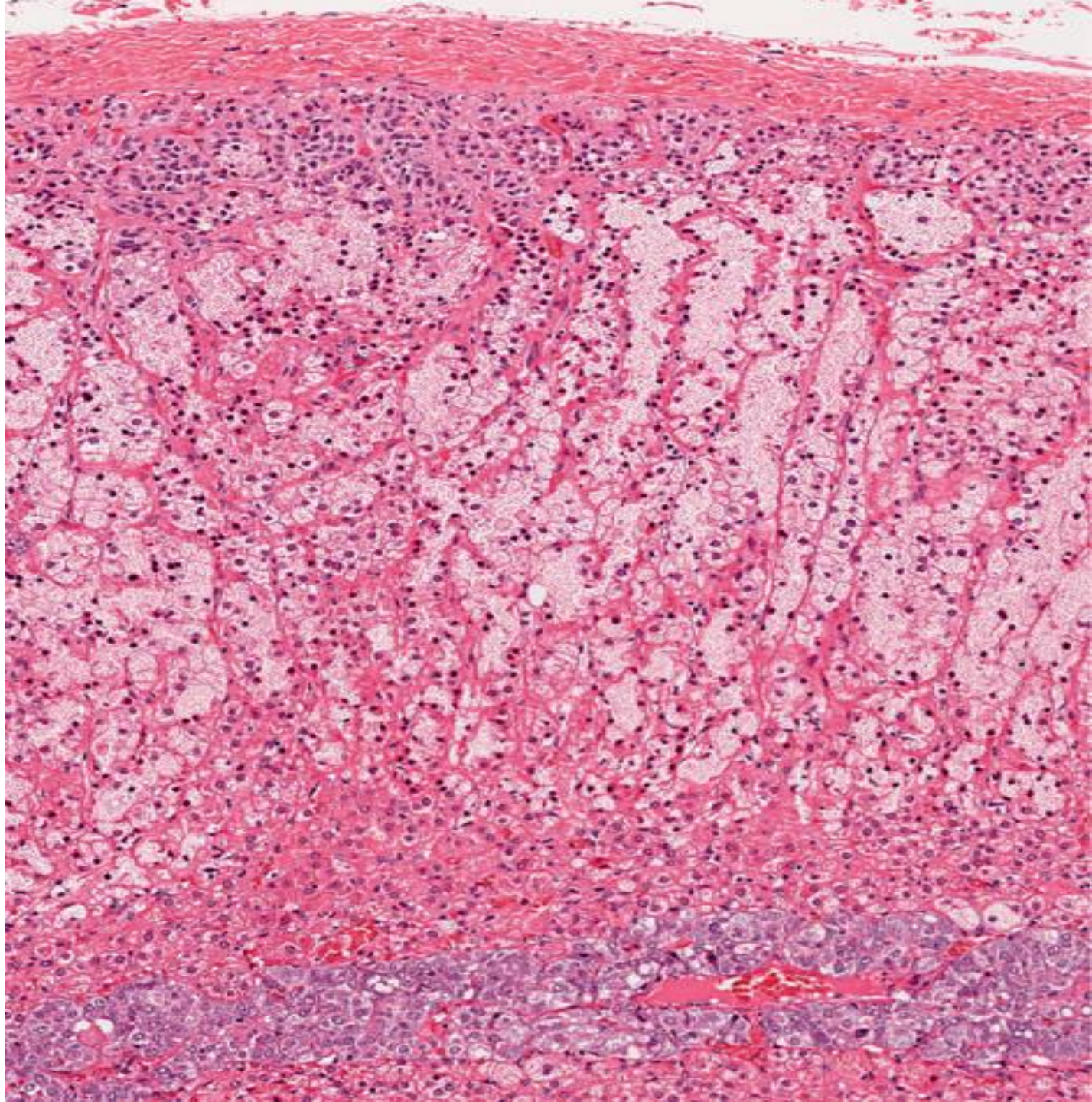


Adrenal Gland



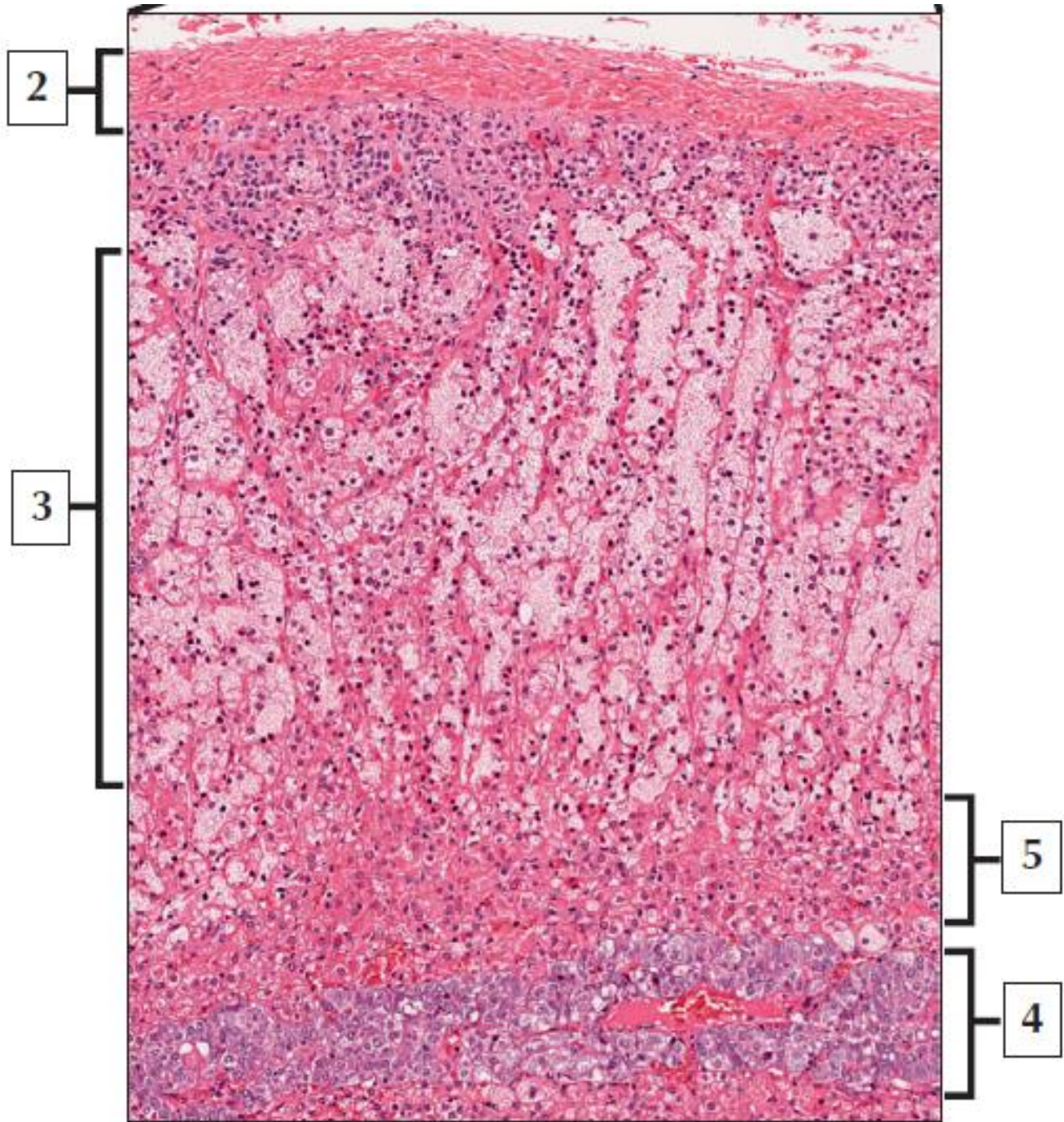


- 1. Zona Glomerulosa**
- 3. Zona Fasciculata**
- 3. Zona Reticularis**
- 4. Adrenal Medulla**



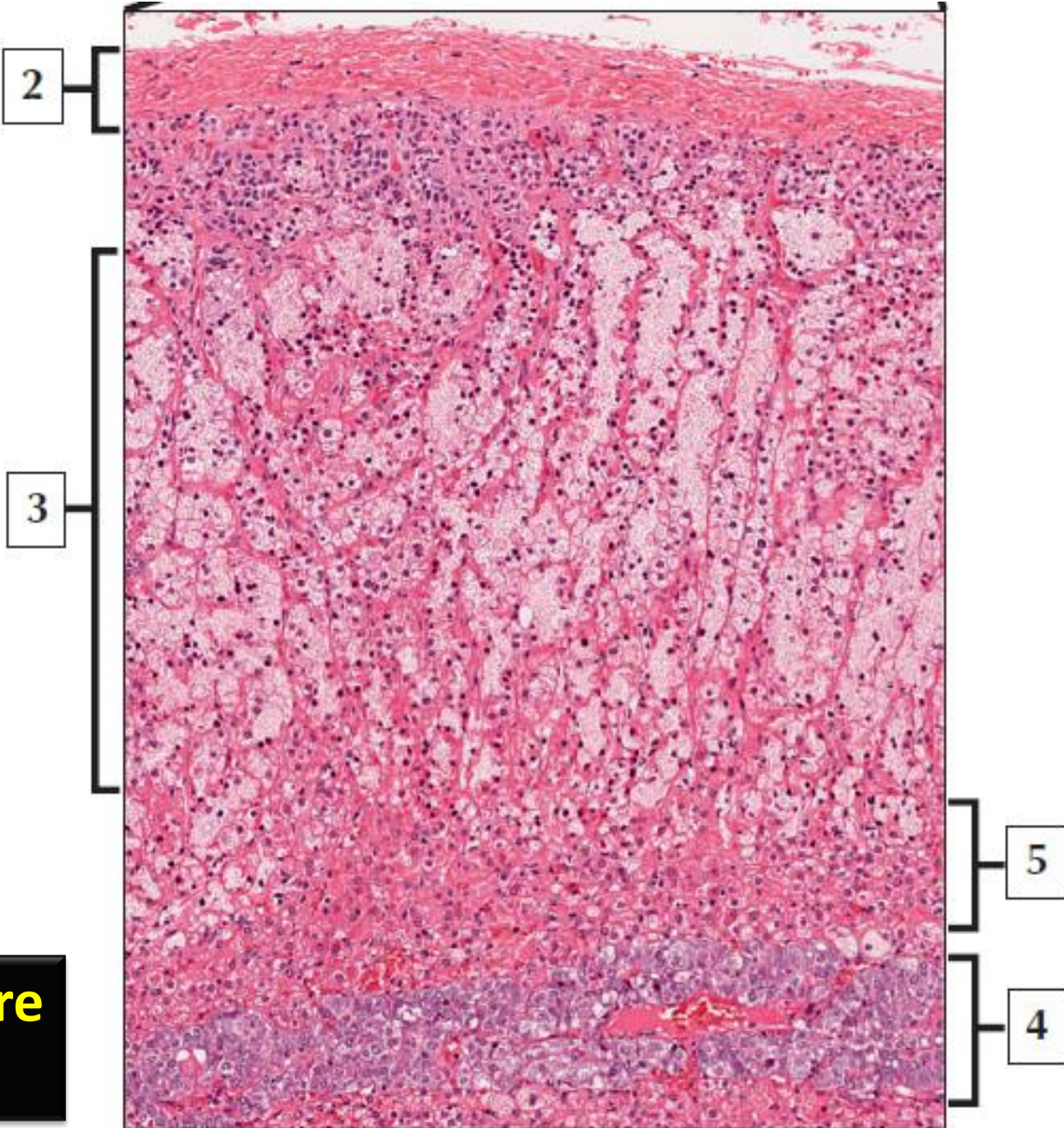


**Adrenal gland
Cortex & Medulla**





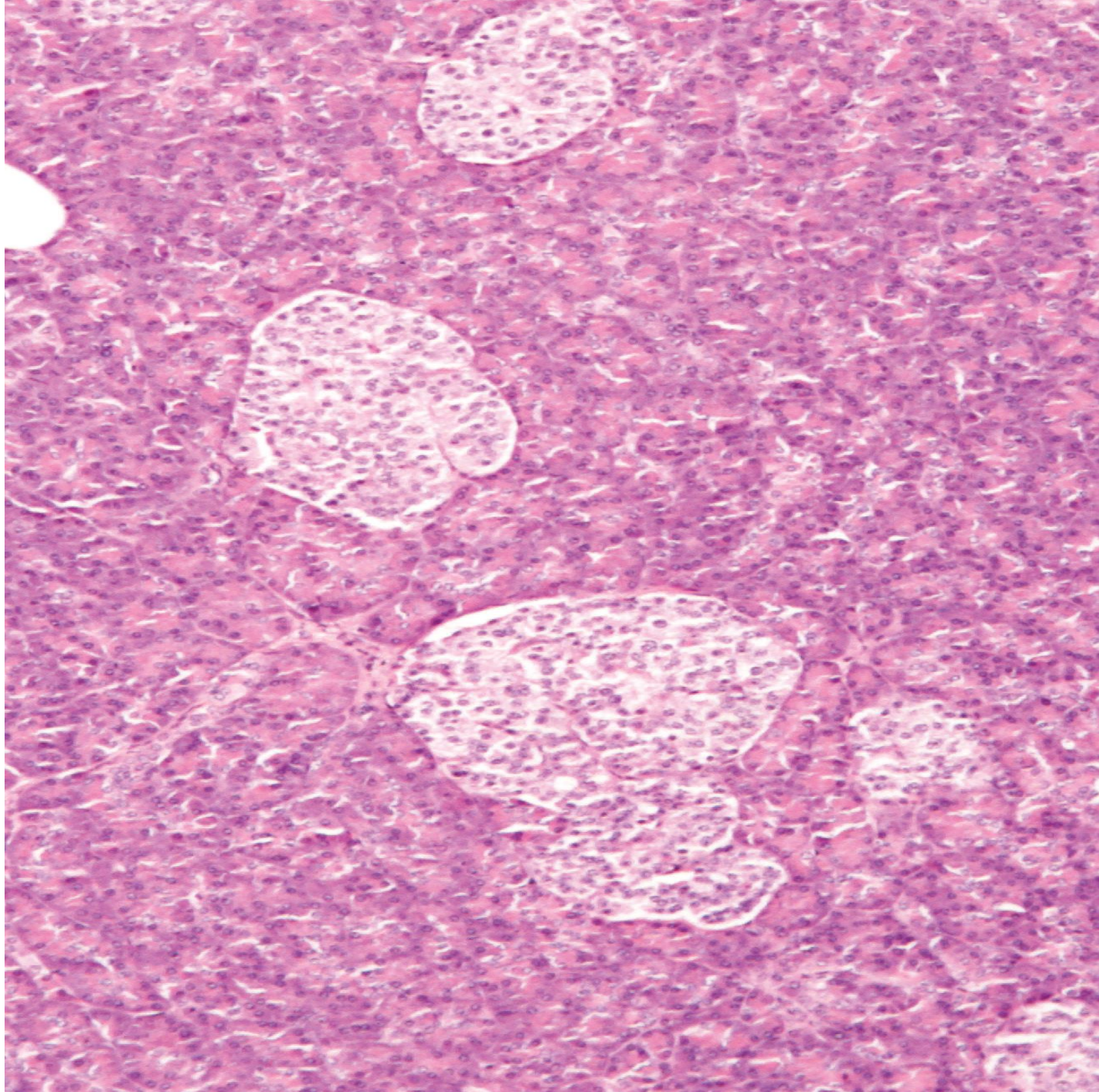
2. Capsule
3. Zona fasciculata
4. Medulla
5. Zona reticularis



Chromaffin cells are found in?



Adrenal Medulla (4)



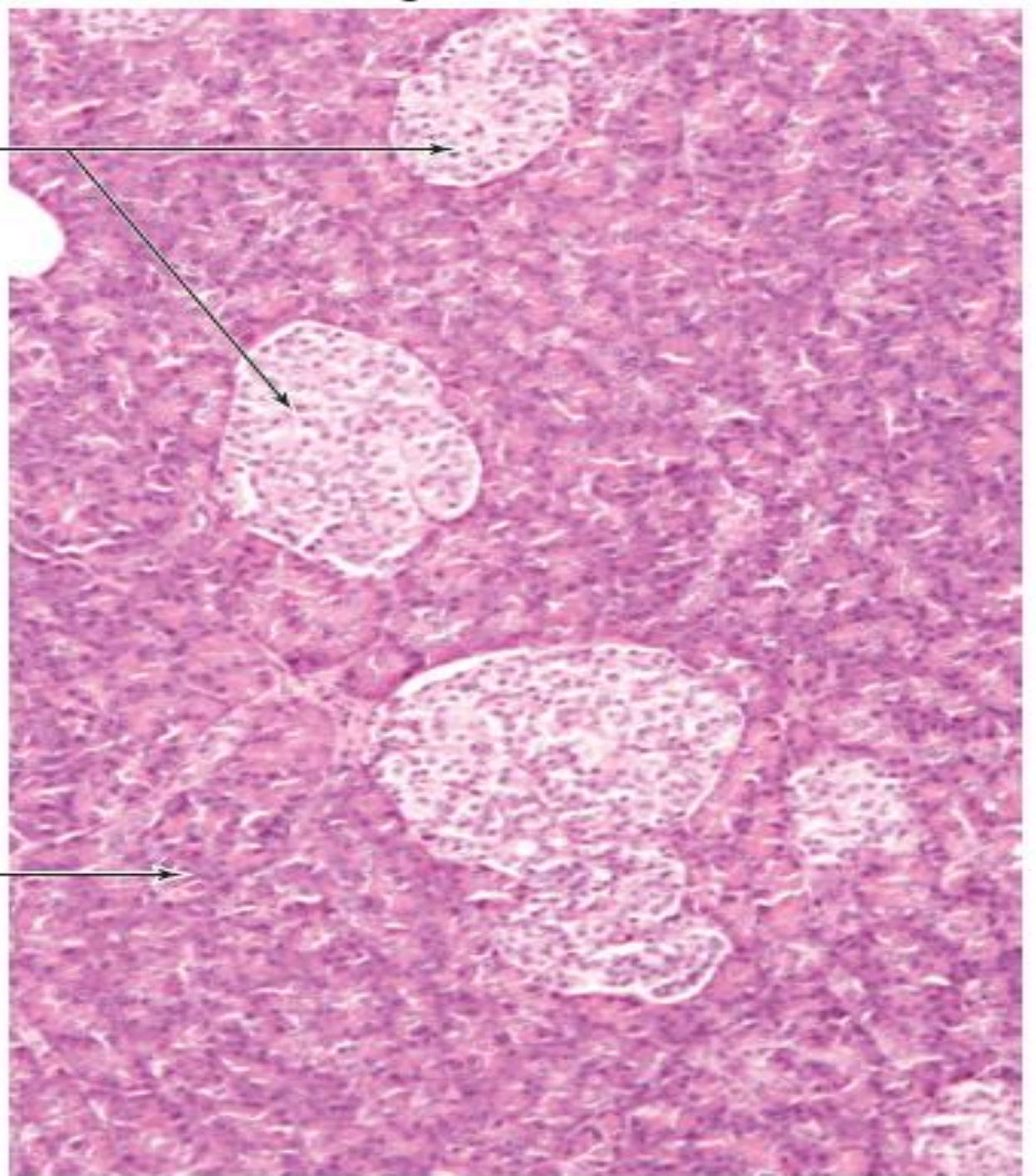


Pancreas



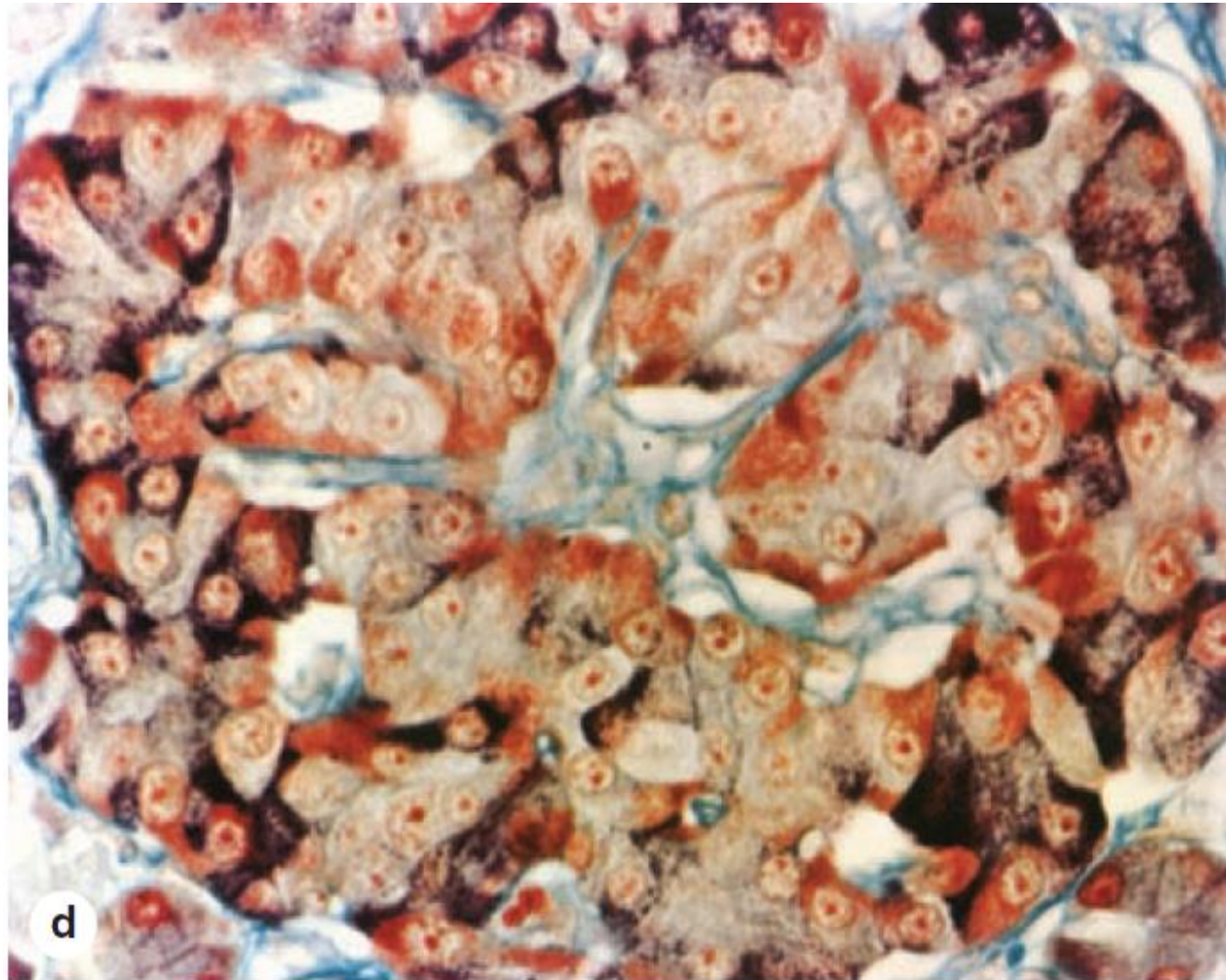
2

3





- 1. Pancreas**
- 2. Pancreatic islets (of Langerhans)**
- 3. Exocrine acinar tissue**



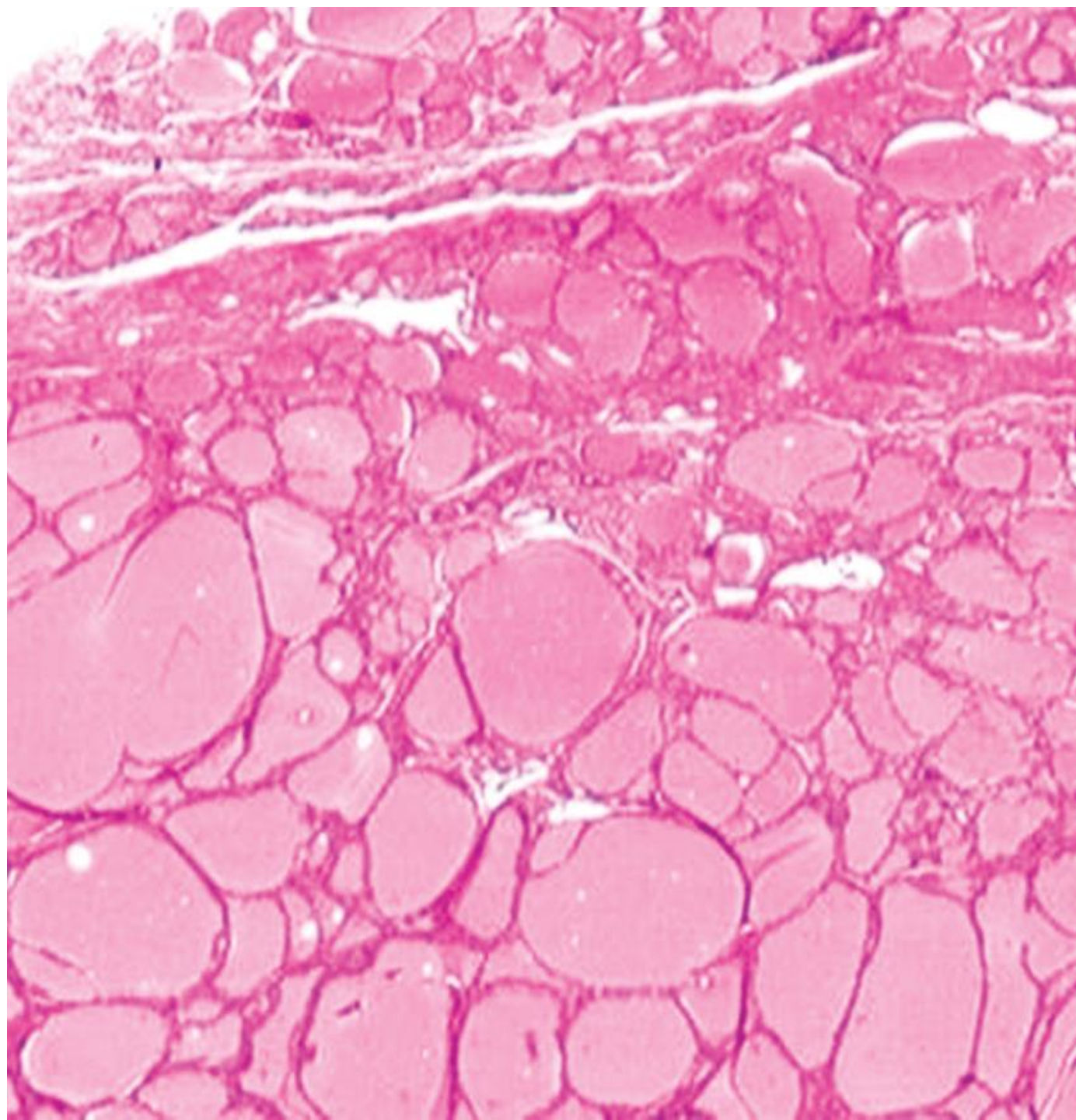
Pancreatic islets (of Langerhans)

- ❖ **Modified aldehyde fuchsin and light green stain:**
 - deep brownish purple ??
 - brownish orange ??



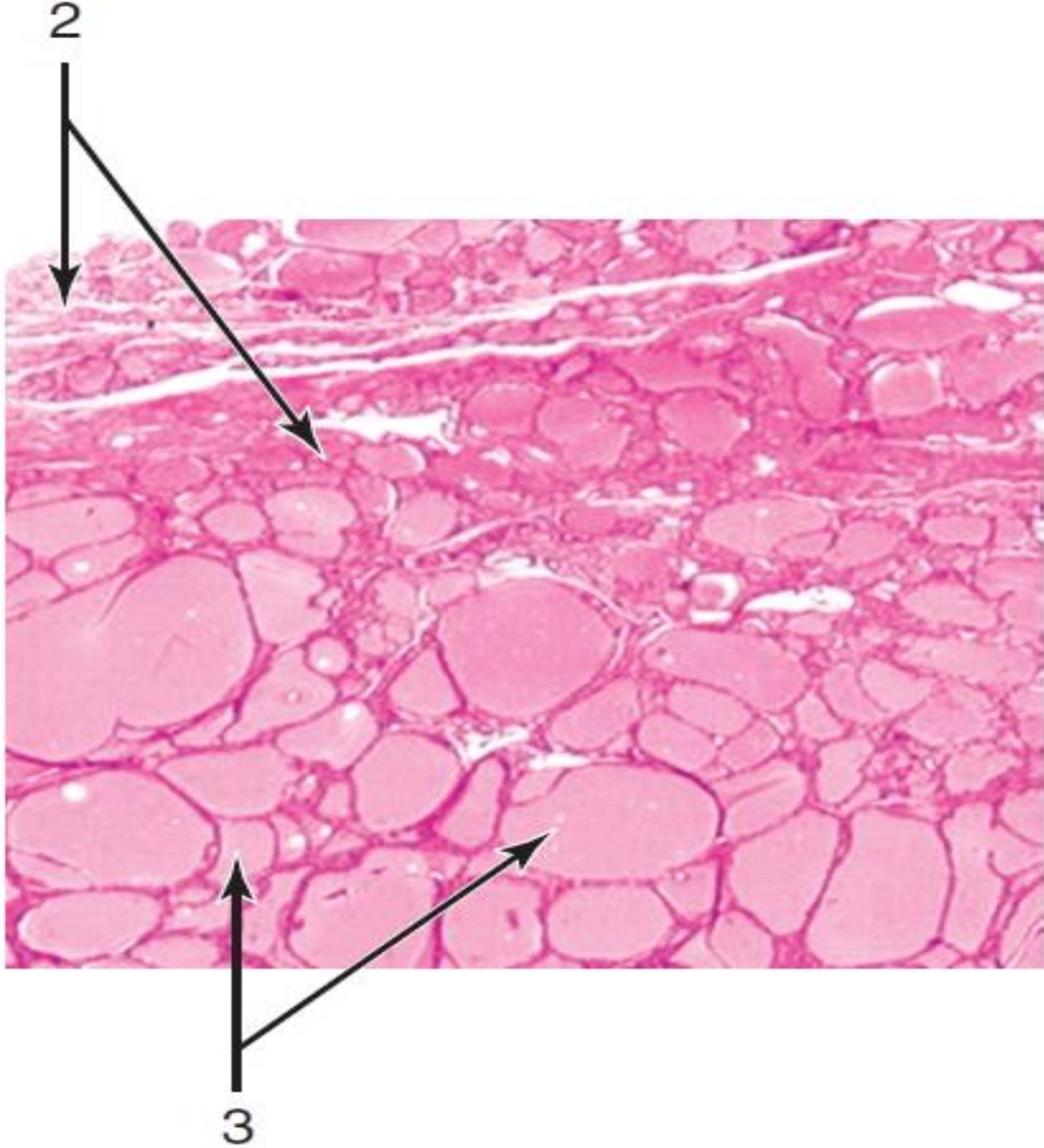
❖ Modified aldehyde fuchsin and light green stain :

- α cells are a deep brownish purple
- β cells granules are brownish orange



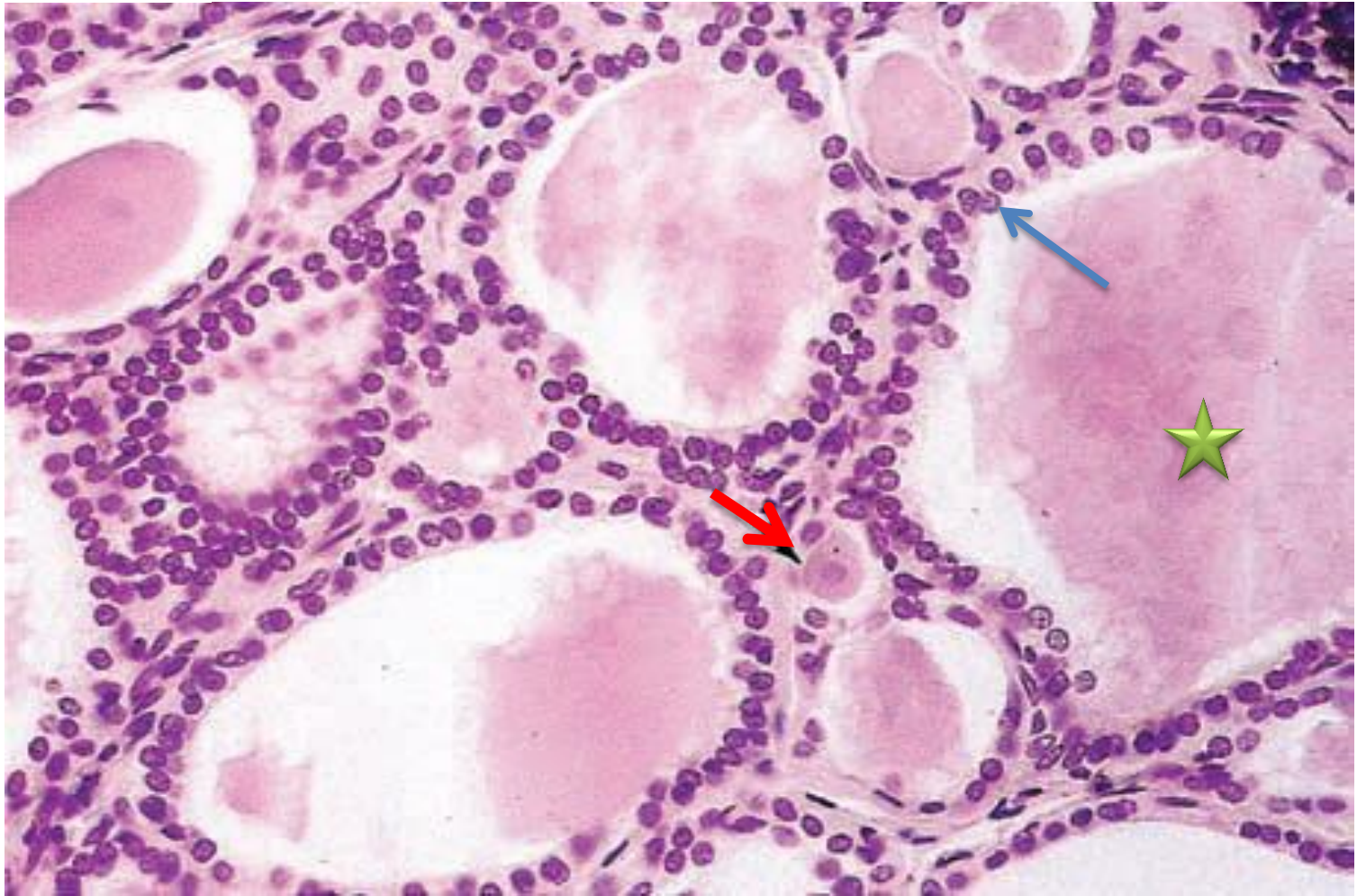


Thyroid Gland



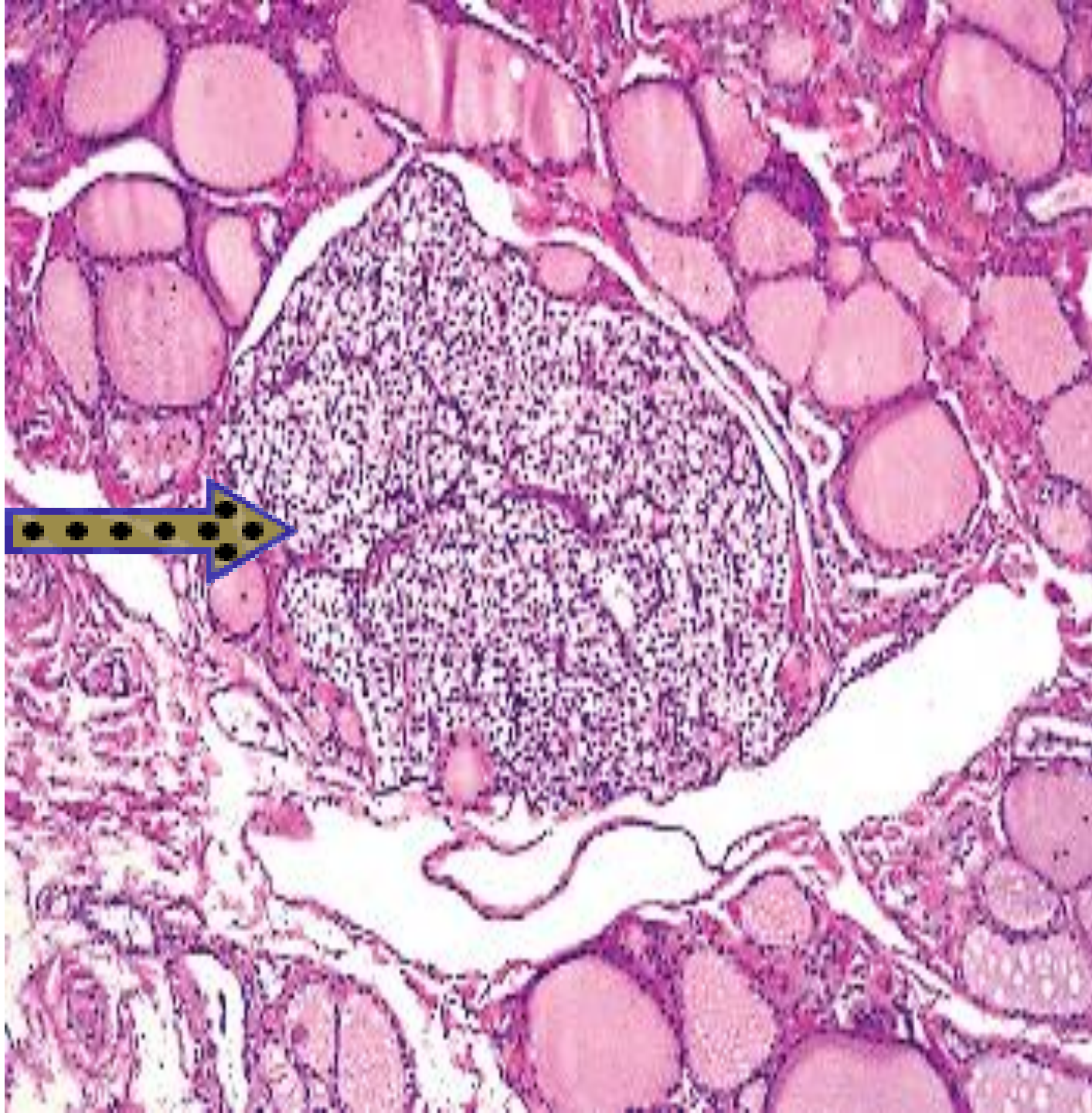



- 1. Thyroid gland**
- 2. Capsule and septa connective tissue**
- 3. Follicles with colloid containing thyroglobulin**



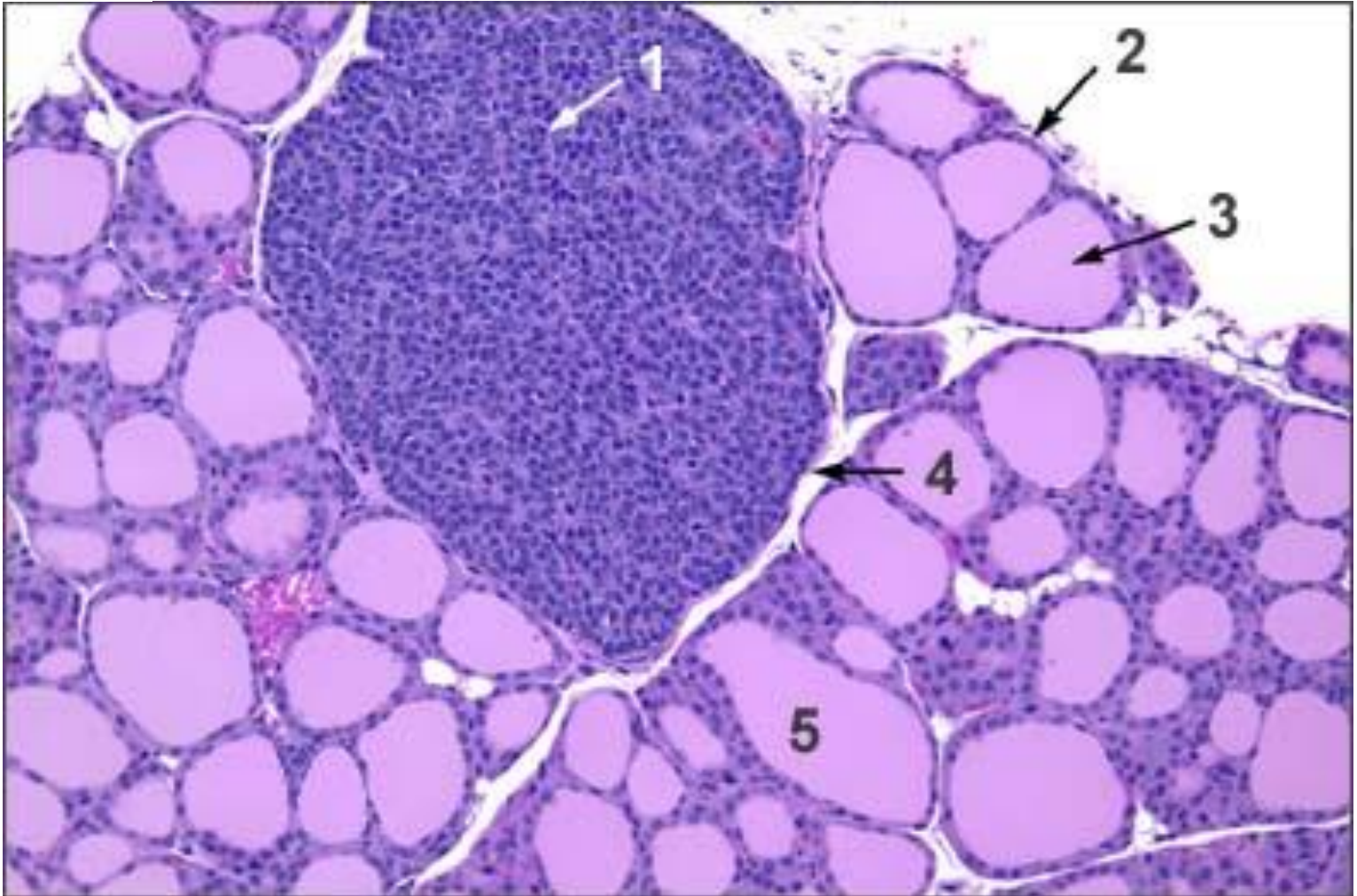


- **Parafollicular or C cells**
- **Follicular cells**
- ★ **Colloid in follicular lumen**





Parathyroid Gland

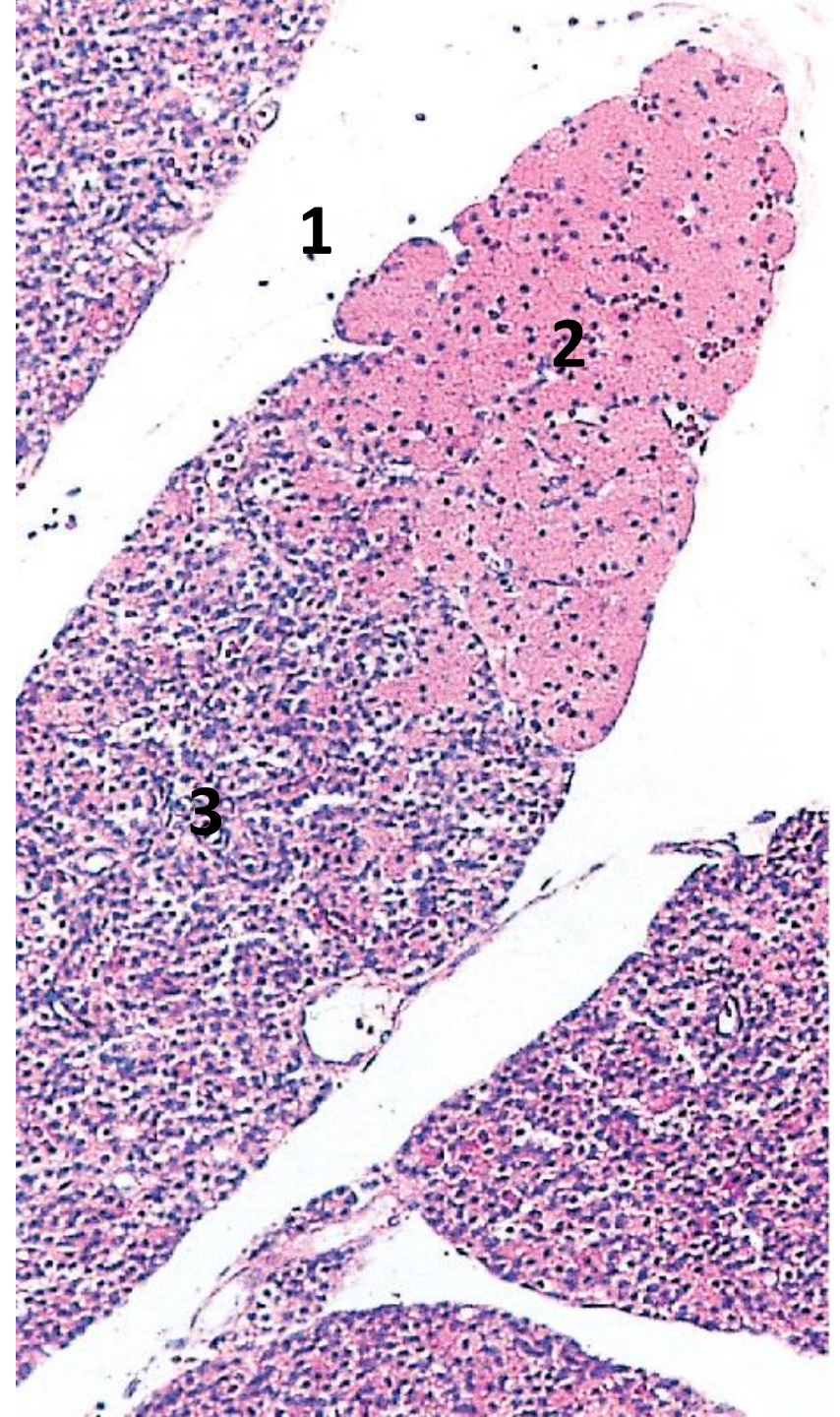




1. Parathyroid Gland

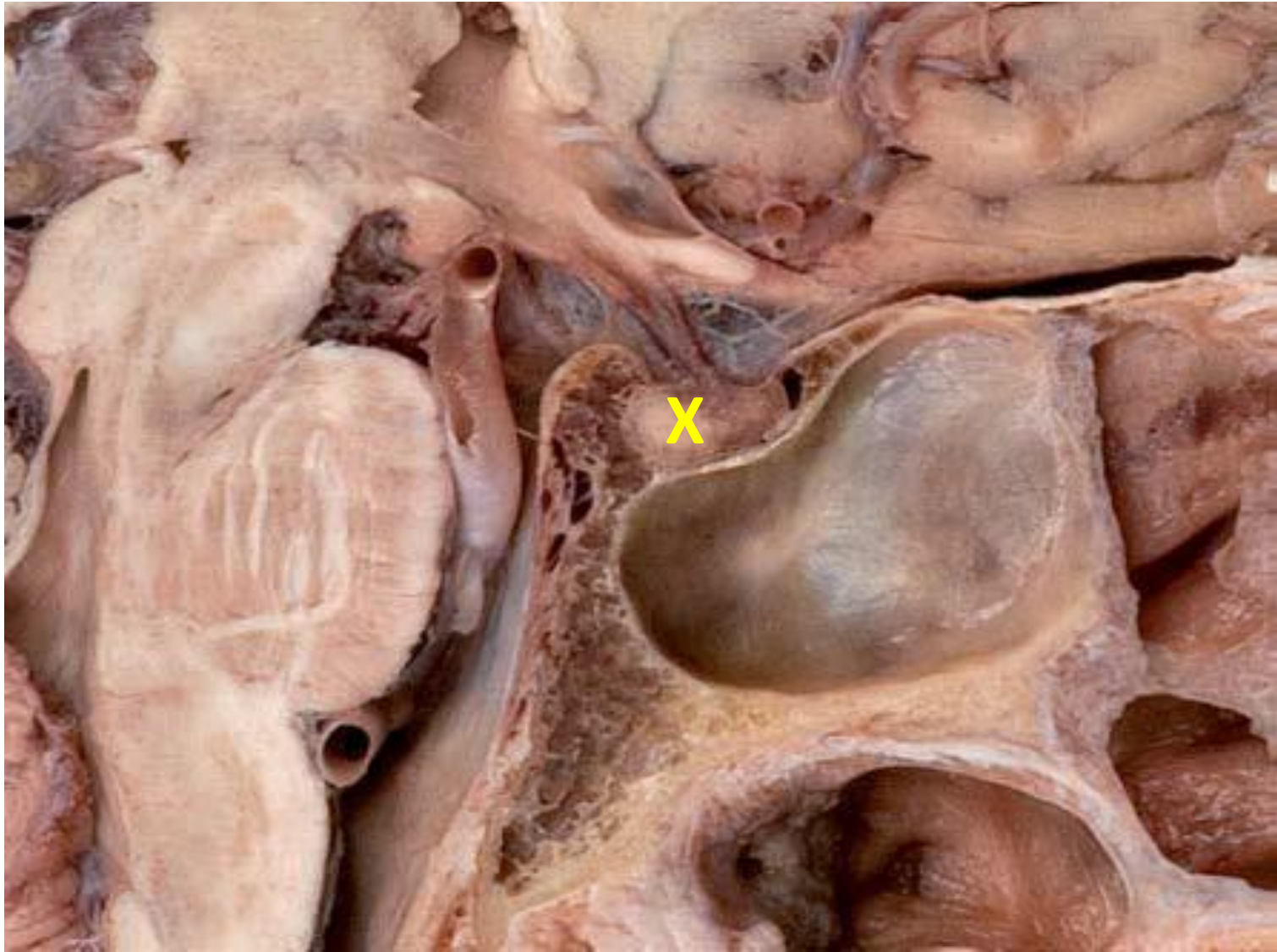

Small lobe of parathyroid gland



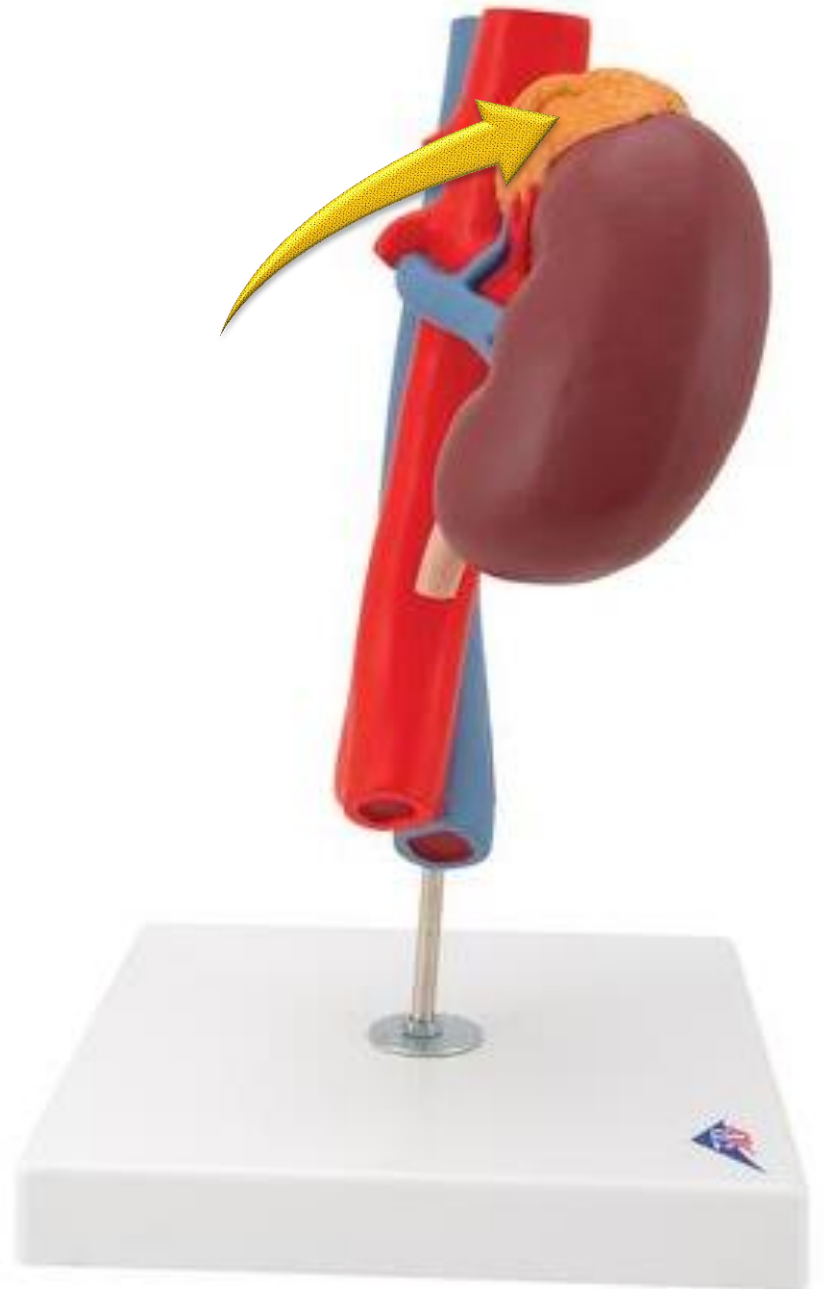

- 1. Connective tissue (Septum)**
- 2. Oxyphil cells** (very acidophilic cytoplasm)
- 3. Principal cells (chief cells)**



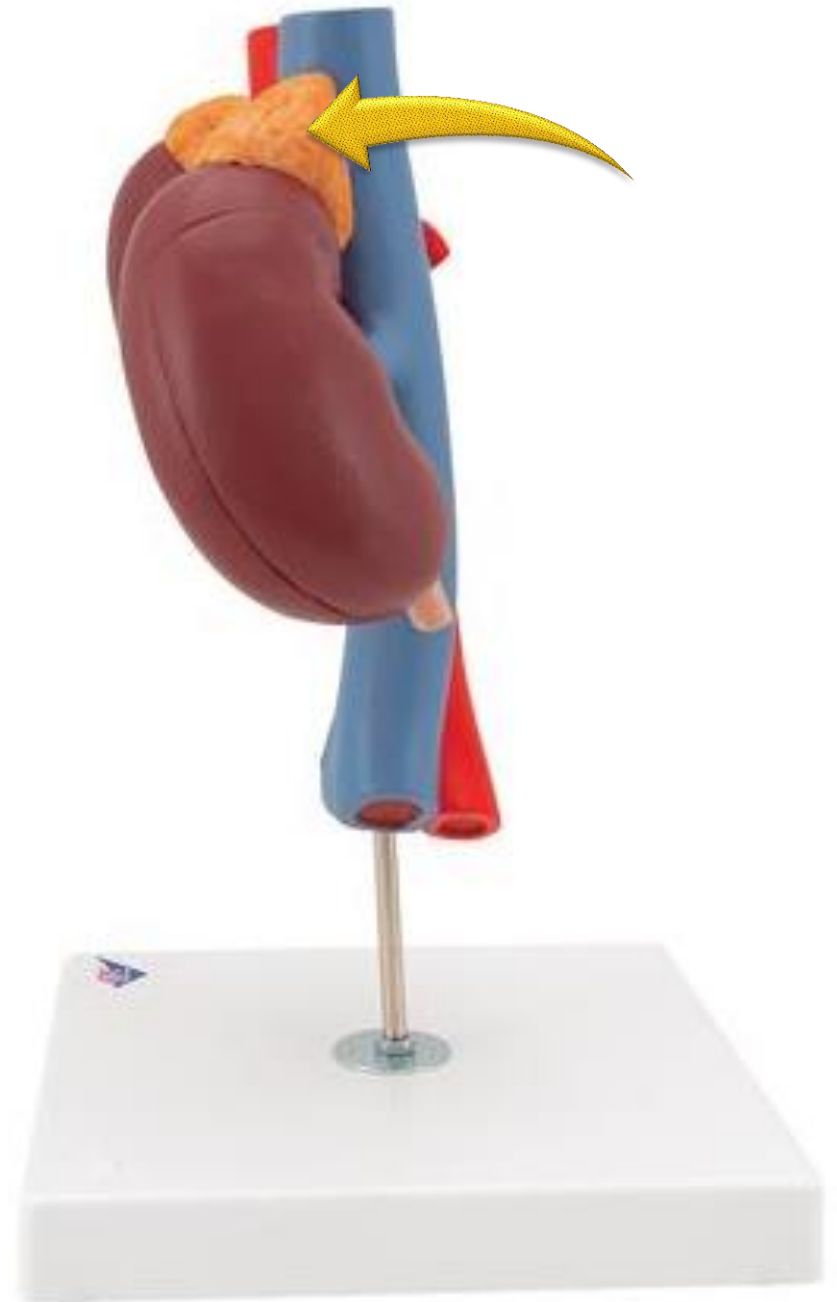

Pituitary gland



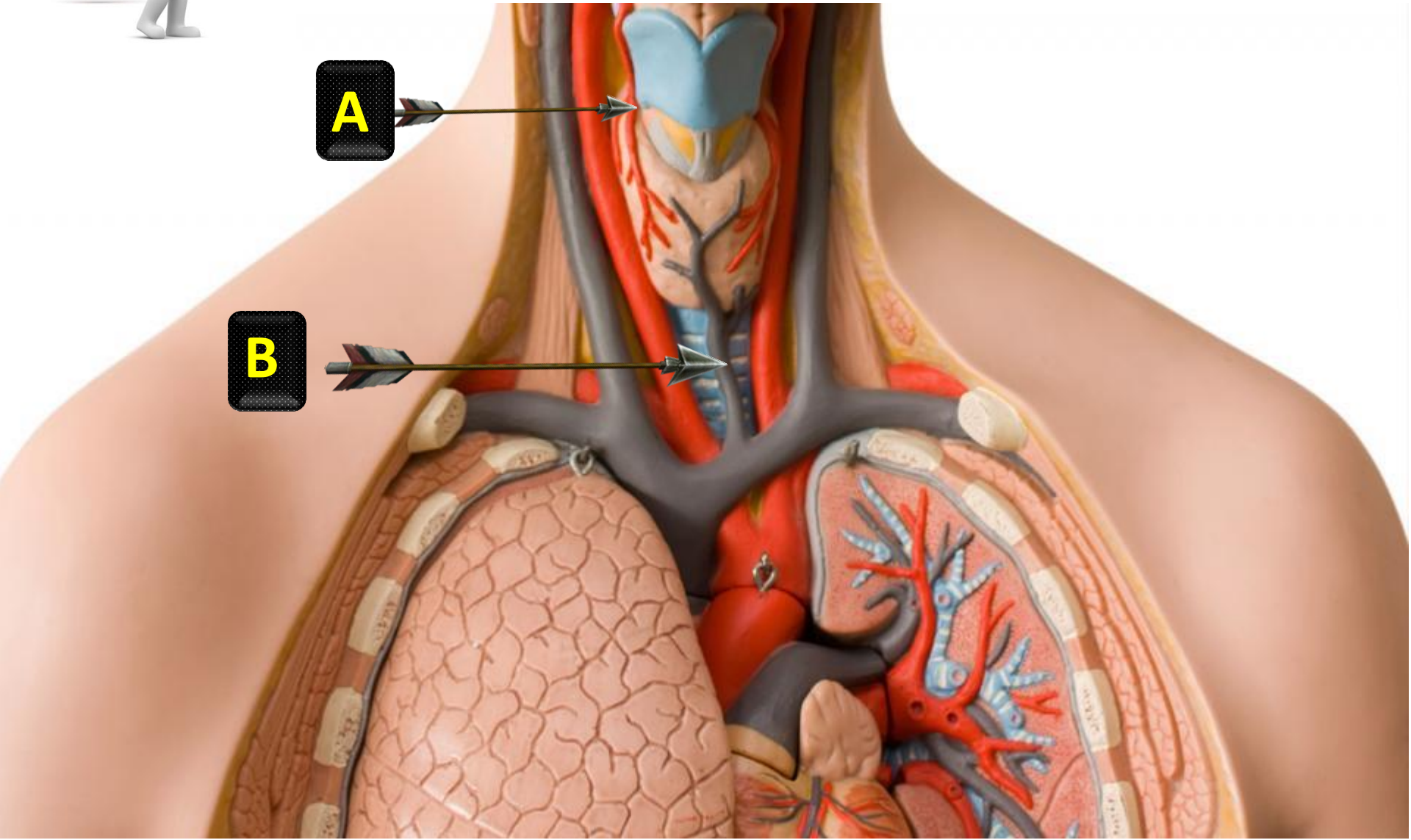


Left adrenal gland





Right adrenal gland



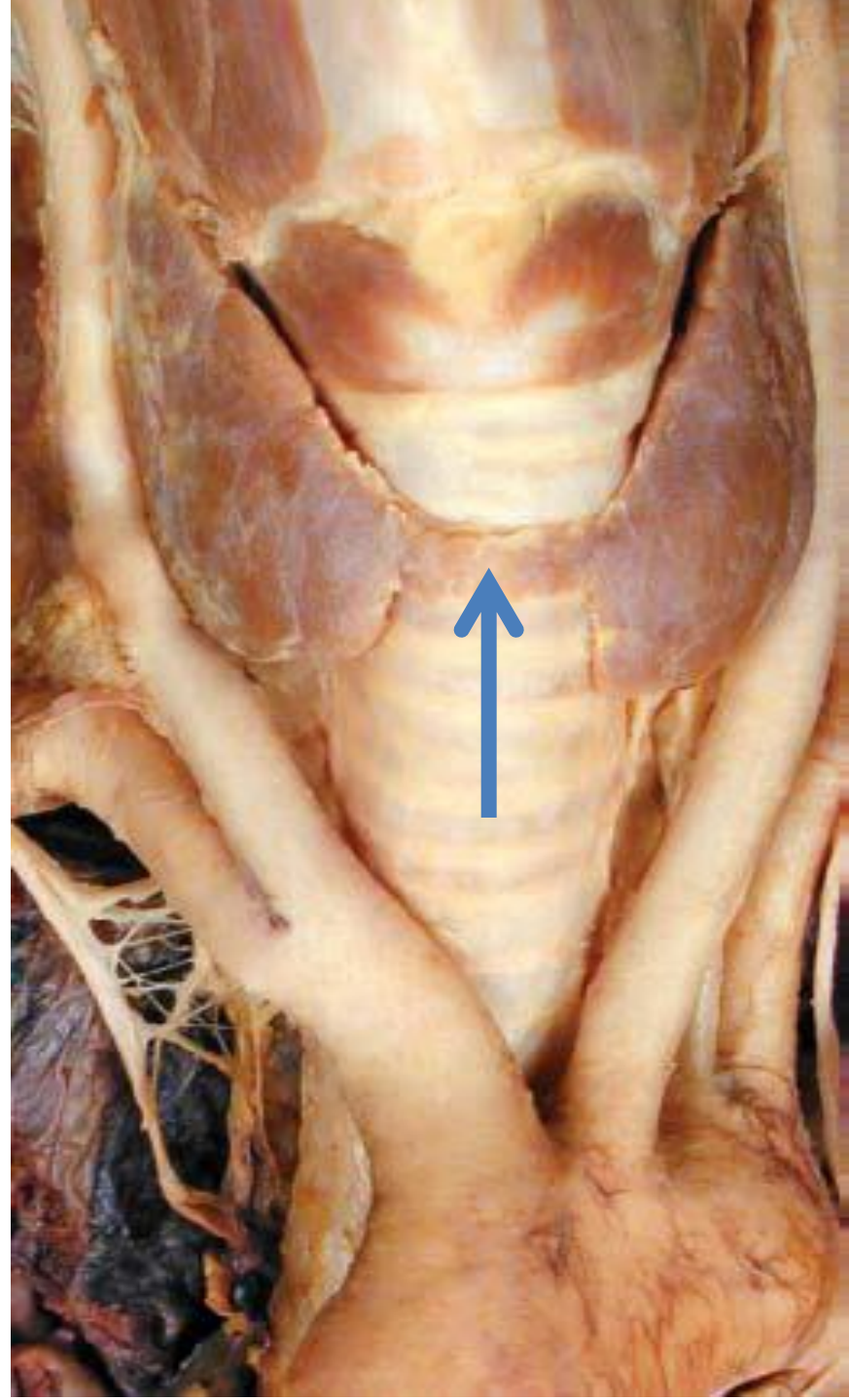
A

B



A : superior thyroid artery

B : inferior thyroid vein





Isthmus of the thyroid gland

Good luck

The image features the words "Good luck" in a bold, white, 3D sans-serif font. The text is centered horizontally and has a slight drop shadow. It is surrounded by a dense, festive shower of multi-colored confetti, including small squares and rectangular pieces in shades of red, blue, green, yellow, and orange. The background is plain white, making the colorful elements stand out.