

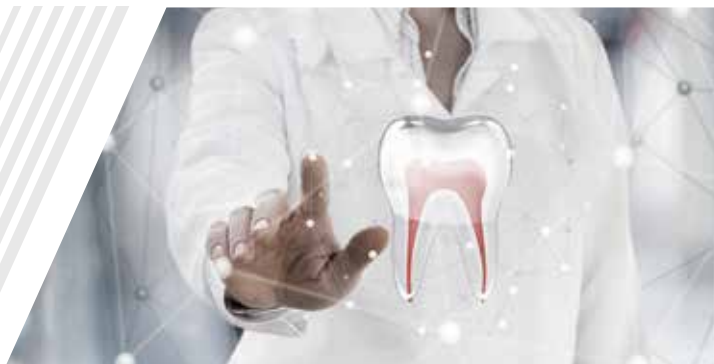

Lebanese University  
Faculty of Dental Medicine  
[www.ul.edu.lb](http://www.ul.edu.lb)

# 16<sup>th</sup> International Convention

Lebanese University - Rafic Hariri Campus - Hadath - Lebanon

MAY 2 - 4



## Excellence in Daily Practice

Lectures ♦ Workshops ♦ Live Transmissions ♦ Posters



[www.fdmcongress.ul.edu.lb](http://www.fdmcongress.ul.edu.lb)



Lebanese University - Faculty of Dental Medicine



LU Dental (Apple Store and Google Play Store)

# Contents

Message from the Dean .....	4
Message from the Scientific Committee .....	5
Board- Faculty of Dental Medicine .....	6
16 <sup>th</sup> Convention Scientific Committee .....	8
16 <sup>th</sup> Convention Organizing Committee .....	9
Scientific Program .....	10
Abstracts Day 1 - Thursday, May 2, 2019 .....	33
Abstracts Day 2 - Friday, May 3, 2019 .....	70
Abstracts Day 3 - Saturday, May 4, 2019 .....	130
Scientific Posters .....	143
List of Exhibitors .....	207

## MESSAGE FROM THE DEAN



Dear friends and colleagues,

It is a great pleasure to welcome you to the 16<sup>th</sup> International Dental Convention that is held from May 2 to 4, 2019 at the Lebanese University Campus, Hadath, Beirut-Lebanon.

Our convention is held on a biennial basis, and is attended by more than 1200 general dentists and specialists from the country and the region. It offers the opportunity to expose and share knowledge that is pertinent to all dental specialties.

This year's theme is "Excellence in Daily Practice", where an outstanding gallery of speakers from Lebanon and all over the world gather to share with us the most significant advances in our profession. Specialized seminars, workshops, live transmissions and posters are also planned to offer a platform for a better understanding and for practical solutions to problems encountered in different specialties of dental medicine.

A unique and wonderful aspect of our 2019 meeting is the collaboration with the World Federation for Laser Dentistry where a certification course pertinent to laser application in all dental fields is taking place. The meeting also offers a great opportunity to see and taste the diverse and beautiful flavors of Lebanon, the "pearl of the Middle East". I wish you a fruitful meeting and memorable stay in Beirut.

**Prof. Toni Zeinoun**

## MESSAGE FROM THE SCIENTIFIC CHAIRPERSON



Dear esteemed guests and colleagues,

On behalf of the Scientific Committee, I warmly welcome you to the 16<sup>th</sup> International Convention of the Faculty of Dental Medicine at the Lebanese University.

The Congress has been designed to provide an innovative and comprehensive overview of the latest developments in dental medicine. Renowned and distinguished speakers from Lebanon and all over the world are gathered to share their knowledge through lectures, live transmissions, workshops and hands-on in light of the theme of the meeting: "Excellence in Daily Practice".

It is our intention that this meeting provides an opportunity for the participants to not only expand their knowledge and experience, but also to interact with each other as well as with the invited speakers. This interaction is facilitated through the adoption of the Mobile Application "LU Dental" that you can download and use during the three days of the event. You can check all information related to the meeting such as schedule, speakers and posters. Once signed in, you can select the conferences and create your own calendar, vote for posters, ask questions and interact with speakers' questions, provide feedback, and receive notifications from organizers and exhibitors.

We would like to thank Rector Prof. Fouad Ayoub (Rector) and Prof. Toni Zeinoun (Dean) for their generous support, to the organizing committee headed by Dr. Mohammad Rifai for its excellent arrangements in all aspects and to our dedicated staff for their untiring help in planning and arranging this event.

We hope that you will enjoy the meeting and that your interaction with colleagues from different countries will stimulate a creative exchange of ideas and will be personally rewarding.

**Dr. Maria Saadeh**

## Board- Faculty of Dental Medicine



**Toni ZEINOUN**  
Dean and Chairperson of the Board



**Georges ABI HATEM**  
Representative of Academic Staff at the Faculty Board



**Georges AOUN**  
Chairperson, Department of Oral Medicine and Maxillofacial Radiology



**Antoine BERBERI**  
Chairperson, Department of Oral and Maxillofacial Surgery



**Edgard JABBOUR**  
Chairperson, Department of Restorative and Esthetic Dentistry and Endodontics



**Mona NAHAS GHOLMIEH**  
Chairperson, Department of Pediatric Dentistry and Dental Public Health



**Mohammad RIFAI**  
Chairperson, Department of Basic Sciences



**Loubna CHAMSEDDINE**  
Representative of Academic Staff at the Lebanese University Council



**Antoine DARAZE**  
Chairperson, Department of Orthodontics and Dentofacial Orthopedics



**Fady EL HAJJ**  
Chairperson, Department of Periodontology



**Wadih NASSIF**  
Chairperson, Department of Prosthodontics



**Maria SAADEH**  
Chairperson, Department of Forensic Odontostomatology and Human Identification



**Ziad SALAMEH**  
Director, Research Unit

## 16<sup>th</sup> Convention Scientific Committee



**Chairperson** Maria SAADEH

**Members** Georges AOUN  
Antoine BERBERI  
José Johann CHIDIAC  
Edgard JABBOUR  
Balsam EL NOUEIRI  
Joseph SABBAGH  
Ziad SALAMEH

## International Journal of Oral and Dental Sciences

**Editor-in-Chief** Hani OUNSI

**Associate Editor** Sami MOUWAKDIE

**Editorial Board** Antoine BERBERI  
Paul NAHAS  
Maria SAADEH  
Ziad SALAMEH

## 16<sup>th</sup> Convention Organizing Committee



**Chairperson** Mohammad RIFAI

**Convention's Executive Registrar** Fadia ASSAF

**Convention's Executive Secretary** Israa DAHER  
Randa FEGHALI  
Rima HAMDOUN  
Grace HAWI

**Members** Georges ABI HATEM  
Fadi ABILLAMAA  
Samia ABOU JAOUDE  
Nathalie ABOU SAMRA  
Rima ABOU TAYEH  
Georges AOUN  
Ghada ASMAR  
Roula BERBERI  
Nadwa CHATILA  
Charbel CHOUBAYAA  
Antoine CHOUFANI  
Antoine DARAZE  
Hicham DIAB  
Elie HAYEK  
Marwan HOTEIT

Fodda HOUMSI  
Houssam JASSAR  
Hassan KAZAN  
Georges KHAWAM  
Pierre EL KHOURY  
Mohamad MACHMOUCHI  
Badry MEOUCHY  
Maria MOARBES  
Sami MOUWAKDIE  
Paul NAHAS  
Wadih NASSIF  
Dolly ROUKOZ  
Jean SAADE  
Ziad SALAMEH  
Elie SMAYRA

Saydé SOKHN  
Sami EL TOUM  
Zoubayda YAHFOUFI  
Salwa YAMMINE  
Mona ZEITOUNI

# Program

Thursday, May 2, 2019

## Conference Hall A

Moderators: E. Jabbour / E. Ossman / R. Rebeiz

09:00-09:45 Shaping Canals Using WaveOne Gold® in Reciprocation. **F12**  
**Wilhelm Pertot**

09:45-10:30 Worn Dentition in the Everyday Practice: the Full Mock Up Concept. **F13**  
**Stefen Koubi**

**11:30-12:30 OPENING CEREMONY | EXHIBIT INAUGURATION**

12:30-13:15 Operative Dentistry: What a Wonderful World - Part I. **F14**  
**Francesco Mangani**

**13:15-14:00 Lunch Break**

Moderators: R. Dib Khalaf / J. Makhzoumé / T. Zeinoun

14:00-14:45 Zirconia Crowns in Pediatric Dentistry: Can They Replace Proven Techniques? **F15**  
**Nabil Ouatik**

14:45-15:30 Lasers-Assisted Periodontal Treatments and Periimplantitis. **F16**  
**Samir Nammour**

15:30-16:15 The Evolution of the Bubble: New Frontiers for Laser Activated Irrigation. **F17**  
**Roeland De Moor**

**16:15-16:45 Coffee Break & Exhibit Visit**

Moderators: H. Aljajah / P. Nahas

16:45-17:30 Biophotonics and the Dental Sciences. Clinical Application of Laser Therapy Based on Translational Preclinical Dental Research. **F18**  
**Aldo Brugnera**

17:30-18:15 Pre-Emptive Dental Anaesthesia by Nd:YAG Photobiomodulation- Part I. **F19**  
**Ambrose Chan**

# Program

Thursday, May 2, 2019

## Conference Hall B

Moderators: A. Darazé / J. Ghoubril

09:00-10:15 **WORKSHOP**  
Why Do Miniscrews Change the Rules of the Game in Daily Clinical Practice. **F20**  
Part I.  
**Cesare Luzi**

**10:15-10:30 Coffee Break & Exhibit Visit**

10:30-11:30 **WORKSHOP**  
Why Do Miniscrews Change the Rules of the Game in Daily Clinical Practice. **F21**  
Part II.  
**Cesare Luzi**

**11:30-12:30 OPENING CEREMONY | EXHIBIT INAUGURATION**

**12:30-14:00 Lunch Break**

# Program

Thursday, May 2, 2019

## Conference Hall B

Moderators: R. Haddad / F. Nabbout

14:00-14:45 New Trends in Self-Ligation with Dual Activation Mechanics. **F22**  
Cesare Luzi

14:45-15:05 Physical, Clinical and Cephalometric Assessment of Upper Airways: A New Paradigm in Orthodontics. **F23**  
Antoine Darazé

15:05-15:25 New Cephalometric Landmarks Identification in Rapid Maxillary Expansion. **F24**  
Mona Sayegh Ghoussoub

15:25-15:45 Involvement of Speech Therapists in Orthodontic Treatment in Lebanon. **F25**  
Maria Haydar

15:45-16:00 **Coffee Break & Exhibit Visit**

Moderators: M. Moarbes / F. Touma

16:00-16:30 Diagnostic Considerations in Soft Tissue Calcifications. **F26**  
Ibrahim Nasseh

16:30-16:50 A Radiologic Approach to Evaluate Radiopacities Jaw Lesion for Simplified Differential Diagnosis. **F27**  
Elie Hayek

16:50-17:20 **Coffee Break & Exhibit Visit**

17:20-17:50 Radiopacities from Incidental Findings to Real Pathologies. **F28**  
Alexandre Khairallah

17:50-18:10 A Radiological Based Diagnostic Algorithm for Detecting Pathologies Associated with Radiopaque Components. **F29**  
Sara Moussa

# Program

Thursday, May 2, 2019

## Conference Hall C

Moderators: J-C Abou Chedid / S. Bader / M. Nahas Gholmieh

09:00-09:45 SMART, SDF, Hall: Why Do We See a Trend Towards Biological Approaches in Pediatric Dentistry? **F40**  
Nabil Ouatik

09:45-10:05 Fiberglass Crowns in Pediatric Dentistry: Overview and Updates. **F31**  
Bourane Ambriss

10:05-10:25 Early Diagnosis and Surgical Management of a Complex Odontoma. A Clinical Case. **F32**  
Hoda Al Moussawi

10:25-10:55 L'Utilisation des Probiotiques en Odontologie Pédiatrique. **F43**  
Marlène Khoury Freiha | Krikor Sahakian

10:55-11:25 An Interactive Approach to Pediatric Dentistry Cases. **F44**  
Riad Bacho

11:30-12:30 **OPENING CEREMONY | EXHIBIT INAUGURATION**

12:30-14:00 **Lunch Break**

# Program

Thursday, May 2, 2019

## Conference Hall C

Moderators: E. Gerges / L. Segaan

14:00-14:45 Impressions for Tooth Supported and Implant Supported Restorations: Materials and Techniques. **F36**  
Stefano Gracis

14:45- 15:15 Retention and Wear of Locator® Attachments in Implantology. **F37**  
Georges Tehini

15:15-15:45 Digitally Driven Prosthetic Restorations. **F38**  
Mohammad Rayyan

15:45- 16:05 Micro-CT Technology for the Evaluation of Novel CAD-CAM Pre-Sintered Co-Cr. **F39**  
Elie Daou

16:05-16:20 Coffee Break & Exhibit Visit

Moderators: P. Habre Hallage / Z. Salameh

16:20-17:05 New Opportunities for your Dental Practice with Intraoral Scanning, Digital Implant Planning and Surgical Guides. **F49**  
Jan Paulics

17:05-17:35 Immediate vs. Conventional Loading in the Posterior Maxilla. **F50**  
Habib Abi Aad

17:35-18:05 Peut-on Éviter de Prendre une Empreinte en Prothèse Hybride Supra Implantaire? **F51**  
Jihad Fakhouri

18:05-18:25 Factors Affecting the Accuracy of All-Ceramic Restorations Related to Digitalization and Manufacturing Procedures. **F52**  
Foudda Homsy

# Program

Thursday, May 2, 2019

## Conference Hall D

11:30-12:30 OPENING CEREMONY | EXHIBIT INAUGURATION

12:30-14:00 Lunch Break

Moderators: N. Barakat / C. Khoury

14:00-14:45 The Collagenous Matrix in Bone Augmentation. **F53**  
Georges Khoury

14:45-15:15 The Cortico-Cancellous Soft Tissue Punch: A Novel Procedure for Alveolar Ridge Preservation. **F54**  
Nabih Nader

15:15-15:45 Future Directions in Bone Reconstruction of the Upper Maxilla. **F55**  
Ronald Younes

15:45-16:00 Discussion

16:00-16:15 Coffee Break & Exhibit Visit

16:15-17:00 Brilliant and Sustainable Pink Aesthetics through Immediate and Minimally Invasive Shaping of the Peri-implant Soft Tissue. **F56**  
Paul Weigl

17:05-17:35 Jaw Cysts and Tumors Management at Lebanese University: from Presumptive Diagnosis to Final Treatment. **F57**  
Ziad Noujeim



## Program

---

Thursday, May 2, 2019

### Workshop - Endodontics - Workshop Hall 1

Moderators: S. Yammine

14:00-17:00 The Latest Reciprocating WaveOne Gold® Files for Shaping Canals. **F59**  
Wilhelm Pertot

### Workshop - Pediatric Dentistry - Workshop Hall 2

Moderators: B. El Noueiri

15:00-18:00 Kiddy Caps: New and Improved Zirconia Crowns. **F58**  
Georges Abi Hatem | Samia Abou Jaoudé | Mohammad Hassan Bacho  
Micheline Katramiz | Hitaf Nasseh | Rola Zein

## Program

---

Friday, May 3, 2019

### Conference Hall A

Moderators: C. Abi Ghosn Yared / J. Ghafari

09:00-09:45 Current Approaches in the Interdisciplinary Treatment Planning of Prosthetic  
and Orthodontic Patients. **F60**  
David De Franco / Stefano Gracis

09:45-10:30 Advanced Features of the Intra-Oral Scanner Allowing the Dentist to Excel  
in Accuracy and Aesthetics. **F61**  
Jan Paulics

10:30-11:00 **Coffee Break & Exhibit Visit**

Moderators: G. Aoun / E. Nehmé

11:00-11:45 Medication Related Osteonecrosis of the Jaw: Prevalence, Risk Factors,  
Clinical and Radiographic Characteristics. **F17**  
Umberto Romeo

11:45-12:30 New Infections and Infection Control in Dentistry: Current Perspectives. **F63**  
Lakshman Samaranayake

12:30-13:15 Oral Cancer. **F139**  
Shankargouda Patil

13:15-14:15 **Lunch Break**

## Program

---

Friday, May 3, 2019

### Conference Hall A

Moderators: A. Berberi / A. Khoury

14:15-15:00 The Socket Chamber Concept: Clinical Outcomes of Immediate Implant Placement and Restoration. **F64**  
Paul Weigl

15:00-15:45 Bone Regeneration: Where Are We? **F65**  
Georges Khoury

15:45-16:15 **Coffee Break & Exhibit Visit**

Moderators: J. Chidiac / N. Rizk

16:15-17:00 The Use of Botox in Bruxism. **F66**  
Giovanni Mauro

17:00-17:45 From Toothache to Orofacial Pain – What Did We (Have to) Learn? **F67**  
Antoon De Laat

## Program

---

Friday, May 3, 2019

### Conference Hall B

Moderators: A. Darazé / M. Hoteit

10:00-10:20 Skeletal Age Assessment on CBCT. **F68**  
Antoine Saadé

10:20-10:40 Update on Different Orthodontic Treatment Modalities in Adult Patients. **F69**  
Anthony Macari

10:40-11:00 Pushing the Envelope of Tooth Movement with Microimplant Anchorage. **F70**  
Bilal Koleilat

11:00-11:30 **Coffee Break & Exhibit Visit**

Moderators: J. Ghafari / M. Ghossoub

11:30-11:50 The Orthodontic-Periodontal Interface **F71**  
Ramzi Haddad

11:50-12:10 Class II Correction with Microimplant-Supported Molar Distalization. **F72**  
Fidèle Nabbout

12:10-12:55 Clinical Management of Impacted Canines. **F73**  
David De Franco

12:55-13:15 Discussion

13:15-14:15 **Lunch Break**

# Program

Friday, May 3, 2019

## Conference Hall B

Moderators: S. El Toum / G. Yared

- 14:15-15:00 Oral Microbiome and Systemic Health: Unraveling Fact from Fiction. **F74**  
**Lakshman Samaranayake**
- 15:00-15:20 Alerting Signs Facing an Oral Ulceration. **F76**  
**Carlo Maksoud**
- 15:20-15:40 Alerting Signs Facing a Red and White lesion. **F77**  
**Nadwa Chatila**
- 15:40-16:00 **Coffee Break & Exhibit Visit**
- 16:00-16:45 Oral Potentially Malignant Disorders. **F79**  
**Shankargouda Patil**
- 16:45-17:05 Alerting Signs Facing a White Lesion. **F80**  
**Dolly Roukoz**

# Program

Friday, May 3, 2019

## Conference Hall C

Moderators: C. Khairallah / J. Sabbagh

- 09:00-09:45 From Dogma to Everyday Dentistry in the Aesthetic Zone: Ingredients and Recipes: From No Prep to Prep Less. **F81**  
**Stefen Koubi**
- 09:45-10:15 How to Rebuild a Functional Posterior Restoration. **F82**  
**Jean-Claude Fahd**
- 10:15-10:45 Does Digital Technology Improve Today's Clinical Practice in Smile Makeover Cases? **F83**  
**Hala Ragab**
- 10:45-11:15 **Coffee Break & Exhibit Visit**
- Moderators: J-C. Fahd / H. Ragab
- 11:15-11:45 Simplified Techniques and Materials to Overcome our Daily Challenge in Direct Composite Restorations. **F84**  
**Louis Hardan**
- 11:45-12:15 Five Most Common Errors in Posterior Composites. **F86**  
**Joseph Sabbagh**
- 12:15-13:00 Operative Dentistry: What a Wonderful World- Part II. **F87**  
**Francesco Mangani**
- 13:00-14:00 **Lunch Break**

## Program

---

Friday, May 3, 2019

### Conference Hall C

Moderators: R. Abiad / H. Ounsi

14:00-14:45 Contemporary Endodontics: Current Strategies and Perspectives. **F88**  
Frédéric Bukiet

14:45-15:15 New trends in Root Canal Obturation in the Era of Minimal Invasive Endodontics. **F89**  
Carla Zogheib

15:15-15:45 Controversies in Minimally Invasive Endodontics. **F90**  
Edmond Koyess

15:45-16:15 Coffee Break & Exhibit Visit

Moderators: E. Jabbour / C. Zogheib

16:15-17:00 Cone Beam CT in Endodontics. **F91**  
Shanon Patel

17:00-17:30 Single-Instrument Endodontics? Really? **F92**  
Hani Ounsi

## Program

---

Friday, May 3, 2019

### Conference Hall D

Moderators: F. El Hajj / G. Tawil

09:00-09:45 Toward Precision Periodontal Therapy: Host Genome, Epigenome and Oral Microbiome Interactions. **F93**  
Sleiman Razzouk

09:45-10:15 Periodontal and Peri-Implant Diseases and Conditions: Where Do We Stand in 2019? **F94**  
Fatmé Mouchref Hamasni

10:15-10:45 Bone Augmentation from Simple to Complicated. **F95**  
Johnny Nohra

10:45-11:15 Coffee Break & Exhibit Visit

Moderators: F. Hamasni / J-M Megarbané

11:15-11:45 Hard Tissue Grafting Techniques for Esthetic implant: When to Do What? **F96**  
Alain Romanos

11:45-12:15 3D Reconstruction of Horizontal Ridge Deficiency: Techniques and Approaches. **F97**  
Elie Azar EL Maalouf

12:15-13:00 Vertical and Main Horizontal Ridge Augmentation: Which Biomaterials in 2019? **F98**  
Bilal Omarjee

13:00-14:00 Lunch Break

## Program

Friday, May 3, 2019

### Conference Hall D

Moderators: H. Diab / P. Souaid

- 14:00-14:45 Restorative Challenges in Older Patients. **F99**  
Hien Ngo
- 14:45-15:05 Fundamental Elements Needed to Prevent Infectious Agents in Dental Settings. **F100**  
Jihad Dagher
- 15:05-15:25 Prévention des Troubles Musculo-Squelettiques chez les Dentistes. **F101**  
Antoine Choufani
- 15:25-15:55 **Coffee Break & Exhibit Visit** **F102**
- 15:55-16:15 School-Based Dental Sealant Program. **F103**  
Dany Daou
- 16:15-16:35 The Upstream-Downstream Concept in Oral Health. **F103**  
Mohamad Machmouchi
- 16:35-16:55 Silver Diamine Fluoride: a New Public Health Measure in Preventing Dental Caries. **F104**  
Sawsan Nasreddine

## Program

Friday, May 3, 2019

### CEDARS Hall

Moderators: K. Corbani / S. Nammour

- 09:00-09:15 A Tribute to Kenji Yoshida. **F138**  
Ambrose Chan
- 09:15-10:00 Pre-Emptive Dental Anaesthesia by Nd:YAG Photobiomodulation- Part II. **F107**  
Ambrose Chan
- 10:00-10:45 Lasers in Endodontics for Root Canal Cleaning and Disinfection- a Critical Appraisal. **F62**  
Roeland De Moor
- 10:45-11:30 Er:YAG Laser: Innovation in Clinical Use Based Upon Scientific Evidence. Clinical Cases. **F114**  
Aldo Brugnera
- 11:30-11:45 **Coffee Break & Exhibit Visit**
- Moderators: A. Brugnera / O. Hamade
- 11:45-12:30 Use of Laser in Dental Prosthetic Surgery. **F108**  
Samir Nammour
- 12:30-13:15 Live transmission: Surgery with Laser. **F119**  
Samir Nammour
- 13:15-14:15 **Lunch Break**

# Program

---

Friday, May 3, 2019

## **CEDARS Hall**

Moderators: A. Chan / P. Nahas

14:15-14:45 Treatment of Peri-Implantitis Using Lasers: Current Clinical Approach. **F109**  
Jamil Shibli

14:45-15:30 Laser in the Treatment of Soft Tissue Diseases of the Oral Cavity: Advantages and Limits. **F106**  
Umberto Romeo

15:30-16:00 Integrating Laser Technology into Esthetic Dentistry: from Myths to Clinical Reality. **F112**  
Karim Corbani

16:00-16:30 **Coffee Break & Exhibit Visit**

Moderators: M. Hoteit / U. Romeo

16:30-17:00 Dental Bleaching Using Violet Light: The Great Leap as New Perspective for Aesthetic Dentistry. **F111**  
Fatima Zanin

17:00-17:30 Success of Bonding Composite to Laser-Treated Dentin. **F113**  
Paul Nahas

17:30-18:00 Effect of Different Er:YAG Etching Settings on Shear Bond Strength of Orthodontic Ceramic Brackets. **F110**  
Marwan Hoteit

# Program

---

Friday, May 3, 2019

## **Chartouni Hall**

### **Workshop - Oral and Maxillofacial Radiology**

Moderators: I. Nasseh

10:00-13:00 How Does CBCT Work and Image Quality in CBCT. **F120**  
Marc Semper

### **Workshop Hall 1**

#### **Workshop - Prosthodontics**

Moderators: A. Assaf

11:00-13:30 Implant Retained Digital Dentistry. **F121**  
Jan Paulics

### **Workshop Hall 2**

#### **Workshop - Periodontology**

Moderators: E. Azar El Maalouf

15:00-18:00 Vertical and Main Horizontal Ridge Augmentation. **F122**  
Bilal Omarjee

## Program

---

Friday, May 3, 2019

**Phoenixia Hall**

**Live Transmission - Endodontics**

Moderator: E. Rizk

09:00-11:00 Endodontic Microsurgery: The Final Conquest.  
Edgard Jabbour / Edmond Koyess

**F115**

**Phoenixia Hall**

**Live Transmission - Implantology**

Moderator: G. Tehini

14:00-16:00 Full Arch Guided Surgery with Immediate Temporary Restoration  
Hani Tohmé / Wadih Nassif / André Assaf

**F118**

## Program

---

Saturday, May 4, 2019

**Conference Hall A**

Moderators: E. Koyess / I. Nasseh

09:00-09:45 External Cervical Resorption- Diagnosis and Treatment.  
Shanon Patel

**F123**

09:45-10:30 Calcium Silicate-Based Root Canal Sealers for Obturation of the Root Canal  
Space: A Recent Approach Raising New Questions.  
Frédéric Bukiet

**F124**

10:30-11:15 The Influence of Cone Beam Computed Tomography in Clinical Decision  
Making.  
Marc Semper

**F137**

11:15-11:30 **Coffee Break & Exhibit Visit**

Moderators: B. Doughan / M. Doumit

11:30-12:15 Clinical Management of Dental Caries.  
Hien Ngo

**F125**

12:15-13:00 Designing a New Workflow for Clinic Health Management.  
Patrizio Bortolus

**F126**

13:00-13:30 **CLOSING CEREMONY**

## Program

---

Saturday, May 4, 2019

### Conference Hall B

Moderator: G. Abi Khalil

10:30-11:00 3D Virtual Surgical Planning in Maxillofacial Surgery.  
Naji Abou Chebel

**F127**

11:00-11:30 Maxillofacial Trauma.  
Wahid Terro

**F128**

11:30-12:00 Management and Surgical Repair of Condylar Fracture.  
Georges Abi Khalil

**F129**

12:00-12:30 Facial Complex Trauma.  
Said Halabi

**F130**

13:00-13:30 CLOSING CEREMONY | POSTER AWARDS ANNOUNCEMENT

## Program

---

Saturday, May 4, 2019

### Conference Hall C

Moderators: J. Hobeiche / K. Rifai

10:30-11:00 Chronic Pain Management: Where Is the Difficulty?  
José Johann Chidiac

**F132**

11:00-11:45 Typical and Atypical Facial Pain.  
Antoon De Laat

**F133**

11:45-12:30 Risks and Pitfalls When Using Botox for Pain Patients.  
Giovanni Mauro

**F134**

13:00-13:30 CLOSING CEREMONY | POSTER AWARDS ANNOUNCEMENT



# Program

Saturday, May 4, 2019

Phoenicia Hall

Live Transmission - Oral Surgery

Moderator: R. Abou Tayeh

09:30-12:30 Live transmission:  
Soft Tissue Management around Implants.  
Carlos Khoury / Roger Bassit

13:00-13:30 CLOSING CEREMONY | POSTER AWARDS ANNOUNCEMENT

## Wilhelm-J. Pertot

DCD, MSc, DEA, PhD

Lecturer, Rey Juan Carlos University

France



### Shaping Canals Using WaveOne Gold® in Reciprocation

Hall A 09:00-09:45

F136

Even though the objectives of endodontics have remained unchanged for the past half century, the evolution in techniques and technology in the last 15 years have made endodontic treatments more reliable and predictable.

Amongst these evolutions, the introduction of nickel-titanium instruments in 1995 has revolutionized the shaping procedure. Most of the instruments on the market feature a constant taper and are used in a continuous rotation motion.

In 2000, ProTaper®, the first instrument designed with a variable taper, was introduced, and was improved in 2004 and called ProTaper Universal®. In 2008, a first article described reciprocation with unequal angles and using Finishing File F2 from the ProTaper® system to shape root canals. Three years later, the WaveOne® and Reciproc® concepts were launched on the market. This unique movement allowed to create a new concept of «single file shaping technique» and proved to be able to shape canals using one file in more than 80% of the cases. This concept introduced simplicity and safety in root canal preparation for general practitioners.

WaveOne Gold® is the latest iteration of WaveOne®, launched in 2015, after 3 years of further research and development. WaveOne Gold® maintains the philosophy of a specifically designed SINGLE Nickel Titanium instrument to shape canals utilizing a reciprocating motion after prior glide path enlargement. WaveOne Gold® exhibits advanced heat-treated nickel-titanium alloy, with a newly designed parallelogram cross-section. The system features four optimized tip diameters to cover a broader range of canal morphologies, reduced tapers to fulfill the requirements of minimally invasive endodontics and offering better flexibility and more resistance to cyclic fatigue.

The new WaveOne Gold® improves safety and efficiency when shaping canals, allowing 3D disinfection and obturation.

In the majority of cases, only a single WaveOne Gold® Primary file is needed thus reducing the number of instruments in any given sequence to an absolute minimum. The influence of the reciprocation motion and of the single file shaping techniques on cyclic fatigue of instruments, on root canal transportation, debris extrusion, dentinal cracks, and cleanliness of the root canal system will be discussed. A link will be done between the scientific studies and their impact on the clinical root canal procedure, with a discussion of clinical tips through different clinical cases and videos.

## Stefen Koubi

DDS, DEA, PhD

Associate Professor, School of Dentistry,  
Marseille University

France



### Worn Dentition in the Everyday Practice: The Full Mock Up Concept

Hall A 09:45-10:30

In the last fifteen years, partial bonded restorations have become the most esthetic, biologic and biomechanical solution for restoring dental defects and imitating the natural dentition. In parallel, materials, techniques and concepts have also evolved to offer a contemporary treatment to our patients. Dental manufacturers offer good products that should be used following a meticulous methodology in order to propose solutions to the restorative dentist.

The aim of this presentation is to suggest a simple way of working and thinking that can be summarized in 3 key words: simple, teachable and repeatable. Laminate veneer will be presented as a versatile tool to solve both cosmetic and functional problems in worn dentitions. In both instances, we follow the same philosophy (minimal invasive approaches), bonded materials (CAD/CAM material, press material), concept (visualization, validation, navigation through the mock up) and clinical procedure (prep design, temporization, and cementation). In addition, the latest material development and their selection according to esthetic, functional and financial requirement will be explained.

Thursday - May 2

## Francesco Mangani

MD, DDS

Professor, Department of Restorative and Esthetic  
Dentistry, Tor Vergata University, Rome

Italy



### Operative Dentistry: What a Wonderful World - Part I

Hall A 12:30-13:15

Operative Dentistry has tremendously evolved in the last 38 years. Nowadays the request for tooth colored restorations and the maintenance of “a nice smiling” represents the main desire of our patients.

Predictable and repeatable results can be achieved through materials and clinical practices that, on one hand, preserve the original structure of the compromised tooth and, on the other hand, involve a very low biologic price. New technologies for dentino-enamel adhesion and the continuous evolution of more sophisticated esthetic materials such as composite and porcelain allow to reach effective and predictable results.

Very often, in congresses, courses on social media such as Facebook, that should be correctly called Facetooth, we assist to something more similar to “a dental show” than to “dental medicine”! People seem to be more concentrated on the quality of the images, the definition of the movies, showing “seductive minimally invasive” clinical cases that do not respect the fundamentals of Operative Dentistry and many times hide a lot of mistakes behind the word “ADHESION”. This lecture points out the relevant guidelines for both direct and indirect esthetic restorations through the evaluation of techniques and materials in order to reach correct, standardized and long-lasting evidence-based clinical results while respecting the principles of biomechanics.

Thursday - May 2

## Nabil Ouatik

DMD, MSc, FRCD(C)

Clinical Lecturer, McGill University

Canada



### Zirconia Crowns in Pediatric Dentistry: Can They Replace Proven Techniques?

Hall A 14:00-14:45

During the last ten years, improvements in ceramic manufacturing techniques have allowed the introduction of serially produced prefabricated zirconia crowns (PZC) specifically for the restoration of anterior and posterior primary teeth. These full zirconia crowns are increasingly popular, because of their esthetic edge. The higher cost per unit and the more elaborate operative technique to execute this treatment are noted. Nevertheless, trained providers are reportedly able to execute this treatment at a speed that is equivalent to existing treatments such as composite strip crowns and stainless steel crowns. Like all emerging techniques, it is found that this type of treatment does not have a very long clinical track record compared to proven techniques and that it only has been the topic of a few scientific publications.

Thursday - May 2

## Samir Nammour

DDS, MSc, PhD, Agr.

Professor, Department of Dental Sciences, Faculty of Medicine, University of Liege  
General Director, European Master: "Oral Laser Applications" (EMDOLA)  
Chairman, International relations and legal affairs, World Federation for Laser Dentistry (WFLD)

Belgium



### Lasers-Assisted Periodontal Treatments and Periimplantitis

Hall A 14:45-15:30

In addition to conventional treatment modalities (mechanical and chemical), the use of different lasers has been increasingly proposed for the treatment of periodontal and peri-implant infections. Preliminary results from both basic studies and controlled clinical trials have pointed to a high potential of Diode and Er:YAG lasers. Irradiation with these specific wavelengths seems to provide a bactericidal effect against periodontopathic bacteria, a reduction of lipopolysaccharides, and a high ability of bacterial biofilm and calculus removal. Recent clinical results have also indicated that non-surgical and surgical treatment of periodontitis and peri-implantitis with laser may lead to significant clinical improvements as evidenced by bleeding on probing, probing depth reduction and gain of clinical attachment. The aim of the present lecture is to evaluate, based on the currently available evidence, the use of laser for treatment of different periodontal diseases and specially periodontitis and peri-implantitis and to indicate its potential as a new treatment modality.

Thursday - May 2

## Roeland De Moor

MSc

Professor, Ghent University

Belgium



### The Evolution of the Bubble: New Frontiers for Laser Activated Irrigation

Hall A 15:30-16:15

Today, extensive knowledge has been gained in the field of Erbium laser induced cavitation. Whereas the focus was on primary bubbles in the past, the impact of secondary bubbles on fluid agitation has become more important. This allows to hold the fiber at the level of the pulp chamber, and no longer in the canal. The optodynamic efficacy, now, comes from enhanced pressure waves travelling at shock speeds to create shear flows (thanks to longer oscillation times of secondary cavitation bubbles) instead of coming from the shock waves that can be created during the implosion of the primary bubbles.

Thursday - May 2

## Aldo Brugnera Junior

DDS, MS, PhD

Associate Researcher, National Institute of Science and Technology (INCT) - Basic Optics and Applied to Life Sciences- IFSC, University of Sao Paulo

Brazil



### Biophotonics and the Dental Sciences. Clinical Application of Laser Therapy Based on Translational Preclinical Dental Research

Hall A 16:45-17:30

Light is a physical phenomenon, essential to most forms of life on Earth, being an important source of energy for them. Laser puts physics and biology in close contact, because it allows a precise exchange of information at a molecular level. In this lecture, we present two different types of treatments with Photobiomodulation (PBMT) based on clinical and scientific evidence. The first research is about dentinal hypersensitivity treatment as a result of clinical studies of laser application therapy based on translational preclinical dental research, which includes the possibility of preventing dentinal sensitivity in the preparation and cementation of porcelain laminates by applying PTL.

The second research was on patients who have lost interdental papilla and thus developed "black triangle", that has a negative aesthetic impact on them. In this context, gingival tissue regeneration could be achieved by tissue engineering (stem cells, scaffolds and growth factors). It has been demonstrated that blood clots originating from locally provoked bleedings is rich in mesenchymal stem cells (MSCs), but they need further stimuli to preserve viability and further differentiation.

Photobiomodulation Therapy (PBMT) has shown positive effects when applied in tissue engineering. PBMT improves survival, proliferation, migration and differentiation of stem cells of dentoalveolar origin.

Thursday - May 2

## Ambrose Chan

Dr PhD, BDS Hon, G Dip Clin Dent, MScDent, FRACDS, FICD

Honorary Assistant Professor, Faculty of Dentistry, University of Hong Kong  
Honorary Research Affiliate, Faculty of Dentistry, University of Sydney  
Radiation Safety Officer, Queensland Health, Australia

Australia



### Pre-Emptive Dental Anaesthesia by Nd:Yag Photobiomodulation- Part I

Hall A 17:30-18:15

Due to the invasive and often painful nature of conventional dental procedures, pre-emptive anaesthesia with injectable local anaesthesia (LA) is routinely used for pain management. Fears of pain and needle injection are associated with aversive experiences, leading to poor oral health and increasing dental avoidance. There is a growing demand for a non-drug, non-invasive and anxiety-free alternative, particularly in young patients and those medically-compromised patients who are on regular poly-medication. The clinical use of Photobiomodulation delivered by Nd:YAG photons emerges as a holistic alternative for pre-emptive dental anaesthesia, including its effectiveness, safety and possible mechanism of actions will be discussed.

Thursday - May 2

## Cesare Luzi

DDS, MS

Visiting Professor, University of Ferrara

Italy



### Why Do Miniscrews Change the Rules of the Game in Daily Clinical Practice?

Hall B 09:00-11:30

## WORKSHOP ORTHODONTICS

Skeletal anchorage has broadly widened the spectrum of modern orthodontics and increased the clinician's possible treatment options, both when dealing with growing patients and with adult patients with compromised dentitions. Absolute anchorage can now be planned in any clinical situation aiding the clinician in difficult tasks like space closure, vertical control, intrusion and extrusion of group of teeth, forced eruption of impacted teeth, class II mechanics and many more which will be described.

In particular, adult patients, which generally request an inter-disciplinary management of the dentition, often present anatomical lack of teeth usable for anchorage purposes, or need of absolute anchorage as no side effects can be accepted. Orthodontic mini-screws have literally changed the rules of the game allowing new and extremely convenient treatment protocols which were not possible to realize with traditional dental anchorage. Their rational use together with interdisciplinary treatment planning will be discussed through a series of case presentations.

Possible risks and complications will also be explained, highlighting the most important factors leading to clinical success.

Thursday - May 2

## Cesare Luzi

DDS, MS

Visiting Professor, University of Ferrara

Italy



### New Trends in Self-Ligation with Dual Activation Mechanics

Hall B 14:00-14:45

Self-ligating brackets and the concept of low friction brought on the orthodontic market an increasing number of innovative treatment techniques and philosophies mainly centered on the characteristics of the brackets and wires used. Unfortunately, this took away attention from the solid principles of a correct and detailed diagnosis, focusing on the concept of a “simple” and “pre-packaged” orthodontics in which the malocclusions adapt to the mechanics and not vice versa.

New generation brackets and archwires should not guide the treatment decisions but should guarantee to the clinician complete reliability in the expression of prescription values and simplify the journey to treatment objectives. Low friction is often synonymous of lack of control, especially when using passive-type brackets, because of the use of undersized archwires in oversized slots, generating difficulties in torque control, rotation control and finishing of the occlusion.

The Dual Activation System allows the possibility of taking the best characteristics of active brackets for maximum 3D control on the anterior segment allowing at the same time freedom to slide and low friction features in the side segments. This presentation will highlight the benefits of this system through a series of case reports.

Thursday - May 2

## Antoine Darazé

DDS, MSc, DSO

Senior Lecturer and Head, Department of Orthodontics and Dentofacial Orthopedics, Faculty of Dental Medicine, Lebanese University

Lebanon



### Physical, Clinical and Cephalometric Assessment of Upper Airways: A New Paradigm in Orthodontics

Hall B 14:45-15:05

Upper airways assessment remains uncompleted and unstandardized in orthodontics. No protocol or consensus has been developed for this purpose. The big challenge in airway orthodontics is to assess all the structures, recognize the importance of airway size and create advanced solutions for airway-related craniofacial dysfunctions. A combination of physical, clinical and cephalometric assessment in a standardized and systematic manner is considered as an extra effort at pinpointing the cause of some orthodontic problems. This will help orthodontists in identifying the involvement of airways and in taking into consideration a more appropriate treatment planning.

The purpose of this presentation is to answer orthodontists about how to assess upper airways and to paint a full picture of what are the proper tools that can be helpful for screening and for a better orthodontic success.

Thursday - May 2

## Mona Sayegh Ghoussoub

DCD, CECSMO, CESA, CEASB-ODF

Chief of Clinical Services, Department of Orthodontics and Dentofacial Orthopedics, Faculty of Dental Medicine, Lebanese University

Lebanon



### New Cephalometric Landmarks Identification in Rapid Maxillary Expansion

Hall B 15:05-15:25

The earliest report of maxillary expansion was in 1860 by Emerson Colon Angell, who claimed to have achieved opening of midpalatal suture and described a gap between the maxillary central incisors. Although the technique was discredited at that time, Rapid Maxillary Expansion (RME) became commonly used only after the second half of the 20th century with the landmark study conducted by Haas. This procedure is recommended for increasing maxillary arch width deficiency, correction of unilateral or bilateral crossbite, reducing nasal resistance to provide a normal breathing pattern, and mobilization of the maxillary sutures to facilitate correction of a Class II or Class III malocclusion. For several decades, two-dimensional (2D) cephalometric radiographs have been used successfully in orthodontics to diagnose and treat malocclusions. Despite its efficiency, it does present some shortcomings and limitations. Moreover, the introduction of CBCT in dental radiology and its various implementation for many clinical applications in dentistry has stimulated interest in using 3D cephalometric analysis for routine orthodontic cases.

Therefore, a novel cephalometric approach using 3D surface model reconstruction, digitization and identification of landmarks and reference planes will be presented to demonstrate the effect of RME on the different anatomic structures especially at the temporomandibular joint region.

Thursday - May 2

## Maria Haydar

BDS, DESS, MSc

Chief of Clinical Services, Department of Orthodontics and Dentofacial Orthopedics, Lebanese University Faculty of Dental Medicine

Lebanon



### Involvement of Speech Therapists in Orthodontic Treatment in Lebanon

Hall B 15:25-15:45

Speech sounds develop in normal children from birth through a learning-based process, in close relation to the environment the child is exposed to and to articulators located in the oral cavity. Particularly, the teeth serve as useful landmarks for the tongue and play a prominent role during the production of certain speech sounds, yet individuals with malocclusions do not necessarily develop speech problems.

The aim of the present survey was to assess the cooperation between orthodontists and speech therapists in Lebanon to ensure optimal patient outcome. Speech therapists practicing for at least 5 years in Lebanon were asked to fill a questionnaire to evaluate the relationship and cooperation between them and the orthodontists. In total 51 questionnaires were answered and collected for descriptive data analysis. 68.63% of the speech therapists reported that they rarely received patients referred from orthodontic cabinets, and atypical swallowing pattern was the highest referral complaint followed by low tongue position at rest. On the other hand, 15% never referred their patients to orthodontists and 45% rarely did. Almost 80% of speech therapists found the cooperation with orthodontists insufficient. The importance of the inclusion of valid speech tests at the diagnosis stage for each patient in orthodontic practice is highlighted.

Thursday - May 2

## Ibrahim Nasseh

DDS, DSO, FITI, FICD

Professor, Department of Oral Medicine and Maxillofacial Radiology, Faculty of Dental Medicine, Lebanese University

Lebanon



### Diagnostic Considerations in Soft Tissue Calcifications

Hall B 16:00-16:30

Head and neck soft tissues calcifications can result from physiological or pathological mineralization. Some of these calcifications may be found on panoramic radiography superimposed over hard and soft tissue structures. Since cone-beam computed tomography (CBCT) has been used in dentistry, fortuitous discovery of such calcifications has increased. However, by providing images in the third dimension, CBCT facilitates their precise localization.

Differentiation of these calcifications create a diagnostic challenge. Adequate diagnosis of these entities may enhance their approach and management by clinicians.

The aim of this lecture is to describe the radiographic characteristics of head and neck calcifications found on panoramic and CBCT images in daily dental practice.

Thursday - May 2

## Elie Hayek

BDS, DESS

Chief of Clinical Services, Department of Oral Medicine and Maxillofacial Radiology, Faculty of Dental Medicine, Lebanese University

Lebanon



### A Radiologic Approach to Evaluate Radiopacities Jaw Lesion for Simplified Differential Diagnosis

Hall B 16:30-16:50

Conventional and imaging radiography were used to analyze asymptomatic radiopaque lesions in the jaw bone and establish the diagnostic relevance of the lesions based on their relationships to teeth and sites. A systematic approach is necessary for the evaluation of the radiopaque jaw lesions and to provide at least a simple differential diagnosis. The most important step in evaluating a radiopaque jaw lesion, is to classify the lesion according to its characteristics imaging features, its relationship to the teeth, and its aspect. On the basis of lesion attenuation, it can be classified type of a lesion as sclerotic lesion or a lesion with ground glass appearance. Once the type has been determined, it is easy to create a proper differential diagnosis. In addition, the presence of different clinical and radiological features, such as margination, a perilesional halo, bone expansion, and growth pattern decrease the differential diagnosis.

A radiologic approach for simplified differential diagnosis may be made by categorizing the radiopaque lesions relating to its relation to the teeth, imaging features and sites or locations.

Thursday - May 2



## Alexandre Khairallah

BDS, PGD, HSSD, FEADMFR, FICD, MBAIRD

Chief of Clinical Services, Department of Oral Medicine and Maxillofacial Radiology, Faculty of Dental Medicine, Lebanese University

Lebanon



### Radiopacities from Incidental Findings to Real Pathologies

Hall B 17:20-17:50

Radiopacities found on X rays are usually a pathognomonic sign of pathologies but sometimes they are only incidental findings. The differential diagnosis of these radiopacities will differ according to their place, relation with teeth and radiological characteristics.

In this presentation, a series of clinical cases of radiopacities and their differential diagnosis will be discussed interactively.

Thursday - May 2

## Sara Moussa

BDS, DESS, DU, MS

Clinical Instructor, Department of Oral Medicine and Maxillofacial Radiology, Faculty of Dental Medicine, Lebanese University

Lebanon



### A Radiological Based Diagnostic Algorithm for Detecting Pathologies Associated with Radiopaque Components

Hall B 17:50-18:10

A systematic approach for evaluation of radiopaque jaw lesions is mandatory to reach a meaningful differential diagnose of the lesion. Many jaw lesions resemble each other radiographically, making them difficult to diagnose correctly.

Focusing on the patient's history, along with an analytical approach to radiographs, helps to narrow the differential diagnosis by categorizing the lesions according to its position, relationship to the adjacent structure size, shape...These basic observations are essential to the evaluation of any type of jaw lesion.

The aim of this lecture is to formulate new proposal algorithm in order to assist dental practitioners in performing differential diagnosis based on the patient radiographs and his clinical assessment. This algorithm will be done by showing a series of case reports of different pathologies associated with radiopaque components describing their radiological features combined with the clinical approach.

Thursday - May 2

## Nabil Ouatik

DMD, MSc, FRCD(C)

Clinical Lecturer, McGill University

Canada



### SMART, SDF, Hall: Why Do We See a Trend Towards Biological Approaches in Pediatric Dentistry?

Hall C 09:00-09:45

Dental caries remains one of the most common chronic diseases for children in most countries. We are now entering an era of change, where the caries challenge will increasingly be addressed using the latest tools and evidence. There has been unprecedented interest in the use of silver diamine fluoride (SDF) in pediatric dentistry ever since it has become available in North America. An abundance of scientific literature has shown that it is very effective at combating dental caries. This talk will walk through the scientific evidence, which helped SDF earn the coveted FDA designation of "Breakthrough Therapy". Non-invasive options like SDF, SMART and Hall have the potential to modify current approaches in pediatric dentistry, dentistry for persons with special health care needs, and public health dentistry. Equally important, in pediatric dental practice, these therapies have the potential to offer more effective treatment and improve patient satisfaction.

Thursday - May 2

## Bourane Ambriss

BDS, DESS

Clinical Instructor, Department of Pediatric Dentistry and Dental Public Health, Faculty of Dental Medicine, Lebanese University

Lebanon



### Fiberglass Crowns in Pediatric Dentistry: Overview and Updates

Hall C 09:45-10:05

Surveying with pediatric dentists across the globe, we experience the same frustrations with all existing pre-formed dental crowns on the market due to their limitations and pitfalls. Designed by a pediatric dentist, fiberglass reinforced resin crowns are becoming the new standard for dental restorations. From an ease of use product to a true cosmetic perception that mimics the anatomy of a real tooth, these crowns exceed stainless steel, strip, and especially zirconia crowns. They have a unique flex-fit technology that hugs the tooth, avoiding the open margin (passive-fit) as well as being autoclavable and adjustable. Taking advantage of their radiographic features, the radiolucent crowns allow the dentist to monitor the tooth pulp, the surrounding bone structures as well as the interproximal caries on adjacent teeth with no overlap, thus minimizing the exposure to radiation for the child. Being metal-free products, these crowns enable patients with cancer to receive an MRI without any problem. Furthermore, with a technique and preparation similar to stainless steel crowns, the time required for the restorative procedure is reduced. A new research shedding the light on the versatile characteristics of fiberglass crowns and several clinical cases will be discussed in this lecture.

Thursday - May 2

## Hoda Al Moussawi

BDS, DESS, MS

Department of Pediatric Dentistry and Dental Public Health, Faculty of Dental Medicine, Lebanese University

Lebanon



### Early Diagnosis and Surgical Management of a Complex Odontoma. A Clinical Case

Hall C 10:05-10:25

Odontomas are the most common type of odontogenic tumor occurring within the jaws and are frequently associated with retained deciduous teeth, interfering with the eruption of permanent teeth. Complex odontoma consists of a disorganized mass with no morphologic resemblance to a tooth. A clinical report about a 6-year-old girl presenting a typical case of complex odontoma in the maxillary anterior region will be presented. Based on Cone beam computed tomography (CBCT) analysis, the odontoma was impacted in a buccal position. Moreover, it had a very close relationship with the germ of the permanent maxillary left central incisor whose eruption pathway was impeded by the structure. The treatment consisted of a surgical removal of the lesion with a minimal invasive technique to preserve the maximum amount of bone tissue. A special attention was given to the assessment of the social, emotional, and psychological status of the pediatric patient prior to surgery. The embedded odontoma was totally extracted without any injury to the adjacent tooth. Follow-up examinations were done after 1 week, 3, 6, and 9 months to control the eruption of the permanent maxillary left central incisor.

Thursday - May 2

## Marlène Khoury Freiha

DCD, MS, CESA, CESB, PhD

Clinical Professor, Department of Pediatric Dentistry, Faculty of Dental Medicine, Saint-Joseph University

Lebanon

## Krikor Sahakian

PhD

Associate Professor, Faculty of Pharmacy, Saint-Joseph University



### L'Utilisation des Probiotiques en Odontologie Pédiatrique

Hall C 10:25-10:55

Le développement de la résistance de certaines bactéries aux antibiotiques, l'effet délétère dû à une surconsommation et un mésusage de ces mêmes antibiotiques sur la santé buccale, mais également sur le développement de pathologies chroniques, et l'augmentation du taux de carie dentaire de par le monde et surtout au Liban, nous invitent à réfléchir sur des nouvelles pistes comme l'utilisation des bactéries non pathogènes pour régulariser la flore bactérienne orale.

De nombreuses études soutiennent le rôle bénéfique des probiotiques dans la santé gastro-intestinale. De nos jours La littérature suggère que l'utilisation de probiotiques pourrait être bénéfique pour le maintien de la santé bucco-dentaire, en raison de sa capacité à diminuer la colonisation bactérienne pathogène orale. Cependant, des essais cliniques randomisés avec des périodes de suivi à long terme sont nécessaires pour confirmer leur efficacité dans la réduction de la prévalence/incidence des maladies infectieuses orales. En outre, la reconnaissance de souches spécifiques avec une activité probiotique pour chaque maladie buccale infectieuse est nécessaire, afin de déterminer la dose exacte, le temps de traitement et les véhicules idéaux.

Le but de cette communication est d'inviter les dentistes à réfléchir d'une façon plus «probiotique» dans la prévention et dans la prise en charge des maladies bucco-dentaires.

Thursday - May 2

## Riad Bacho

DCD, DSO, FICD

Associate Professor, Department of Pediatric Dentistry and Dental Public Health, Faculty of Dental Medicine, Lebanese University

Lebanon



### An Interactive Approach to Pediatric Dentistry Cases

Hall C 10:55-11:25

Most dental lectures involve a predominantly one-sided experience in which the expert outputs the subject matter to the recipient. While this traditional technique has proven to be an effective method of delivering information to willing participants, audience discussion and participation is often minimal. The interactive approach to lectures, especially those with a focus on presenting clinical cases, can prove to be an engaging alternative to the traditional seminar. The information will be unfolded with the help of the interactive participants, resulting in a more dynamic and exciting exchange of knowledge. Pediatric dentistry cases will be presented. An interactive discussion regarding diagnosis/treatment modalities will be implemented through a special application on participants mobile phones.

Thursday - May 2

## Stefano Gracis

DMD, MSD

Private practice

Italy



### Impressions for Tooth Supported and Implant Supported Restorations: Materials and Techniques

Hall C 14:00-14:45

To many professionals, final impression is a very stressful moment of the prosthetic work on which they believe they have little or no control. Every time that an impression is not satisfactory, they do not know whether to blame the material or the technique. This lecture will attempt to answer the following question: does a satisfactory impression depend more on the choice of an "accurate" material or on the utilization of a proper technique?

The topics addressed are:

- Types of impression materials available
- Criteria for material selection
- Soft tissue retraction (methods and agents)
- Step-by-step impression technique for tooth-supported restorations
- Objectives and peculiarities of impression taking for implant-supported restorations

Thursday - May 2

## Georges Tehini

DDS, CAGS, MScD, DSO

Assistant Professor, Department of Prosthodontics,  
Lebanese University

Lebanon



### Retention and Wear of Locator® Attachments in Implantology

Hall C 14:45-15:15

Limited information is currently available relative to the various factors affecting retention and wear of Locator® attachments. Articles found in the literature cover some aspects of the problem but not all of them. In this lecture, we will present an interesting new theme that seems to have a direct effect on retention and wear; Chewing and masticatory loading. While all researchers pointed out the complexity of the wear process, our study contributes in the understanding of the involved factors and helps in decreasing the maintenance demands of the Locator® Attachments.

Thursday - May 2

## Mohammad Rayyan

BSc, MSc, PhD, DiplImp

Associate Professor, Department of Oral  
Rehabilitation Sciences, Faculty of Dentistry, Beirut  
Arab University

Lebanon



### Digitally Driven Prosthetic Restorations

Hall C 15:15-15:45

Digital dentistry offered many advantages to prosthetic dentistry. Speed, precision and predictable outcomes were among the fruits of computer aided dentistry. Nowadays, the bar of digital dentistry has risen few more notches, where predicable results encouraged dental scientists to apply the concept of reverse engineering to dental prosthesis.

Thursday - May 2

## Elie Daou

DCD, MSc, DES, DSO

Lecturer, Department of Prosthodontics, Faculty of Dental Medicine, Lebanese University

Lebanon



### Micro-CT Technology for the Evaluation of Novel CAD-CAM Pre-Sintered Co-Cr

Hall C 15:45-16:05

A novel pre-sintered Ceramill Sintron CAD-CAM Cobalt-Chromium has been introduced to the market. This alloy was designed to provide homogeneous and distortion-free frameworks through a maximum process reliability. No specific veneering porcelain is required.

Restoration longevity rely on different criteria. Marginal adaptation is considered as a key factor. Several techniques were used to evaluate a prosthesis adaptation and micro-computed tomography (micro-CT) was recently proposed. Few studies considered this methodology as a reliable and non-destructive technique to evaluate the internal and marginal adaptation of dental restorations. The core-ceramic interface also plays a role in the prosthesis success over time. This study was designed to evaluate the novel pre-sintered Ceramill Sintron using new measuring technology.

Thursday - May 2

## Jan Paulics

DDS

Private Practice

Sweden



### New Opportunities for your Dental Practice with Intraoral Scanning, Digital Implant Planning and Surgical Guides

Hall C 16:20-17:05

See a presentation of the benefits with digital impressions especially in conjunction with guided prosthetics. See a comparison to the old analog techniques and what you can do today that was not even possible before.

Learning objectives:

- To understand the benefits with digital impressions.
- To know the possibilities of planning and producing surgical guides in your own clinic.

Thursday - May 2

## Habib Abi Aad

DCD, DSO

Lecturer, Department of Prosthodontics, Faculty of Dental Medicine, Lebanese University

Lebanon



### Immediate vs Conventional Loading in the Posterior Maxilla

Hall C 17:05-17:35

Traditionally, implant treatment is based on a 2-stage protocol with a healing period of 2-4 months during which the implants achieve osseointegration. This clinical concept has been revisited and immediate loading of implants has recently been demonstrated to be a predictable procedure with high success rates in multiple clinical applications including full edentulism in the maxilla and mandible, single tooth replacement in the anterior and posterior areas, and overdentures both maxillary and mandibular. Lack of data has been covered as to the results of immediate loading in partially edentulous patients and more specifically in the posterior maxilla. Our research helps clarifying some issues that can provide the clinician with new reliable guidelines.

Thursday - May 2

## Jihad Fakhouri

DCD, DU, DES, DEA, MS, PhD

Professor, Department of Removable Prosthesis, Faculty of Dental Medicine, Saint-Joseph University

Lebanon



### Peut-on Éviter de Prendre une Empreinte en Prothèse Hybride Supra Implantaire?

Hall C 17:35-18:05

L'élaboration d'une prothèse hybride implant-retenue requière une haute précision dans le transfert des données de la clinique au laboratoire. Toute imperfection dans l'enregistrement des informations nécessaires à la réalisation d'un montage occlusal adéquat a pour conséquence des complications post-prothétiques certaines.

Les principales données reposent sur l'emplacement des implants ainsi que le rapport intermaxillaire dans les trois plans de l'espace.

La qualité de l'empreinte est tributaire du matériau ainsi que de la technique utilisée. De nos jours, un seul dispositif permet de soustraire cette étape de la construction prothétique mais la technique reste limitée quant à ses exigences anatomiques.

Le plâtre blanc de Paris semble être le produit qui convient le mieux à ce genre d'enregistrement, ses qualités physico-chimiques en témoignent.

Il est évident qu'aucun compromis n'est permis puisque les répercussions d'une moindre imprécision se ressentiront sur la réalisation prothétique, ses moyens d'incrustation, sur les accessoires intermédiaires ou même sur les implants.

Thursday - May 2

## Foudda Homsy

BDS, DES, DSO

Lecturer, Department of Prosthodontics, Faculty of Dental Medicine, Lebanese University.

Lebanon



### Factors Affecting the Accuracy of All-Ceramic Restorations Related to Digitalization and Manufacturing Procedures

Hall C 18:05-18:25

Fit accuracy is considered one of the most important criteria for the clinical quality and success of ceramic restorations. Digital dentistry allows the production of dental restorations with more advanced technologies such as subtractive milling/machining with computer assisted design/computer assisted manufacturing (CAD/CAM) systems or additive manufacturing with rapid prototyping through direct and indirect optical scanners. These new systems were suggested to generate more accurately fitting restorations.

Several factors have been documented to influence the fit accuracy of dental restorations including restoration-related, impression-related and manufacturing-related parameters. In the digitally-produced restorations, additional factors related to the scanning device, design software and settings are significant in dictating the fit at the restoration-tooth interface. Milling machine accuracy, milling-related conditions such as quality and size of the burs and material properties are important factors that can influence the fit accuracy in subtractive procedures. Laser speed and intensity, angle and building direction, number of layers, software, shrinkage between layers, amount of supportive material and post-processing procedures are related factors affecting the accuracy in additive technologies.

The aim of this lecture is to present the different factors affecting the accuracy of all-ceramic restorations fabricated through subtractive and additive technologies.

Thursday - May 2

## Georges KHOURY

DDS, MSc

Assistant Professor, Faculty of Medicine, Lille II  
Assistant Professor, Paris Hospitals, Dental School,  
Paris VII

France



### The Collagenous Matrix in Bone Augmentation

Hall D 14:00-14:45

Some biomaterials include in their composition a structural or added collagen matrix. This matrix is also present in autologous bone, conferring it with increased tolerance and incorporation properties. It represents about 30% of the native bone structure. Its presence in biomaterials facilitates its implementation and the cohesion of particles in a large number of indications, while potentiating its incorporation.

The benefits of this collagen matrix will be exposed through clinical cases both in terms of vascular induction and dimensional stability.

Thursday - May 2



## Nabih Nader

BDS, CES, DU

Chief of Clinical Services, Department of Oral and Maxillofacial Surgery, Faculty of Dental Medicine, Lebanese University

Lebanon



### The Cortico-Cancellous Soft Tissue Punch: A Novel Procedure for Alveolar Ridge Preservation

Hall D 14:45-15:15

After tooth extraction, the alveolar ridge will commonly decrease in volume and change morphologically. Careful management of extraction site prevents unsightly bone loss and secure a better cosmetic outcome of tooth replacement. Today, with the increasingly frequent use of dental implants to replace non-restorable teeth, preservation of the existing alveolus is essential to maintain adequate bone volume for placement and stabilization of the implants. Atraumatic extraction and socket preservation techniques have been introduced to minimize bone resorption after tooth extraction and, thus, allows treatment that satisfies esthetic and functional criteria. The purpose of the presentation is to focus on most common alveolar ridge preservation procedures following tooth extraction; a novel technique using Autogenous Cortico-Cancellous Soft Tissue Punch technique (ACCP) will be presented: Histology and clinical evidence is reviewed to provide an in-depth understanding of the logic behind and value this new socket preservation approach.

Thursday - May 2

## Ronald Younes

DCD, MSc, PhD, FICD

Assistant Professor and Head, Department of Oral Surgery, Faculty of Dental Medicine, Saint-Joseph University of Beirut

Lebanon



### Future Directions in Bone Reconstruction of the Upper Maxilla

Hall D 15:15-15:45

Placement of endosseous implants in the edentulous atrophic maxilla is often difficult because of a lack of supporting bone. Sinus augmentation procedures (both lateral and crestal) have been extensively used in the molar area and showed predictable long-term results. However, today, the clinician should deal with many challenging clinical situations in the premolar area as well as the esthetic anterior zone and should offer his patients long-term predictable implant rehabilitation. Therefore, a careful pre-operative assessment of numerous clinical and radiological parameters is needed to assess the proper bone reconstruction technique.

Numerous innovative technical variations will be discussed including GBR, onlay 2D/3D blocks and Horizontal segmental osteotomy. A key aim of this lecture is to assist the practitioner in selecting the appropriate bone augmentation technique based on the evaluation of a number of parameters that are described in detail and codified in a simple and practical way.

Thursday - May 2

## Paul Weigl

DDS, MSc

Head, Department of Postgraduate Education,  
Faculty of Oral and Dental Medicine, Goethe-  
University Frankfurt am Main

Germany



### Brilliant and Sustainable Pink Aesthetics Through Immediate and Minimally Invasive Shaping of the Peri-Implant Soft Tissue

Hall D 16:15-17:00

Today, about 80% of implants are placed in a single tooth gap. A therapy concept offered in today dental practice must be able to serve the main stream of patients that is predominant: brilliant esthetic results, treatment appointments reduced to a minimum and minimal invasive procedure. These requirements provide anatomic-functional shaping of the peri-implant soft tissue immediately after implant placement or after re-entry of a submerged healed implant. In the so-called soft tissue transition zone, the prosthetic components abutment and / or crown simulate the root portion of the missing tooth and thereby form a nature-identical emergence profile. The therapy concept includes only two treatment appointments and avoids the change of abutments. This sometimes requires new work steps and workflows between surgeon, dentist and dental technology. The therapy concept stands in contrast to a stepwise shaping of the soft tissue. In case of sufficient primary stability, an immediate restoration with a temporary single crown with infra-occlusion is prioritized. In addition to conventional clinical and dental procedures, the following digital workflows are suitable for:

- the own production of a patient-specific abutment, the temporary and the final crown with a chairside CAD / CAM system (e.g. CEREC®)
- the outsourced production and deployment of the patient-specific abutment, temporary crown and ZrO2 framework of the final crown prior to fully guided implant placement.

## Ziad Noujeim

DCD, CES, DU, DIU, FICD, FACOMS, FIAOMS,  
FEBOS, FDI Speaker

Senior Lecturer / Postgraduate Tutor, Department  
of Oral and Maxillofacial Surgery, Faculty of Dental  
Medicine, Lebanese University

Lebanon



### Jaw Cysts and Tumors Management at Lebanese University: from Presumptive Diagnosis to Final Treatment

Hall D 17:05-17:35

Oral Surgery is constantly developing as a dental specialty, with new techniques and technologies being embraced. These developments and advancements are regularly incorporated at the Lebanese University, Department of Oral and Maxillofacial Surgery. However, full attention is also paid to the basis of patient assessment and diagnosis, which form the cornerstone of any surgical specialty. Jaw pathology is a very specific surgical-pathological discipline that requires knowledge, expertise, and skills in surgical techniques and oral pathology. Most surgical operations in dentistry are performed by surgical dentists and periodontists but there is an increasing need for trained oral surgeons in the world nowadays. Indeed, management of jaw cysts and tumors is an operative field that was a no-man's-land partly controlled by general surgeons, partly controlled by ENT surgeons and plastic and reconstructive surgeons, but has now come to be the field of a specialized branch of dentistry.

In this oral presentation, we will address a large variety of cystic and neoplastic lesions of jaws that were diagnosed and treated at the Department of Oral and Maxillofacial Surgery at Lebanese University Faculty of Dental Medicine in Beirut, Lebanon. For each presented clinical case, we will discuss principles of examination, diagnostic steps, treatment planning, and surgical considerations, including difficulties and hazards of the surgical operation.

**Georges Abi Hatem  
Samia Abou Jaoudé  
Mohammad Hassan Bacho  
Micheline Katramiz, Hitaf Nasseh  
Rola Zein**

Department of Pediatric Dentistry and  
Dental Public Health, Faculty of Dental  
Medicine, Lebanese University



### **Kiddy Caps: New and Improved Zirconia Crowns**

Hall 15:00-18:00

## **WORKSHOP PEDIATRIC DENTISTRY**

The workshop first consists of a presentation about the preparation, indications, contraindications, advantages and disadvantages of the zirconia crown “kiddy caps”. A hands-on will follow, during which every participant will perform 2 preparations then crown adaptation and cementation, one on a primary molar and one on a primary incisor. Trained instructors will supervise, help and answer the questions of participants during the session.

Thursday - May 2

**Wilhelm Pertot**

DCD, MSc, DEA, PhD

Lecturer, Rey Juan Carlos University

France



### **The Latest Reciprocating WaveOne Gold Files for Shaping Canals**

Hall 15:00-18:00

## **WORKSHOP ENDODONTICS**

WaveOne Gold® is the latest iteration of WaveOne®, launched in 2015, after 3 years of research and development. WaveOne Gold® maintains the philosophy of a specifically designed SINGLE Nickel Titanium instrument to shape canals utilizing a reciprocating motion after prior glide path enlargement.

WaveOne Gold® exhibits advanced heat-treated nickel-titanium alloy, with a newly designed parallelogram cross-section. The system features four optimized tip diameters to cover a broader range of canal morphologies, reduced tapers to fulfill the requirements of minimally invasive endodontics and offering better flexibility and more resistance to cyclic fatigue.

The new WaveOne Gold® improves safety and efficiency when shaping canals, allowing 3D disinfection and obturation.

In the majority of cases, only a single WaveOne Gold® Primary file is needed thus reducing the number of instruments in any given sequence to an absolute minimum. The influence of the reciprocation motion and of the single file shaping techniques on cyclic fatigue of instruments, on root canal transportation, debris extrusion, dentinal cracks, and cleanliness of the root canal system will be discussed. A link will be done between the scientific studies and their impact on the clinical root canal procedure, with a discussion of clinical tips through different clinical cases and videos.

Thursday - May 2

## David De Franco

DMD, DMedSc

Private practice

Italy

## Stefano Gracis



### Current Approaches in the Interdisciplinary Treatment Planning of Prosthetic and Orthodontic Patients

Hall A 09:00-09:45

In many partially edentulous patients requiring prosthesis and osseointegrated implants, orthodontic treatment is indicated to reposition natural teeth. This may be important to correct the sagittal, vertical and transverse positions of the teeth to improve masticatory function, create the necessary space for restoring the mesio-distal dimension of the crowns and obtain a satisfactory and natural looking esthetic outcome. Osseointegrated implants, as well as non-integrated mini-implants or temporary anchorage devices (TADs), can be used as anchorage to carry out the planned orthodontic movements, especially in patients with many missing teeth, and to support temporary crowns in edentulous areas. The treatment of such patients implicates a complete diagnosis, careful planning and an efficient line of communication between the orthodontist and the prosthodontist.

This lecture will illustrate the variables that should be taken into consideration when a combined ortho-implant-prosthetic treatment is necessary. Several clinical cases will help demonstrate the decision-making process.

Friday - May 3

## Jan Paulics

DDS

Private Practice

Sweden



### Advanced Features of the Intra-Oral Scanner Allowing the Dentist to Excel in Accuracy and Aesthetics

Hall A 09:45-10:30

A presentation of the benefits with digital impressions. See a comparison to the old analog techniques and what you can do today that wasn't even possible before. A walk-thru of the Workflows in intra oral scanning.

Learning Objectives:

- To understand the benefits with digital impressions.
- To know the possibilities of advanced intra oral scanning.

Friday - May 3

## Umberto Romeo

DDS

Associate Professor, Sapienza University, Rome

Italy



### Medication Related Osteonecrosis of the Jaw: Prevalence, Risk Factors, Clinical and Radiographic Characteristics

Hall A 11:00-11:45

Osteonecrosis of the jaws (ONJ) is an uncommon but severe bone disease, can be related to various medicaments including bisphosphonates, antiangiogenic and antiresorptive medicaments such as Denosumab, human monoclonal antibody to the receptor activator of nuclear factor- $\kappa$ B ligand. For this reason, the term ONJ was currently replaced by Medication Related Osteonecrosis of the jaws (MRONJ). The rise in number in the latest years can be explained with many patients treated with all these drugs, assumed for osteometabolic (i.e osteoporosis, osteogenesis imperfecta) or neoplastic diseases (multiple myeloma, metastatic breast, prostate and renal cancer). The onset mechanism of MRONJ is not entirely understood, probably different mechanisms are involved, such as inhibition of the osteoclasts differentiation and function, decrease of the angiogenesis and inflammation/infection of the jaw bones. The author, through the presentations of some clinical cases, describes the diagnostic and clinical aspects of MRONJ and explains how is possible to prevent or to manage the MRONJ.

Friday - May 3

## Lakshman Samaranayake

Hon DSc, BDS, DDS (Glas), FDSRCS (Edin),  
FRCPATH, FRACDS, FDSRCPS (Glas),  
FHKCPATH, FCDSHK

Visiting Professor, Sharjah University College of  
Dental Medicine, UAE  
Professor Emeritus, and Immediate Past Dean of  
Dentistry, University of Hong Kong, China

United Arab Emirates



### New Infections and Infection Control in Dentistry: Current Perspectives

Hall A 11:45-12:30

Although transmission of infectious agents among patients and dental health care workers in dental settings is rare there are still reports of such incidences. Notable breaches in basic infection prevention procedures include unsafe injection practices, failure to heat sterilize dental hand pieces, and failure to monitor autoclaves. These reports highlight the need for comprehensive training to improve and vigilance in maintaining the highest standards of care in dental practices. Moreover, the unrelenting emergence of new infectious disease emphasizes the need for keeping up with such information. This presentation will review the current basic infection control practices in dentistry and provide a glimpse of the new infections extant in the global community that may impact infection control in dental practice.

Friday - May 3

## Shankargouda Patil

BDS, MDS, PhD

Associate Professor, Department of Maxillofacial Surgery and Diagnostic Sciences, College of Dentistry, Jazan University

Saudi Arabia



### Oral Cancer

Hall A 12:30-13:15

The past decade has seen significant progress being made in the development of molecular diagnostic and treatment tools against oral cancer. Despite the advent of novel diagnostics and therapeutics, cancer control has largely been ineffective. The primary cause being the growing resistance in cancer and the inability of current treatment modalities to prevent loco-regional recurrence and distant metastasis. Although current treatment modalities effectively counter the primary tumor, they largely fail to diagnose and treat any potential minimal residual disease. Due to the lack of active therapeutic intervention post-primary therapy, the minimal residual disease has an increased risk of proliferation resulting in recurrences. It is also imperative to note that certain molecular treatment modalities have unintended effects which in turn can lead to the development of therapeutic resistance. For example, a recent study used inactivation of the DNA mismatch repair gene as a therapeutic modality. The basis for the study was that when the DNA mismatch repair genes are inactivated, they would result in additional mutations which would be interpreted by the immune system as a neoantigen generating sustained immune response against cancer. Although the studies have shown promising results, it is vital to acknowledge the potential complication of such endeavors. One such complication in this scenario is that if normal cells surrounding the cancer cells are exposed to DNA repair inhibition, they would develop mutation leading to neoplastic transformation. In addition, if the new mutation in the cancer cells does not elicit an immune response, it would just result in the accumulation of new mutation which in turn could increase the aggressiveness of cancer. Lack of progress in cancer control could also be explained by the lack of awareness as to several unknown potential risk factors in oral cancer. One such potential risk factor is the household air pollution (HAP). Despite HAP being closely associated with lung cancer and that HAP and oral cancer have an epidemiological association, there has been a lack of studies examining the role of HAP as a potential risk for oral cancer. Thus, until we are able to uncover all the potential causes of oral cancer and effectively counter these etiologic factors, it is not possible to curb the growing prevalence of oral cancer. Thus, my lecture would cover the current challenges in oral cancer control and future directions in oral cancer research.

## Paul Weigl

DDS, MSc

Head, Department of Postgraduate Education, Faculty of Oral and Dental Medicine, Goethe-University Frankfurt am Main

Germany



### The Socket Chamber Concept: Clinical Outcomes of Immediate Implant Placement and Restoration

Hall A 14:15-15:00

An immediate implant placement has to be combined with a primary wound healing of the extraction socket by a seal with a root-shaped abutment/crown complex. The resulting socket chamber is filled with blood which has a very high potential for healing and for new bone formation. The blood-filled chamber completely ossified without any therapeutic support - the placement of membranes and bone replacement materials in case of a lack of buccal bone lamella loses its dogmatic required application. This kind of immediate restoration simulates a tooth-reimplantation in the transition zone requiring a flapless tooth extraction. It ensures the preservation of the original emergence profile including papillae and long-term esthetics. However, an appropriate implant thread design and osteotomy is mandatory to gain predictable a sufficient primary and secondary stability of the implant at the fresh extraction socket. Additionally, a two appointments work-flow enables an one-abutment-one-time concept preventing mid-facial soft-tissue recession. In addition, a meta-analysis showed that immediate implantation in an infected socket does not increase the risk of failure.

## Georges KHOURY

DDS, MSc

Assistant Professor, Faculty of Medicine, Lille II  
Assistant Professor, Paris Hospitals, Dental School,  
Paris VII

France



### Bone Regeneration: Where Are We?

Hall A 15:00-15:45

Bone augmentations are widely used in oral surgery due to a better development of biomaterials and membranes. The gold standard is still autogenous bone but it is rarely used and is becoming an exceptional treatment. Certainly, we can always consider that autogenous bone is not promoted by any commercial company, but how today we will use it for a sinus lifting grafting, knowing that it was the standard treatment during the nineties? Autogenous bone is known for the induction factors that still gives it advantage in terms of primary integration, but who among us did not find resorption occurring in his own patients?

What if the answer was in cellular mimicry? Could this explain the strong resorption of predominantly spongy bones compared to bones with high mineral density? It is not the same density available in some biomaterials? Of course, the latter lacks the organic component of collagen and non-collagenic proteins. Platelet factors are able to provide this induction supplement and compensate the absence of some factors?

In this lecture, all these questions will be exposed by the identification of the main components of the autologous bone and its possible availability in different biomaterials, the latter are already able to bring effective responses to a panel of bone defects.

Friday - May 3

## Giovanni Mauro

MD, DDS, MSc

Professor, University of Parma

Italy



### The Use of Botox in Bruxism

Hall A 16:15-17:00

Bruxism can be defined as a repetitive masticatory muscle activity (RMMA) characterized by clenching or grinding of the teeth and/or by bracing or thrusting of the mandible. It can occur during wakefulness (awake bruxism) or sleep (sleep bruxism). It is believed that the former is associated with other motor disorders, or with psychosocial factors and it is reported in 22.1 to 31% of the population. The latter is considered to be part of sleep arousal phenomena with a prevalence of 7.4% in the adult population. This lecture wishes to address the possible use of botulinum toxin (BoNT-A) injections in the management of bruxism. Available literature, techniques, pro, and cons will be evaluated, and clinical suggestions will be provided.

Friday - May 3

## Antoon De Laat

DDS, PhD

Professor, Department of Oral Health Sciences,  
Catholic University, Leuven

Belgium



### From Toothache to Orofacial Pain - What Did We (Have to) Learn?

Hall A 17:00-17:45

While during the previous century the dentist was more focused on acute pain and its intra-oral causes, the scope of our field widened over the past decades, also including more chronic pains. Consequently, the role of dentistry in the differential diagnosis of chronic orofacial pain became more important. This development paralleled the impressive progress made in the field of understanding pain in general, and the important role that dental scientists and clinicians had in this evolution. One example: from a more biomechanical thinking regarding the etiology of temporomandibular disorders, a more in-depth knowledge of the neurophysiology of the masticatory system and of the implementation of the biopsychosocial model of pain deemed necessary.

The present lecture will provide an overview of this period and the consequences it had for our profession. Indeed, along with the expanding scope of our field came the responsibility to strengthen our knowledge on pain physiology and on medical topics in general. Similarly, teachers should realize that if the future of dentistry will shift away from the technical precision and handcraft into more medical management of our patients, also our teaching and curricula need to modernize. In this way, and based upon the important realizations of our profession interacting with other medical specialists, a continuous improvement can be provided in the way we manage and treat our patients.

Friday - May 3

## Antoine Saadé

DCD, DU, CES, CECSMO, DSO

Lecturer, Department of Orthodontics and  
Dentofacial Orthopedics, Faculty of Dental  
Medicine, Lebanese University

Lebanon



### Skeletal Age Assessment on CBCT

Hall B 10:00-10:20

Skeletal age assessment is a required procedure in several fields of medical and dental specialties prior to intended treatment. In orthodontics, the aim of bone age estimation is to provide the accurate time from which an orthopedic correction of jaw discrepancies could be initiated. This decision has traditionally relied on hand-wrist or lateral cephalometric radiographs to detect modifications on epiphyses and cervical vertebrae. However, as use of CBCT in dental practice has increased in the past years, it prevented prescription of additional radiographs. In this lecture, a new method for skeletal age determination based on CBCT's craniofacial shape is developed. Results of this procedure are promising, yielding a highly accurate skeletal age assessment when compared to conventional methods.

Friday - May 3



## Anthony Macari

DCD, DESS, MS

Associate Professor, Division of Orthodontics and Dentofacial Orthopedics, American University of Beirut

Lebanon



### Update on Different Orthodontic Treatment Modalities in Adult Patients

Hall B 10:20-10:40

Nowadays, dentofacial esthetics has gained lots of interest among people with the increasing desire to enhance the smile and therefore the general appearance. This trend led to a higher demand for orthodontic treatment among the adult population.

The objective of this presentation is to explore the different approaches to treat adult individuals exhibiting complex malocclusions in sagittal, vertical and transverse dimensions. Treatment of adult subjects will be shown, and interdisciplinary approach with restorative dentists, periodontist and orthognathic surgeons will be emphasized.

Friday - May 3

## Bilal Koleilat

DCD, MS

Assistant Professor, Department of Orthodontics and Dentofacial Orthopedics, Faculty of Dental Medicine, Lebanese University

Lebanon



### Pushing the Envelope of Tooth Movement with Microimplant Anchorage

Hall B 10:40-11:00

The use of microimplants in anchorage control with little or no patient cooperation has been well established and documented. The contemporary orthodontist is able to reduce large overjets, protract, intrude and upright molars with relative ease. Microimplants allowed to push the envelope of tooth movement thus reducing the number of extraction cases. Mechanotherapies that once were labeled as unusual are now the trend, compromised results are now considered satisfactory with more focus on patient's occlusal and esthetic needs and concerns. This has led the practitioner to address treatment planning with a different mindset, question the limitations of old classical protocols and pave the way for new modalities in treating malocclusions.

The aim of this oral presentation is to show through multiple clinical cases how microimplants have enabled new perspectives in treatment planning compared to conventional ones.

Friday - May 3

## Ramzi Haddad

BDS, Res Ortho, DESS, MS

Assistant Professor, Division of Orthodontics,  
American University of Beirut

Lebanon



### The Orthodontic-Periodontal Interface

Hall B 11:30-11:50

In the present era, the importance of dental multidisciplinary treatment is crucial. The orthodontic-periodontics interdisciplinary approach is almost unavoidable in adult patients due to several factors: 1- Orthodontic treatment sometimes results in undesirable periodontal changes; 2- Orthodontics has been used as an adjunct treatment to periodontics and vice-versa; 3- The increasing demand for adult orthodontics, where periodontal problems might contribute to the development of malocclusion.

The objectives of this lecture are to: 1- highlight the benefits of orthodontic tooth movement in resolving some of the periodontal problems in adults and 2- describe different orthodontic mechanics in horizontal and vertical bone regeneration

Friday - May 3

## Fidele Nabbout

BDS, DUO, MS, PhD

Assistant Professor, Department of Orthodontics and  
Denfocfacial Orthopedics, Faculty of Dental Medicine,  
Lebanese University

Lebanon



### Class II Correction with Microimplant-Supported Molar Distalization

Hall B 11:50-12:10

Over the past decade, the use of anchorage screws is becoming a standard practice in orthodontics. The growing interest for microimplants is confirmed by the amount of recent published articles in the literature.

The potential use of microimplants has been demonstrated repeatedly during orthodontic treatment with fixed appliances for different types of movement, especially for molar distalization.

Their use allows to correct Class II malocclusions by avoiding extraction of premolars, decreasing the need for surgery in specific cases, and reducing patient compliance while keeping usual goals of treatment.

During this presentation, clinical cases will illustrate our therapeutic approach in Class II situations.

Friday - May 3

## David De Franco

DMD, DMedSc

Private practice

Italy



### Clinical Management of Impacted Canines

Hall B 12:10-12:55

The ectopic eruption and impaction of canines is a rather frequent clinical problem. The management of impacted canines can be challenging even for experienced orthodontists depending on its location and severity, as well as the presence of other complications such as root resorption and ankylosis. An interdisciplinary approach, usually involving the general or pediatric dentist, the periodontist or oral surgeon, and the orthodontist, is essential in the treatment of impacted canines in order to achieve good function, esthetics and stability. This lecture will address the clinical management of both maxillary and mandibular impacted canines with regard to diagnosis and treatment, different surgical procedures for uncovering canines, anchorage requirements and biomechanics. Several clinical cases will demonstrate the clinical management of impacted canines.

Friday - May 3

## Lakshman Samaranayake

Hon DSc, BDS, DDS (Glas), FDSRCS (Edin),  
FRCPATH, FRACDS, FDSRCPS (Glas),  
FHKCPATH, FCDSHK

Visiting Professor, Sharjah University College of  
Dental Medicine, UAE  
Professor Emeritus, and Immediate Past Dean of  
Dentistry, University of Hong Kong, China

United Arab Emirates



### Oral Microbiome and Systemic Health: Unraveling Fact from Fiction

Hall B 14:15-15:00

Oral microbiome is the term given to the totality of organisms and their resident oral ecosystem. Biofilms are an integral component of the oral microbiome. The two commonest human afflictions and the primary diseases of the oral cavity, caries and periodontal disease, are caused by oral biofilms- traditionally called dental plaque. There is a growing body of data that periodontal biofilms related diseases, can have profound effects on total health and longevity including atherosclerotic vascular disease, adverse pregnancy outcomes, diabetes and, pulmonary disease. New data indicate that kidney disease, pancreatic cancer and indeed oral cancer may be associated with oral biofilms.

This presentation will provide a state-of-the art overview of the oral microbiome in health and disease and how to unravel `fact from fiction` in the literature. The clinical relevance of the new data for the patient and the practitioner will also be discussed.

Friday - May 3

## Carlo Maksoud

DCD, DIU, DU, MSBM, CES,

Chief of Clinical Services, Department of Oral Medicine and Maxillofacial Radiology, Faculty of Dental Medicine, Lebanese University

Lebanon



### Alerting Signs Facing an Oral Ulceration

Hall B 15:00-15:20

Oral mucosal ulcerations are common. Most are self-resolving and transient but some may require a medical or dental intervention. Squamous cell carcinoma (SCC) represents about 95% of all oral malignancies.

In this lecture, we will discuss all symptoms and signs that conclude our diagnosis. SCC has poor prognosis and poor morbidity.

Friday - May 3

## Nadwa Chatila

BDS, DESS, MS, PhD

Lecturer, Department of Oral Medicine and Maxillofacial Radiology, Faculty of Dental Medicine, Lebanese University

Lebanon



### Alerting Signs Facing a Red and White Lesion

Hall B 15:20-15:40

Oral and pharyngeal cancer is the sixth most common cancer in the world. The most frequent tumor is squamous cell carcinoma, which represents 95% of oral cancers. It is generally established that epithelial cancer could be predated by a non-invasive lesion. These areas of altered mucosa, described according to their clinical appearance, may be a combination of white and red lesions. The disorders of concern are erythroleukoplakia, oral lichen planus and candidiasis.

The aim of this presentation is to review the clinical potentially malignant features of red and white lesions and to emphasis on the early signs for diagnosis.

Friday - May 3

## Shankargouda Patil

BDS, MDS, PhD

Associate Professor, Department of Maxillofacial Surgery and Diagnostic Sciences, College of Dentistry, Jazan University

Saudi Arabia



### Oral Potentially Malignant Disorders

Hall B 16:00-16:45

The term precancerous lesions and conditions were replaced by the term oral potentially malignant disorders (OPMDs) by WHO. The reason for the change in terminology was that precancer denotes that the lesion would eventually transform into cancer with utmost certainty, but, not all cases designated as precancer show malignant transformation. Many precancer cases have been reported to remain the same or even regress. Thus, the use of the term potentially malignant was a more precise indicator of its behavior. Despite implementing strict definition and diagnostic criteria for OPMDs, there are certain entities which are not well defined clinically or histopathologically. Oral lichenoid dysplasia and exophytic verrucous hyperplasia are two such entities wherein even their existence is not universally accepted.

Our research team has conducted multi-institute retrospective studies analyzing these two entities and their related lesions. The results of the study have provided significant insight into the true nature of these enigmatic entities which will be discussed in the presentation. Another critical issue concerning OPMDs is the lack of accuracy of our grading system to predict their malignant potential. The major limitation of all the major epithelial dysplasia grading system is the significant inter and intraobserver subjectivity. Our research team has explored the possibility of overcoming the subjectivity by formulating a customized grading system for each OPMDs. Each of the OPMDs and their respective malignant counterparts would be histopathologically assessed for dysplastic features. All the dysplastic features which were common for the OPMD and the malignant counterpart will be considered as the sole features to be considered in the grading system. Such a customised grading system would reduce the subjectivity of the grading and increase the accuracy of predicting the malignant risk.

Thus, my presentation would cover the natural history of the controversial OPMDs- oral lichenoid dysplasia and exophytic oral verrucous hyperplasia and emphasize the importance of formulating customised epithelial dysplasia grading system for OPMDs.

## Dolly Roukoz

BDS, DESS

Chief of Clinical Services, Department of Oral Medicine and Maxillofacial Radiology, Faculty of Dental Medicine, Lebanese University

Lebanon



### Alerting Signs Facing a White Lesion

Hall B 16:45-17:05

At the World Health Organization workshop held in 2005, the term oral potentially malignant disorders (OPMDs) was recommended instead of “pre-malignant lesions and conditions”. White lesions, with homogeneous or non-homogeneous clinical aspects, form a large chapter in oral pathology and constitute a range of potentially malignant lesions. Non-homogeneous white lesions may present a risk of potentially malignant transformation that varies from 6 to 25% in erosive lichen planus to 23.6% for non-homogeneous leukoplakia. Verifying the pre-malignant status of an oral white lesion requires an understanding of different clinical warning signs collected during clinical examination leading to a proper management for these lesions.

## Stefen Koubi

DDS, DEA, PhD

Associate Professor, School of Dentistry, Marseille University

France



### From Dogma to Everyday Dentistry in the Aesthetic Zone: Ingredients and Recipes from No Prep to Prepress

Hall C 09:00-09:45

Restoring tooth in the esthetic zone is a daily challenge. The issue is to predict the final result specially the color balance with the adequate value. Many parameters are concerned (choice of ingot, thickness of the prep, choice of resin cement, color of the substrate...).

The aim of this lecture is to present recipes when playing with crown, laminate veneer or no prep restoration suggesting a detailed clinical protocol according to the clinical situation. Both of these topics should not be addressed in an artistic way, since it is quite impossible to fit within everyday dentistry work; nevertheless, they can be worked out in a predictable way. Style Italiano indirect philosophy will be highlighted in this lecture.

Friday - May 3

## Jean-Claude Fahd

BDS, DESS

Chief of Clinical Services, Department of Restorative and Esthetic Dentistry and Endodontics, Faculty of Dental Medicine, Lebanese University

Lebanon



### How to Rebuild a Functional Posterior Restoration

Hall C 09:45-10:15

When restoring a posterior cavity, the dentist may face several difficulties. The aim of this lecture is to focus on reproducing tooth morphology during composite build up. It will also motivate and explain to the audience the state of the art of posterior composite restorations.

In addition to basic fundamentals that dentists have been using, new techniques, like stamp and wax up technique will be presented. Through clinical cases, a step by step technique coupled to critical thinking will provide practitioners with the opportunity to apply knowledge acquired in this lecture to the practice of dentistry in a variety of patient care settings.

At the end of this presentation, the audience will have different choices for building up a posterior restoration offering the best treatment modalities for their patients.

Friday - May 3

## Hala Ragab

BDS, MSc, PhD

Professor and Director, Division of Operative and Esthetic Dentistry, Faculty of Dentistry, Beirut Arab University

Lebanon/Egypt



### Does Digital Technology Improve Today's Clinical Practice in Smile Makeover Cases?

Hall C 10:15-10:45

This presentation will discuss the benefits of integration of digital technology when planning a smile makeover case. Three workflows will be discussed, the analogue and the digital and the hybrid approach and how digital integration made it possible to be more conservative, save time and gives more predictable results.

Friday - May 3

## Louis Hardan

DDS, CEA, DEA, PhD

Associate Professor and Head, Department of Esthetic and Restorative Dentistry, Saint-Joseph University

Lebanon



### Simplified Techniques and Materials to Overcome our Daily Challenge in Direct Composite Restorations

Hall C 11:15-11:45

Since their introduction in the 1970s, light activated resin composites have shown many shortcomings such as poor wear resistance, poor dentin marginal adaptation, problems of shade matching in esthetic cases and mainly polymerization shrinkage. With the new generation of composites, most of those problems are solved.

The aim of this lecture is to develop the optimal choice of composites and adhesive systems. It will also overview the novelties in restorative materials (low shrinkage composites) and dental technologies. Several clinical cases will be presented, showing how to perform esthetic composite restorations from simple to complex cases using simplified and repeatable techniques.

Friday - May 3

## Joseph Sabbagh

DDs, MSc, PhD, FICD

Associate Professor, Department of Restorative and Esthetic Dentistry and Endodontics, Faculty of Dental Medicine, Lebanese University

Lebanon



### Five Most Common Errors in Posterior Composites

Hall C 11:45-12:15

Direct composite restoration is a very common procedure used in daily practice by dentists. Filling posterior cavities using resin composites has always been a challenging task for dentists looking for a fast and reliable technique. Field isolation and bleeding control, the achievement of an tight contact point, the management of deep cavities and post-operative sensitivity are the most common errors encountered during posterior restorations. Besides the choice of a preforming resin-based material, and an adhesive system, the technique of using those products are of paramount importance.

The choice of the restoration is made according to different criteria: type and position of the tooth, remaining tooth structure, patient habits and hygiene, etc..... The aim of this presentation, using well documented clinical cases, is to offer to the dentist a precise analysis of the 5 most relevant clinical elements, in order to achieve a successful posterior restoration.

Friday - May 3

## Francesco Mangani

MD, DDS

Professor, Department of Restorative and Esthetic Dentistry, Tor Vergata University, Rome

Italy



### Operative Dentistry: What a Wonderful World- Part II

Hall C 12:15-13:00

Operative Dentistry has tremendously evolved in the last 38 years. Nowadays the request for tooth colored restorations and the maintenance of “a nice smiling” represents the main desire of our patients.

Predictable and repeatable results can be achieved through materials and clinical practices that, on one hand, preserve the original structure of the compromised tooth and, on the other hand, involve a very low biologic price. New technologies for dentino-enamel adhesion and the continuous evolution of more sophisticated esthetic materials such as composite and porcelain allow to reach effective and predictable results.

Very often, in congresses, courses on social media such as Facebook, that should be correctly called Facetooth, we assist to something more similar to “a dental show” than to “dental medicine”! People seem to be more concentrated on the quality of the images, the definition of the movies, showing “seductive minimally invasive” clinical cases that do not respect the fundamentals of Operative Dentistry and many times hide a lot of mistakes behind the word “ADHESION”. This lecture points out the relevant guidelines for both direct and indirect esthetic restorations through the evaluation of techniques and materials in order to reach correct, standardized and long-lasting evidence-based clinical results while respecting the principles of biomechanics.

Friday - May 3



## Frédéric Bukiet

DDS, MBD, MSc, PhD, HDR

Professor, Aix-Marseille University

France



### Contemporary Endodontics: Current Strategies and Perspectives

Hall C 14:00-14:45

In the past 10 years, considerable technological evolutions have been proposed to enhance root canal treatment quality, to make the latter less operator dependent and more reproducible. The goal of this lecture is to provide a critical overview of the following developments:

- CBCT use in Endodontic has revolutionized the preoperative evaluation of complex cases leading to better appreciate the tridimensional anatomy and to anticipate potential clinical difficulties. Currently, the CBCT images can be used with different software only selecting the tooth of interest, providing a tridimensional rendering and allowing a treatment plan.
- Conservative and ultraconservative access cavities have been proposed to decrease the loss of dental structures and the risk of fracture. This controversial topic needs clarification especially regarding the benefit/risk balance of such strategies.
- Nowadays, a lot of shaping systems are available in the market. Reciprocating single files have been recommended to improve the cyclic fatigue resistance and to avoid the screwing effect. Heat treatments of nickel-titanium files also contribute to increase their mechanical properties and their flexibility. Finally, new file design has been recently released aiming to improve the cleaning outcome. The main evolutions on root canal instrumentation will be discussed comparing the reciprocating movement and the continuous rotation.
- Due to their improved properties, bioceramic root canal sealers have been recommended to be used with the “single cone technique”. the clinical application of these materials for obturation of the root canal space will also be discussed.

## Carla Zogheib

DCD, MSc, PhD

Assistant Professor, Department of Endodontics,  
Faculty of Dental Medicine, Saint-Joseph University

Lebanon



### New trends in Root Canal Obturation in the Era of Minimal Invasive Endodontics

Hall C 14:00-15:15

Success in endodontic treatment is based on the equally important triad of debridement, disinfection, and obturation. When a step in the endodontic or restorative procedure is inadequate, apical seal is adversely affected. The ultimate goal of endodontic obturation has remained the same for the past 50 years: achieve a fluid-tight seal of the root canal system, from the coronal opening to the apical termination.

An ideal obturation technique should assure complete filling of the canal without overfill and with minimal or no voids. For this purpose, several techniques have been advocated for obturation. Thus, it is important to select a technique that offers consistency and is easy to use. Most of obturation studies show that all materials and techniques result in some degree of microscopic voids. Although a poorly obturated canal and voids are related, radiographic evaluation of obturation does not correlate well with obturation imperfections neither confirm an adequate seal. Fortunately, clinical success rates after endodontic treatment are high despite the varied conditions, materials, and techniques employed. An alternative recent approach is to minimize structural changes during root canal therapy, which may result in a new strategy that is the ‘minimally invasive endodontics’.

This presentation will provide an overview of the contemporary approach to root canal obturation. It will outline the full range of obturation materials including those traditionally used and newer, advanced ones that are now available that have active physical and biological properties. Obturation techniques will be reviewed based on experimental research and on evidence-based systematic analysis, considering factors affecting root canal treatment outcome highlighting the conservation of tooth structure to enhance longevity after root canal treatment. Actual success rate in endodontic treatment based on clinical reliable studies will also be discussed.

## Edmond Koyess

DCD, CES, DSO

Assistant Professor, Department of Restorative and Esthetic Dentistry and Endodontics, Lebanese University, Faculty of Dental Medicine

Lebanon



### Controversies in Minimally Invasive Endodontics

Hall C 15:15-15:45

Economy in dentin structure, in both conservative dentistry and endodontics, has a direct impact on tooth survival. The trend of minimally invasive endodontics has generated controversies when considering overzealous tooth structure economy and the need of adequate management of root canal anatomy.

The aim of this lecture is to draw a line between science fantasy and the laws of reality.

Friday - May 3

## Shanon Patel

BDS, MSc, MClintDent, MRD, PhD, FDS, FHE

King's College London Dental Institute

United Kingdom



### Cone Beam CT in Endodontics

Hall C 16:15-17:00

One of the most important stages in diagnosis and management of endodontic problems is radiographic examination. However, conventional radiographic techniques have certain limitations.

This lecture will review these limitations, and how cone beam computed tomography (CBCT) technology can be applied to overcome some of the shortcomings of conventional radiography to improve the management of complex endodontic problems.

The objectives of this presentation are to understand:

- the limitations of radiographs
- three-dimensional imaging (CBCT)
- applications of CBCT in Endodontics.

Friday - May 3

## Hani Ounsi

DCD, DESE, DEA, MSc, PhD

Assistant Professor, Department of Restorative and Esthetic Dentistry and Endodontics, Faculty of Dental Medicine, Lebanese University  
Visiting Professor, University of Siena

Lebanon



### Single-Instrument Endodontics? Really?

Hall C 17:00-17:30

The purpose of root canal treatment is to eliminate inflamed and/or infected tissues from the root canal system through changing the shape of the main root canal and applying a proper cleaning/disinfection protocol. Shaping is usually done through manual or engine-driven, stainless steel or nickel-titanium instrumentation in any possible combination. In an effort to simplify endodontic shaping, new instruments are regularly introduced in consistently shorter sequences, down to one instrument, and presented commercially by shedding light on features that are often exaggerated while occulting their shortcomings. This contributes to eclipse fundamental aspects of the shaping, and more importantly the cleaning procedure, that may lead to medium to short-term failure of the endodontic treatment.

Friday - May 3

## Sleiman Razzouk

DDS, MS, PhD

Adjunct Faculty, New York University College of Dentistry  
Private practice

USA



### Toward Precision Periodontal Therapy: Host Genome, Epigenome and Oral Microbiome Interactions

Hall D 09:00-09:45

Periodontal diseases are multidimensional and complex. Bacterial content is the initiator, but disease progression depends on genetic and environmental parameters related to the host. Although bone loss magnitude is the common resulting outcome, the biologic process likely represents a unique inflammatory response characteristic to every individual.

This presentation provides updated insights on the distinctiveness of inflammation per individual in terms of microbiome and genome specificity. Periodontists should be prepared to incorporate these parameters into their clinical interpretation to advance personalized medicine.

Friday - May 3

## Fatmé Mouchref Hamasni

DDS, CES, DSO

Assistant Professor, Department of Periodontology,  
Faculty of Dental Medicine, Lebanese University

Lebanon



### Periodontal and Peri-Implant Diseases and Conditions: Where Do We Stand in 2019?

Hall D 09:45-10:15

Periodontitis is characterized by non-reversible tissue destruction resulting in progressive attachment loss, eventually leading to tooth loss. It is estimated that severe periodontitis, which is the sixth most prevalent disease of mankind, affects 11% of the world population with prevalence increasing by age. On the other hand, in daily practice, osseointegrated dental implants have become a popular modality of treatment for the replacement of lost teeth. When used to support various types of dental prostheses, functional implants become subject to variable complications which may disrupt the host response at the implant-mucosa interface. Several classifications have been published in order to facilitate the diagnosis of different diseases and to help clinician performing an appropriate treatment approach.

The aim of this communication is to update knowledge related to different periodontal and peri-implant diseases based on the consensus of the World Workshop on the Classification of Periodontal and Peri-implant Diseases and Conditions, co-sponsored by the American Academy of Periodontology (AAP) and the European Federation of Periodontology (EFP), published in 2018.

Friday - May 3

## Johnny Nohra

DCD, MS

Senior Clinical Instructor, Department of  
Periodontology, Faculty of Dental Medicine,  
Saint-Joseph University

Lebanon



### Bone Augmentation from Simple to Complicated

Hall D 10:15-10:45

In the last two decades, there has been a paradigm shift in implant dentistry. Implant placement in « available bone » is no longer acceptable. Prosthetically driven implants with adequate soft and hard tissue support are a prerequisite for long term implant success.

In this presentation, an evidence-based overview of guided bone regeneration (GBR) cases from simple to complex will be presented.

Friday - May 3

## Alain Romanos

DMD, MS, FICD

Assistant Professor, Department of Periodontology,  
Faculty of Dental Medicine, Lebanese University  
Visiting Assistant Professor, University of Alabama,  
Birmingham, USA

Lebanon



### Hard Tissue Grafting Techniques for Esthetic Implant: When to Do What?

Hall D 11:15-11:45

Alveolar ridge resorption after tooth loss is a common phenomenon. It usually occurs the first 3 months and the resorption can go up to 50 % the first year. Other cases lost their front teeth at an early age and implant was not indicated before finishing their growth, so the loss of a tooth does not coincide with replacement by osseointegrated supported prosthesis and there is frequently a lag of months to years before an edentulous site presents for therapy.

This often calls for augmentation procedures to increase the height and width of the existing bone to facilitate dental implant placement and restoration. Multiple soft and hard tissue grafting techniques will be described before or at time of implant placement.

Friday - May 3

## Elie Azar El Maalouf

DDS, CES, DSO

Assistant Professor, Department of Periodontology,  
Faculty of Dental Medicine, Lebanese University

Lebanon



### 3D Reconstruction of Horizontal Ridge Deficiency: Techniques and Approaches

Hall D 11:45-12:15

Following tooth extraction, trauma, periodontal/endodontic disease, most patients present with tissue deficiencies.

Tissue deficiencies include deficits of soft tissue (alveolar mucosa) and/or hard tissue (alveolar bone). Alveolar ridge defects can be categorized as horizontal, vertical and combination defects. Without careful consideration and proper treatment planning, hard and/or soft tissue defects may lead to functional, structural, or esthetic compromises in the final prosthesis. With different ridge augmentation techniques, can we prevent these esthetic and functional complications?

In this presentation, we will present a clinically relevant implant-driven classification of the alveolar ridge width, with the goal to help clinicians to choose the proper ridge augmentation technique.

Treatment management strategies of the horizontally collapsed ridges, especially the ridge-split approach, will be discussed using well supported references and clinical examples of treated cases. Comparison and advantages of different techniques will be presented.

Friday - May 3

## Bilal Omarjee

DDS, DES DIU, DU, EA

Private Practice

France



### Vertical and Main Horizontal Ridge Augmentation: Which Biomaterials in 2019?

Hall D 12:15-13:00

Advanced ridge horizontal more than 4 mm, as well as vertical increases remain a challenge in pre-implant surgery.

Faced with the different techniques and the plethora of biomaterials in pre-implant surgery, the surgeon must follow decision-making pathways.

This reasoned choice of the biomaterial will allow the surgeon to push the limits of the guided bone regeneration. Nowadays, slowly resorbable cortical membrane, known as Lamina, in formwork techniques will allow us augmentations so far only possible with autogenous bone.

Friday - May 3

## Hien Chi Ngo

BDS, MDS, PhD, Grad Cert HEEd, FICD, FADI, FPFA

Professor and Dean, College of Dental Medicine, University of Sharjah

United Arab Emirates



### Restorative Challenges in Older Patients

Hall D 14:00-14:45

The retention of healthy teeth in the elderly contributes to overall physical and mental health and quality of life. There are specific issues that need to be considered when providing dental care for older patients. The incidence of general disease is higher in this population, as is the amount of prescribed medication. These can complicate dental management by altering salivary flow, causing bleeding disorders, lichenoids reactions and tissue overgrowth. Oral diseases are cumulative and become more complex to manage over time. In older individuals, conservative treatments should be considered first, as complex options such as implant-born structures could be more challenging to maintain as patients get older. In the natural course of ageing, individuals will transition from being robust (active and capable) to being frail (limited activity and capability) and finally being dependent (very limited activity and capability), the ability to cope with extensive treatment decreases with age and, in more severe cases, patients must be sedated for dental care.

In this presentation, I will address a structured approach to formulate a care plan for older individuals: identify the issues and possible solutions, protect the dentition and patient, control disease and maintain oral and general health.

#### Learning objectives:

- Understand the holistic approach in care planning for older individuals;
- Understand the challenges in managing oral health for life;
- Be familiar with preventive and restorative considerations in elderly patients.

Friday - May 3

## Jihad Dagher

BDS, DU, DESS, DSO

Lecturer, Department of Pediatric Dentistry and Dental Public Health, Faculty of Dental Medicine, Lebanese University

Lebanon



### Fundamentals Elements Needed to Prevent Infectious Agents in Dental Settings

Hall D 14:45-15:05

Infection continues to be one of the most critical issues in healthcare service worldwide. Infection prevention and control of cross-contamination are essential in providing a secure environment for patients and healthcare providers within healthcare settings in general and more specifically in dental practices.

Infection transmission during dental procedures may occur through direct contact with saliva, oral fluids or blood, airborne droplets containing infective agents, or indirect contact via contaminated objects (e.g., instruments, equipment, or environmental surfaces). Exposure to bloodborne pathogens like human immunodeficiency viruses (HIV) and hepatitis B and C viruses (HBV and HCV) is a constant risk and therefore high standard precautions must be implemented and followed for all patients attending dental clinics regardless of their infection status.

Friday - May 3

## Antoine Choufani

DCD, DESS, Cert PDH, DU

Chief of Clinical Services, Department of Pediatric Dentistry and Dental Public Health, Faculty of Dental Medicine, Lebanese University

Lebanon



### Prévention des Troubles Musculo-Squelettiques chez les Dentistes

Hall D 15:05-15:25

L'ergonomie est l'étude de la relation entre le travailleur et son travail dans tous ses aspects. Les traitements dentaires impliquent un travail de grande précision au niveau des membres supérieurs et présentent de nombreuses contraintes posturales. Si cette posture n'est pas correcte, elle peut très rapidement être à l'origine de troubles musculo-squelettiques. Ainsi, le praticien doit organiser son site de travail en accord avec les normes de l'ergonomie et en adoptant des postures correctes et adéquates. De même, le bon choix du fauteuil et du tabouret, ainsi que les autres éléments du cabinet, va aider dans l'application de ces normes.

Dans cette présentation, on va évoquer les problèmes de posture et leurs conséquences, de même que les règles générales de l'ergonomie au cabinet, pour en sortir avec des recommandations.

Friday - May 3

## Dany Daou

DCD, DES, MS

Assistant Chief of Clinical Services, Department of Pediatric Dentistry and Dental Public Health, Faculty of Dental Medicine, Lebanese University

Lebanon



### School-Based Dental Sealant Program

Hall D 15:55-16:15

Data from the WHO Global Oral Data Bank indicate that dental caries index among Lebanese children has worsened over the last decades. Although chronic diseases are among the most common and costly of all health problems, they are also among the most preventable. The children who are most at risk for dental diseases are those who are least likely to see a dentist. Moreover, the children who are of low-income status are in greatest need of community based preventive interventions.

The lack of access to preventive dental services, such as dental sealants, can be a major barrier to optimal dental health. School-based dental sealant programs are an important and effective public health approach in promoting the oral health of children and adolescents.

The Faculty of Dental Medicine at the Lebanese University, the NGO Ajialouna and in collaboration with the Ministry of Education implemented a school-based dental sealant program from 2010 to 2017 in order to reach children from low-income families who are less likely to receive private dental care. The program targeted higher risk public schools in Beirut in order to reach higher risk children in a practical and effective approach for increasing sealant prevalence among this population. In this program, around 1450 children benefited from more than 5000 sealants.

This presentation will describe the school-based dental sealant project outlining the various results and recommendations.

Friday - May 3

## Mohamad Machmouchi

DDS, MSc

Instructor, Department of Pediatric Dentistry and Dental Public Health, Faculty of Dental Medicine, Lebanese University

Lebanon



### The Upstream-Downstream Concept in Oral Health

Hall D 16:15-16:35

Dental caries continues to pose an important public health problem across the world. According to the World Health Organization, dental caries affects about 60-90% of schoolchildren, the vast majority of adults and contributes to an extensive loss of natural teeth in older people globally.

High-quality appropriate dental care should encompass the concepts of effectiveness and efficiency. Many dental procedures are ineffective, and some preventive measures are inefficient. A common criterion on first dental intervention is essential to use before carrying out any clinical procedure. Applying the criteria will lead to minimal intervention and therefore unnecessary dental treatment will be reduced.

In this lecture, the Upstream-Downstream concept will be discussed as well as basic issues in Dental Public health.

Friday - May 3



## Sawsan Nasreddine

BDS, DU

Chief of Clinical Services, Department of Pediatric Dentistry and Dental Public Health, Faculty of Dental Medicine, Lebanese University

Lebanon

### Silver Diamine Fluoride: A New Public Health Measure in Preventing Dental Caries

Hall D 16:35-16:55

Silver diamine fluoride (SDF) has been used worldwide since 1970 to arrest caries. In 2014, the SDF received FDA clearance as a desensitizing agent in the United States and in 2016 it was recognized by Food and Drug Administration with breakthrough therapy designation for caries treatment.

SDF is a bactericidal agent and reduces the growth of cariogenic bacteria. It inhibits demineralization and promotes the remineralization of enamel and dentine. It also delays degradation of the dentine collagen.

This presentation will discuss current evidence on the efficacy of silver diamine fluoride for arresting caries and prevention. Dentists should be encouraged to use it into their daily practice. In addition, since SDF is inexpensive and can easily be applied in field settings, it should be considered as a new tool to be used in Dental Public Health programs.

## Ambrose Chan

Dr PhD, BDS Hon, G Dip Clin Dent, MScDent, FRACDS, FICD

Honorary Assistant Professor, Faculty of Dentistry, University of Hong Kong  
Honorary Research Affiliate, Faculty of Dentistry, University of Sydney  
Radiation Safety Officer, Queensland Health, Australia

Australia



### Pre-Emptive Dental Anaesthesia By Nd:Yag Photobiomodulation- Part II

Cedars Hall 09:15-10:00

Due to the invasive and often painful nature of conventional dental procedures, pre-emptive anaesthesia with injectable local anaesthesia (LA) is routinely used for pain management. Fears of pain and needle injection are associated with aversive experiences, leading to poor oral health and increasing dental avoidance. There is a growing demand for a non-drug, non-invasive and anxiety-free alternative, particularly in young patients and those medically-compromised patients who are on regular poly-medication. The clinical use of Photobiomodulation delivered by Nd:YAG photons emerges as a holistic alternative for pre-emptive dental anaesthesia, including its effectiveness, safety and possible mechanism of actions will be discussed.

## Roeland De Moor

MSc

Professor, Ghent University

Belgium



### Lasers in Endodontics for Root Canal Cleaning and Disinfection- a Critical Appraisal

Cedars Hall 10:00-10:45

The clinical application of lasers in endodontics started in the late 90s. In that period, delivering the laser light up to the radicular apex, conventionally one millimetre from the anatomic apex, required the use of fibres or tips with a thin (narrow) diameter (generally 200-300 microns) that were flexible and resistant to negotiate the anatomical curvatures of dental roots with minimal risk of breakage. This approach required helical (circular or spiral) movement of the fibre, in order to increase the irradiation angle between laser fibre and dentin surface, trying to improve the angle (directionality) and energy diffusion. This technique is suitable for most wavelengths used in dentistry in the visible (532nm / KTP), in the near-infrared (from 810 to 1340 nm / Diodes - Nd:YAG - Nd:YAP), and medium-infrared (2780 nm / Er,Cr:YSGG and 2940 nm / Er:YAG) electromagnetic spectrum. This technique is what we call "conventional laser endodontics": the spiral motion of a laser fibre in a dried canal.

Almost ten years later the activation of irrigation solutions with Erbium lasers was introduced. This was the beginning of the era of "laser activated irrigation" (LAI), with a fibre in the irrigation solution and inducing fluid streaming based on the creation of cavitation bubbles. Also here there was a rapid evolution. At present two approaches are possible i.e. (1) conventional LAI (with the fibre still in the root canal lumen) and (2) the PIPS approach with the fibre in the pulp chamber activating the irrigation solution in the root canal.

The aim of this presentation is (1) to clarify the difference in laser-target interaction of these techniques as all approaches are temperature driven, (2) to evaluate the value-added cleaning and disinfection of the 3 different approaches, (3) to highlight how laser use, though depending on the wavelength, can make the difference with the current non-laser based cleaning and disinfection protocols and finally (4) may satisfy the needs of modern endodontics.

## Aldo Brugnera Junior

DDS, MS, PhD

Associate Researcher, National Institute of Science and Technology (INCT) - Basic Optics and Applied to Life Sciences- IFSC, University of Sao Paulo

Brazil



### Er:YAG laser: Innovation in Clinical Use Based Upon Scientific Evidence. Clinical Cases

Cedars Hall 10:45-11:30

The objective of this presentation is to demonstrate innovative uses of the new Er YAG laser, which are the removal of veneer (laminates), inlay and onlay. Treatments with Er:YAG laser and its advantages in clinical treatments are well known and have been widely approached in literature. The studies by Morford et al were designed to systematically investigate the efficacy of Er:YAG laser on veneer debonding, possibly without damaging the underlying tooth and preserving veneer integrity. While the veneer materials did not show any characteristic water absorption bands in the FTIR, the bonding cement showed a broad H<sub>2</sub>O/OH absorption band. Veneers transmitted between 11.5% and 43.7% of the incident Er:YAG energy with Emax transmitting twice the energy as EE at comparable thicknesses. Laminates for removal have been complicated in aesthetic odontology due to the complexity of the process with conventional high speed system. A major difficulty has been working time and eventual damage to dental structure. In addition, as lighter porcelain became available, a growing number of patients is requesting to replace their old facets. The laser used in these 3 clinical cases was Laser Lite Touch, MMO optics, Brazil, with the following parameters: Energy densidade/ Frequency 150mJ/40Hz to 200mJ/40Hz; Pulse Energy per pulse 6.00W /8.00W; AS7066 tip; Water level 5. Laminates removal was very fast, around 3.08 min per laminate, with no damage to remaining tissue surface, no pain or sensitivity, no trauma as there was no vibration and comfort to the patient.

## Samir Nammour

DDS, MSc, PhD, Agr.

Professor, Department of Dental Sciences, Faculty of Medicine, University of Liege  
General Director, European Master: "Oral Laser Applications" (EMDOLA)  
Chairman, International relations and legal affairs, World Federation for Laser Dentistry (WFLD)  
Belgium



### Use of Laser in Dental Prosthetic Surgery

Cedars Hall 11:45-12:30

The use of laser beam in oral surgery has several advantages: bloodless surgery, no scar formation, no need for suture, immediate decontamination of the surgical site, good visibility of the surgery field, fast work, positive psychological impact on patients, etc.

The use of laser in prosthetic surgery is helpful. The no need for suturing avoids anatomical distortions of surgical sites. The low inflammatory reaction reduces the post-surgical discomforts and patient complaints. Several clinical cases (prosthetic fibroma, floated ridge, vestibular lengthening ...) will be showed and discussed step by step. The beam diameter is 0.1 mm, which allows high precision during the dissection of oral tissues.

Friday - May 3

## Samir Nammour

DDS, MSc, PhD, Agr.

Professor, Department of Dental Sciences, Faculty of Medicine, University of Liege  
General Director, European Master: "Oral Laser Applications" (EMDOLA)  
Chairman, International relations and legal affairs, World Federation for Laser Dentistry (WFLD)  
Belgium



### Live transmission

Cedars Hall 12:30-13:15

Friday - May 3

## Jamil Shibli

DDS, Ms, PhD

Professor, Department of Periodontology and Oral Implantology, University of Guarulhos, São Paulo

Brazil



### Treatment of Peri-implantitis Using Lasers: Current Clinical Approach

Cedars Hall 14:15-14:45

Peri-implantitis is an infectious disease that causes bone loss and if not treated could lead to the loss of the implant-supported restoration. The etiology of peri-implantitis is associated with a complex bacterial biofilm and systemic and local risk factors might increase the severity of the peri-implant tissues destruction.

Intriguingly, there is no specific and predictable treatment for peri-implantitis, although several surgical and non-surgical therapeutic strategies have been proposed to manage this complex-multifactorial disease. These strategies to treat peri-implantitis can be divided in anti-infective and regenerative techniques, however, the removal of the contaminants and hard deposits at implant surface alter the implant surface topography as well as the oxide layer avoiding peri-implant bone regeneration and consequently the new bone reformation.

Physical methods using lasers have been employed in both anti-infective and detoxification methods in the last decades. Sterilization and cleaning/decontamination of dental implant surfaces by means of high and low-intensity laser therapy using Er:Cr:YSGG and Er:YAG have been also employed. Laser irradiation removes not only the inflammatory soft tissue present around the peri-implant pocket but also detoxify the implant surface without damage or even alter the titanium surface neither dental implant morphology allowing a better stabilization of the blood clot with or without adding some bone graft materials during the guided bone regeneration (GBR). In addition, photobiomodulation produced as secondary effect following Er:YAG laser therapy positively modulates wound healing. This effect is caused by promotion of cell proliferation and differentiation, as well as anti-inflammatory effects playing a pivotal impact on peri-implant tissues.

The present conference will focus on the treatment of peri-implantitis using Er:YAG laser as well as the effect on the bacterial etiology. In addition, treatment of soft and hard periodontal tissues will also be discussed during the presentation.

Friday - May 3

## Umberto Romeo

DDS

Associate Professor, Sapienza University, Rome

Italy



### Laser in the Treatment of Soft Tissue Diseases of the Oral Cavity: Advantages and Limit

Cedars Hall 14:45-15:30

The oral soft tissue lesions could be divided in surface and exophytic lesions. The surface lesions of oral mucosa consist of lesions that involve the epithelium and/or superficial connective tissue; generally they do not exceed 2-3 mm in thickness. Clinically, surface lesions are flat or slightly thickened and white, pigmented or with vesicular-ulcerated-erythematous. On the other side, the exophytic oral lesions are characterized as pathologic growths projecting above the normal contours of the oral mucosa. There are several underlying mechanisms responsible for oral exophytic lesions such as hypertrophy, hyperplasia, neoplasia, and pooling of the fluid. Both superficial and exophytic lesions are sometimes difficult to deal with clinically.

Through the clinical presentations of several cases, the advantages and the limit to approach them with different laser wavelengths will be described.

Friday - May 3

## Karim Corbani

DCD, DESE

Senior Lecturer, Department of Restorative and Esthetic Dentistry, Saint-Joseph University of Beirut

Lebanon



### Integrating Laser Technology into Esthetic Dentistry: from Myths to Clinical Reality

Cedars Hall 15:30-16:00

The field of esthetic dentistry has substantially expanded over the last two decades in an effort to keep pace with patients' demands driven by the "social esthetic trend". New materials and technologies were introduced in order to improve the efficiency, predictability and esthetic outcome for both patients and clinicians.

Laser technology has become increasingly utilized in clinical dentistry; initially introduced as an alternative to the traditional halogen curing light, the laser now has become the instrument of choice, in many applications, and integrated in esthetic treatment plan as a key for success. Several lasers machines with different wavelengths (semiconductor diode laser, CO2 laser and Nd:YAG laser) were introduced on the market for soft tissue applications: gingival depigmentation, gingival recontouring, periodontal treatment, frenectomy...; laser expanded opportunities to cut and remove hard tissue (especially with the Erbium-YAG laser) including enamel, dentin, caries, and osseous tissues. The Erbium is also excellent as a soft tissue laser. Pain free cavity preparation was introduced using this technology, used also in the daily restorative treatment in removing cemented veneers, etching and cleaning.

This lecture will address the advantages and limitations of laser technology integrated as a tool in esthetic dentistry practice, discussing clinical cases with an evidence-based background.

Friday - May 3

## Fatima Zanin

DDS, MS, PhD

Private Practice

Brazil



### Dental Bleaching Using Violet Light: The Great Leap as New Perspective for Aesthetic Dentistry

Cedars Hall 16:30-17:00

**Background.** Dental bleaching, a non-invasive technique, is currently part of overall dental treatments and highly associated with the patient's expectations to improve dental aesthetics. The color of the teeth is a relevant factor in dental aesthetics and the most common method is the use of chemical agents (with and without light), that break down pigments, giving the teeth a lighter shade. In 2018, Brugnera et al studied the efficiency of photoactivation of a violet LEDs system, 405-410nm during bleaching with 35% carbamide peroxide gel and its influence on postoperative sensitivity. Control group had bleaching performed with the same gel without the light, with equal times for the two techniques. Changes in teeth color (immediate, 7 days and 14 days after completion of bleaching), teeth sensitivity and satisfaction of participants regarding both techniques were evaluated. **Methods.** 50 participants were selected and randomly divided into a treatment group (n = 25): G1- Control Group: 35% Carbamide Peroxide gel, (2 sessions, 1 session/week); G2- Hybrid technique: Violet LEDs + application of 35% Carbamide Peroxide gel, (2 sessions, 1 session/week). The authors used Violet gel (Whiteform 35%- Formula & Ação, São Paulo -Brazil) and Leds System Bright Max Whitening (MM Optics, São Paulo, Brazil), wavelength ranging from  $\lambda$  405 to  $\lambda$  410nm with 4 super Leds (Light Emitting Diode) P=100mW each one Total Power = 400mW in order to illuminate all the vestibular surfaces of upper and lower jaws simultaneously, from molar to molar. Light activation: 1 minute on and 30 seconds off.

**Results.** G2: violet LED + 35% CP gel was more effective than G1 35% PC gel, at the same times applied in this study. The great leap of the use of Violet LEDs for bleaching is the possibility to perform dental bleaching with light and gel and only with light. This presentation will show clinical cases using both methods.

**Conclusion.** It is a new option in dental bleaching, without producing either heat or sensitivity, with comfort and safety for the patients and professionals.

Friday - May 3

## Paul Nahas

BDS, CES, DSO

Lecturer, Department of Restorative and Esthetic Dentistry and Endodontics, Faculty of Dental Medicine, Lebanese University

Lebanon



### Success of Bonding Composite to Laser-Treated Dentin

Cedars Hall 17:00-17:30

Conflicting and limited data is currently available relative to the bond strength of restorative materials to dentin prepared with various techniques. Laser parameters including laser type and energy levels have not been thoroughly investigated and dentists who are using lasers for cavity preparation are short of evidence-based protocols required to achieve satisfactory short- and long-term clinical outcomes of composite restorations.

The aims of this lecture are to 1- demonstrate the use of parameters of Erbium lasers that would yield to optimal bonding strength of composite and 2- prove the longevity of composite restoration when subjected to laboratory artificial aging.

Friday - May 3

## Marwan Hoteit

BDS, CES, DU, UDMR

Chief of Clinical Services, Department of Orthodontics and Dentofacial Orthopedics, Faculty of Dental Medicine, Lebanese University

Lebanon



### Effect of Different Er:YAG Etching Settings on Shear Bond Strength of Orthodontic Ceramic Brackets

Cedars Hall 17:00-17:30

Since the last few decades, there is growing interest in ceramic brackets especially in adults. Conventional etching produces demineralization of the superficial layer, and leads to high level of bond strength that can be related to both considerable patient discomfort and a high risk of enamel damage while debonding. With the introduction of Erbium lasers into the orthodontic field, Er:YAG laser showed an important advantage related to the ability to adjust its settings while etching. This would help reaching an adequate ceramic brackets shear bond strength while respecting the enamel integrity. Could Er:YAG laser be a viable alternative to phosphoric acid?

Friday - May 3

## Marc Semper

DDS

Private Practice

Germany



### How Does CBCT Work and Image Quality in CBCT

Chartouni Hall 10:00-13:00

## WORKSHOP RADIOLOGY

The technical, physical and mathematical principles of cone-beam computed-tomography will be explained briefly as well as image reconstruction and setting parameters for the diagnosis in dentomaxillofacial radiology.

Particular attention is paid to the artifacts related to this technology and strategies how to reduce their negative influence on the imaging process. Furthermore, justifications and obligations in the use of CBCT and aspects of radiation exposure will be summarized.

Case selective reconstruction modes, imaging modalities and potential applications are shown as well as clinical case studies with regard to diagnosis and treatment planning as well as fictitious therapy will be discussed.

Friday - May 3

## Jan Paulics

DDS

Private Practice

Sweden



### Implant Retained Digital Dentistry

Workshop Hall 1 11:00-13:30

## LIVE TRANSMISSION: PROSTHODONTICS

This is an intensive training program and will provide a practical insight into the most current digital techniques supporting full end to end workflows for implant retained restorations. The workflow including intraoral scanning, implant planning, CAD Design incorporating 3Shape Smile Design concept and manufacturing will be demonstrated in detail accompanied by practical hands-on workshops.

Hands-on workshops will cover the following exercises:

- Intraoral scanning and utilization of CT scan data
- Digital implant treatment planning
- Take the surgical guide from virtual design to 3D printed product
- Guided surgery protocols and model workshop.

Friday - May 3

**Bilal Omarjee**  
DDS, DES DIU, DU, EA

Private Practice

France



## Vertical and Main Horizontal Ridge Augmentation

Workshop Hall 2 15:00-18:00

### WORKSHOP PERIODONTOLOGY

Advanced ridge horizontal more than 4 mm, as well as vertical increases remain a challenge in pre-implant surgery.

Faced with the different techniques and the plethora of biomaterials in pre-implant surgery, the surgeon must follow decision-making pathways.

This reasoned choice of the biomaterial will allow the surgeon to push the limits of the guided bone regeneration. Nowadays, slowly resorbable cortical membrane, known as Lamina, in formwork techniques will allow us augmentations so far only possible with autogenous bone.

Friday - May 3

**Edgard Jabbour**  
BDS, DESS, MSc, DSO

Assistant Professor and Head, Department of Restorative/Esthetic Dentistry and Endodontics, Faculty of Dental Medicine, Lebanese University

Lebanon



**Edmond Koyess**  
DCD, CES, DSO

Assistant Professor, Department of Restorative and Esthetic Dentistry and Endodontics, Lebanese University, Faculty of Dental Medicine

Lebanon



## Endodontic Microsurgery: The Final Conquest

Phoenicia Hall 09:00-11:00

### LIVE TRANSMISSION: ENDODONTICS

The aim of endodontic treatment is to disinfect the pulp space (reducing the microbial load and removing necrotic tissue) followed by sealing the pulp canal system to prevent recontamination. However, infection remaining in the inaccessible apical areas, extraradicular infection including apically extruded dentin debris with bacteria present in dentinal tubules, bacterial biofilms, true radicular cysts, and foreign body reactions require surgical intervention. The main goal of root-end surgery is to prevent bacterial leakage from the root-canal system into the periradicular tissues by placing a tight root-end filling following root-end resection. Periapical microsurgery proved to be a successful final procedure in the resolution of these pathologies.

Friday - May 3



## Hani Tohmé

DCD, MSc, MRes

Senior Lecturer and Clinical Director, Department of Removable Prosthodontics, Faculty of Dental Medicine, Saint-Joseph University

Lebanon



## André Assaf

BDS, CES, DU, MBA, DUQAES

Head, Biomaterials and Technology Unit, Senior Lecturer, Department of Prosthodontics, Faculty of Dental Medicine, Lebanese University Associate Professor, Faculty of Dentistry, Beirut Arab University, Lebanon

Lebanon



## Wadih Nassif

BDS, CES, DSO

Head and Assistant Professor, Department of Prosthodontics, Faculty of Dental Medicine, Lebanese University

Lebanon



## Full Arch Guided Surgery with Immediate Temporary Restoration

Phoenicia Hall 14:00-17:00

### LIVE TRANSMISSION: IMPLANTOLOGY

Guided implant surgery entails many advantages to surgeons, prosthodontists and patients. It is based on a reverse implant planning that also allows the design of a surgical guide to be fabricated by a computer numerical controlled printing or milling. It is supported either by the remaining teeth, the ridge or by both. When properly planned and fabricated, it carries the additional advantages of a quick and precise implant placement, a flapless non traumatic procedure, and a possible immediate loading in case primary stability is achieved.

In this session, a fully edentulous patient is rehabilitated with six BLT implants from Straumann™. Six radiopaque markers were placed on the patient denture flange. A first CBCT is made for the patient while wearing his denture and a second one for the denture alone. This dual scanning technique is followed by the alignment of the 2 DICOM datasets for optimal selection of implant sites, orientation and size and the design of the surgical guide via the Implant Studio from 3Shape™. A guided flapless implant surgery is performed under local anesthesia. Finally, the denture is hollowed opposing the emergence areas of the implants provided with their temporary abutments. When total passivity is obtained at the correct interarch relationship, addition of self-cure acrylic resin is made to fill the holes and convert the removable prosthesis into a fixed implant-supported restoration. The denture is then devoid of its palate and flanges, the fitting surface made convex for better cleansability and occlusion adjusted.

## Shanon Patel

BDS, MSc, MClintDent, MRD, PhD, FDS, FHE

King's College London Dental Institute

United Kingdom



## External Cervical Resorption-Diagnosis and Treatment

Hall A 09:00-09:45

Over the last 2 decades External Cervical Resorption (ECR) has attracted increased interest, this in part due the improved radiographic detection with CBCT. The effective management of ECR depends on accurate diagnosis and assessment of the true nature and accessibility of ECR.

Using the latest evidence, the aim of this presentation is to:

- describe the clinical & radiographic features of ECR,
- explain the impact of CBCT in improving the accuracy of diagnosis,
- explain a clinically relevant new 3D classification of ECR,
- describe the management strategies for ECR.

## Frédéric Bukiet

DDS, MBD, MSc, PhD, HDR

Professor, Aix-Marseille University  
France



### Calcium Silicate-Based Root Canal Sealers for Obturation of the Root Canal Space: A Recent Approach Raising New Questions

Hall A 09:45-10:30

Several obturation techniques combining gutta-percha and a root canal sealer have been used to seal the root canal space including the single cone technique. This technique relies primarily on one gutta-percha cone and more emphasis is placed on the sealer which functions as a root canal filler. Among the available root filling techniques, single cone technique is often considered to be less technique-sensitive as well as cost-effective. However, a higher sealer volume inside the root canal space may negatively influence the seal as most available sealers tend to shrink upon setting. As a result, SCT combined with conventional sealers was deemed inappropriate, and it was recommended to maximize the gutta percha volume and minimize the sealer thickness. Recently, hydraulic calcium silicate-based sealers, also known as bioceramic root canal sealers, have been introduced. These sealers have good flowability and antimicrobial properties. The material itself is also hydrophilic, thus it can expand when contacting moisture, form a hydroxyapatite, and bond to dentin resulting in better sealing. Due to these improved properties, bioceramic root canal sealers have been recommended by the manufacturers to be incorporated in root canal obturation using a single cone technique. Given the increasing bioceramic root canal sealers release into the market, this lecture aims to examine the current knowledge and the clinical application of these materials for obturation of the root canal space.

Saturday - May 4

## Marc Semper

DDS

Private Practice

Germany



### The Influence of Cone Beam Computed Tomography in Clinical Decision Making

Hall A 10:30-11:15

In addition to the clinical examination, the evaluation of diagnostic imaging is the most important component of preoperative diagnostics in dentistry. This lecture describes the influence of cone beam computed tomography on decision making in treatment planning, particularly in endodontic treatment. The aim of this lecture is to provide the audience with a basic understanding of how cone beam computed tomography imaging may influence treatment planning by providing substantial additional informations over two dimensional imaging modalities. An overview of the current literature is presented and in selected cases the different diagnostic abilities of two- and three-dimensional modalities are portrayed.

Saturday - May 4

## Hien Chi Ngo

BDS, MDS, PhD, Grad Cert. HEEd, FICD, FADI, FPFA

Professor and Dean, College of Dental Medicine,  
University of Sharjah

United Arab Emirates



### Clinical Management of Dental Caries

Hall A 11:30-12:15

Dental practitioners believe in the prevention of dental disease and helping patients maintain a functional and aesthetic dentition for life, but how can we deliver predictable outcomes and make it a reality in clinical practice?

The modern approach to clinical dentistry relies on dentists taking the dual role of physician and surgeon. So there is a need for a systematic approach to the clinical management of a healthy oral environment. Patients present with a range of different conditions and circumstances and while no single intervention is effective in all cases, it is possible to develop specific strategies and protocols that incorporate monitoring of outcomes for managing individual patients.

Despite continuing major advances in dental materials and techniques, the average longevity of a direct tooth coloured restoration is still hovering around 10 years. Restorative materials are still poor substitute for natural tooth structure. Teeth can withstand high mastication load because they are built using two very different materials, so it has been suggested that we should also replicate this design when rebuilding a tooth.

Today, technological innovations have provided dental professionals with new tools and science has provided us with many possible ways of handling the above issues. This lecture aims at identifying important factors that govern clinical success, reviewing possible solutions and demonstrating practical ways at preserving and restoring tooth structure.

Topics covered will include:

- Minimal Intervention Dentistry – implementing strategies into clinical practice
- Aetiological factors linking caries, erosion and dentine hypersensitivity
- In-office and at-home care strategies, making them easy and predictable-

Saturday - May 4

## Patrizio Bortolus

Economics studies at University of Trieste, actually attending Executive MBA at MIB in Trieste  
CEO Saratoga Dental  
Italy



### Designing a New Workflow for Clinic Health Management

Hall A 12:15-13:00

Modern clinics are facing one of the biggest changes ever into dental field such as the introduction of digital scanners and an increasing patient awareness. Yet both workflow and ergonomics need to be redesigned to achieve the highest level of efficiency and protection from cross contamination. Moreover, a new way of collaborating between dentists and nurses can bring any clinic to maximize their performances either in terms of quality being delivered to patients, safety for everybody or productivity.

Some of the most common challenges faced by dental offices are:

- Supply management and inventory
- Standardized Systems for Delivery
- Staff motivation and training
- Technology Integration.

This lecture offers a variety of real-world solutions geared at streamlining organization and removing the bottle-necks that slow production, create stress and impact performance.

During this course you will learn:

- The importance of addressing ergonomics, hygiene and organization from a different perspective
- A step-by-step protocol to redesign your clinic workflow
- How to increase ergonomics and productivity.

Saturday - May 4

## Naji Abou Chebel

MD, MSc

Assistant Professor, Department of Oral and Maxillofacial Surgery, Faculty of Dental Medicine, Lebanese University  
Assistant Professor, Department of ENT Head and Neck surgery, Lebanese American University  
Clinical Associate, Department of Otorhinolaryngology-Head and Neck Surgery, AUBMC  
Lebanon



### 3D Virtual Surgical Planning in Maxillofacial Surgery

Hall B 10:30-11:00

3D virtual surgical planning is the new gold standard in the preparation for orthognathic surgery, especially in asymmetries. This technology has proven beneficial in many other indications.

During this presentation, we will discuss the benefits of virtual planning in orthognathic, traumatology, oncology, reconstruction and craniofacial surgery.

Saturday - May 4

## Wahid Terro

MD, MSc, OMFS, MScD, MIADR, MIAOMFS

Tutor, Department of Oral and Maxillofacial Surgery, Faculty of Dentistry, Beirut Arab University  
Chief of Clinical Services, Department of Oral and Maxillofacial Surgery, Faculty of Dental Medicine, Lebanese University

Lebanon



### Maxillofacial Trauma

Hall B 11:00-11:30

Oral and Maxillofacial trauma may involve injuries to the soft and hard tissues of the face such as lacerations and fractures of the jaw bones.

In adults, facial trauma is usually more severe, caused by traffic or sports accidents or physical attack and involve the upper, mid and lower part of the face. The most frequent facial trauma are usually jaw fractures, cheekbone, orbital bones, and injuries to the skin. These cases may present isolated or panfacial trauma. In this lecture, reported cases of isolated and panfacial traumas will be demonstrated and discussed.

Learning objectives:

- 1- Better understanding of oral and maxillofacial trauma,
- 2- Understanding the basic principles of fracture treatment.

Saturday - May 4

## Georges Abi Khalil

Dip Stomatol, PhD

Department of Oral and Maxillofacial Surgery,  
Faculty of Dental Medicine, Lebanese University

Lebanon



### Management and Surgical Repair of Condylar Fracture

Hall B 11:30-12:00

Mandibular condylar fractures occur in about a third of mandibular fractures and treatment options include surgical and non-surgical approaches for unilateral and bilateral condylar fractures in patients of many age or gender. Surgical repair of a condylar fracture must follow 3 rules - precise reduction, reliable fixation and minimal damage. Different surgical approaches are shown in this presentation the retromandibular and the preauricular being the most common ones.

Saturday - May 4

## Said Halabi

DU, DIS, FICD

Department of Oral and Maxillofacial Surgery,  
Faculty of Dental Medicine, Lebanese University

Lebanon



### Facial Complex Trauma

Hall B 12:00-12:30

During his professional trail, maxillofacial surgeons face multiple cases of trauma, varied from simple to complex even life-threatening conditions.

In this presentation, different serious facial trauma cases will be shown and discussed:

- Brain exposure due to the injury of the upper face using the coronal flap to make access for more advanced hard and soft tissue reconstruction.
- Bilateral mandibular parasymphysial fracture resulting in lethal condition due to tongue relapse.
- Compound-comminuted facial fracture with a complex repair using plates and screws.

Saturday - May 4

## José Johann Chidiac

DSO, DCD, MSc, Cert OFP, AEFM

Professor, Department of Prosthodontics, Faculty of Dental Medicine, Lebanese University

Lebanon



### Chronic Pain Management: Where is the Difficulty?

Hall C 10:30-11:00

Chronic pain is often defined as any pain lasting more than 12 weeks. Changes happen in the affected part of the body, in the nervous system and in everyday life activities. The difficulty lies in the fact that it is variable according to ethnic, cultural, gender and genetic differences. Treatments include multiple possibilities starting by pharmacological, non-pharmacological, behavioural, psychological and various other techniques.

This presentation is an overview of chronic pain management in relation to all these factors trying to define the role of the dentist in supporting suffering patients.

Saturday - May 4

## Antoon De Laat

DDS, PhD

Professor, Department of Oral Health Sciences, Catholic University, Leuven

Belgium



### Typical and Atypical Facial Pain

Hall C 11:00-11:45

Traditionally, dentists were highly trained for the diagnosis and management of acute pain and its intraoral causes. However, several kinds of pain in and around the oral cavity can interfere with a clear diagnosis of dental or periodontal pain. Consequently, dentists should be trained in differentially diagnosing pain that may mimic dental pain, or occur in the same region.

As a typical example, temporomandibular disorders with their myogenous or arthrogenous pain, are considered the responsibility of the dentist. Happily, over the last decades an impressive progress has been made in formulating Research and Clinical Criteria for a reliable diagnosis of musculoskeletal pain of the masticatory system, as well as its evidence-based management. Sometimes muscle and joint pain of the jaw system constitute part of a more generalized musculoskeletal condition that needs to be managed in cooperation with other disciplines.

Another important differential diagnosis with toothache and dental pain, is the group of neuralgia's and neuropathic pain syndromes. Here patients may present first to the dentist and it is crucial to orientate them correctly from the start. Regarding trigeminal neuropathic pains, new developments have necessitated more focused attention: e.g. the underlying pathophysiology of glossodynia/burning mouth syndrome tends to be neuropathic. In addition, potentially as a result of increased alveolar implant-surgery, post-traumatic trigeminal neuropathy presents more frequently and these difficult chronic pains need an appropriate approach.

The current presentation will try to bring an update on some aspects of the abovementioned topics.

Saturday - May 4

## Giovanni Mauro

MD, DDS, MSc

Professor, University of Parma

Italy



### Risks and Pitfalls when Using Botox for Pain Patients

Hall C 11:45-12:30

Botox has a large margin of safety. In therapeutic applications, complications are mostly local and relatively mild. Nevertheless, being a potent neurotoxin, side effects, risks and pitfalls must be considered in its clinical use. The lecture will present an overview of the biochemistry of the toxin and a discussion about possible risks linked with the use of botulinum for pain patients. Immunogenicity, allergy, local and systemic side effects will be discussed, and clinical indications to avoid some pitfall will be suggested.

## Carlos Khoury

DDS, MS

Lecturer, Department of Oral and Maxillofacial Surgery,  
Faculty of Dental Medicine, Lebanese University.

Lebanon



## Roger El Bassit

DDS, MS

Lecturer, Department of Oral and Maxillofacial Surgery,  
Faculty of Dental Medicine, Lebanese University.

Lebanon



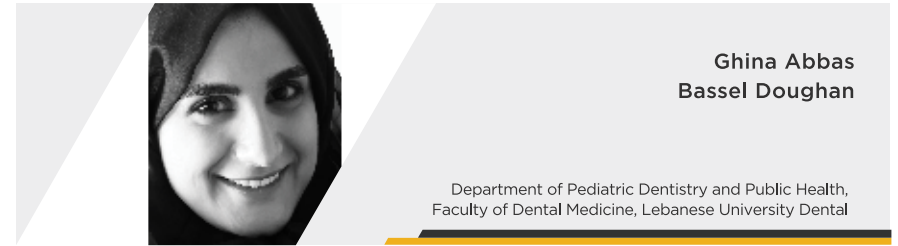### Soft Tissue Management Around Implants

Phoenicia Hall 09:30-12:30

### LIVE TRANSMISSION: ORAL SURGERY

Implantology has been in recent decade the miracle treatment of dentistry. But this treatment is not without certain complications. In fact, pathologies Such as peri-implantitis, recessions (in the case of a fine biotype around the implants, etc..) become more and more common as we move forward in time. However, these complications can be significantly limited by preventive treatments namely a good positioning of the implant during surgery, good prosthetic fulfilment, good hygiene... as well as a protective thick biotype. There are various processes of soft tissue management techniques around implants including free gingival graft, Edlan Mejchar, palatal flap, pedicle connective tissue graft, etc... We are going to perform a live surgery of one of these processes in an effort to help limit subsequent complications.

# Scientific Posters



## Prevalence of Dental Trauma in Special Needs Children

Special health care needs are defined by the American Academy of Pediatric Dentistry (AAPD) as “any physical, developmental, mental, sensory, behavioral, cognitive, or emotional impairment or limiting condition that requires medical management, healthcare intervention, and/or use of specialized services or programs. The prevalence of traumatic injuries in children with disabilities occurs more frequently than in healthy children. These individuals are at higher risk of traumatic dental injuries (TDI), which may be related to the nature of the medical condition. It is hoped that, from the best knowledge of the distribution of the problem in this population, it will be possible to elaborate educational and clinical strategies to prevent its occurrence. Prevention of traumatic dental injuries will be possible only if it is based on reliable data relating to its prevalence, causes and risk factors.

An observational cross-sectional study was conducted at Al Hadi institute for disabled children between April 2017 and June 2018. The sample consisted of 624 children aged 3-23 years. Dental trauma conditions were assessed according to World Health Organization (Oral Health Assessment Form for Children 2013). The objective of this study was to assess TDI prevalence among children with hearing loss, vision disability, autism, mental handicapped and educational difficulties.





Anas Abdo<sup>1,2</sup>  
 Chirstian Makary<sup>1</sup>  
 Frédéric Cuisinier<sup>3</sup>  
 Mirza Allaf<sup>2</sup>

<sup>1</sup>Faculty of Dental Medicine, Saint-Joseph University  
<sup>2</sup>Damascus University, Syria  
<sup>3</sup>Montpellier University, France

### Clinical Efficacy of the Immediate Implant loading in the Aesthetic Zone (Randomized Clinical Trial)

**Aim.** Evaluation of the clinical efficacy and in vitro assessment (bone resorption, color stability, patient satisfaction, marginal fit, surface topography) of two types of provisional restorations used in immediate implant loading.

**Materials and methods.** A randomized clinical trial was conducted on 20 immediate dental implants, divided in 2 groups: 10 with Direct and 10 with Indirect provisional restorations. Forty in vitro crowns and 40 in vitro discs were used to measure marginal fit, surface topography and color stability. Bone resorption was measured on CBCT radiographs and color stability was evaluated by Vita Easy Shade after soaking the crowns and discs in staining solution (tea) for four intervals. In addition, surface roughness was assessed using the RT200 device and Microtopography test in Montpellier- France. Marginal Fit was assessed by both Nano CT and Cement replica technique. Selective SEM was also done for some random selected samples.

**Results.** Vertical bone resorption was on average 0.7 mm for the direct and 0.1 mm for the indirect restorations ( $p < 0.05$ ). In vitro measures for color stability (E= Indirect: 1st interval=4.5, 2nd interval= 6.6, 3rd interval= 8.3, Direct 1st interval=6, 2nd interval=8, 3rd interval= 13), surface roughness (Direct Ra =0.067Q, Indirect Ra = 0.250 Q), marginal gape with Cement Replica: Direct=146Q, Indirect =152Q NanoCT marginal gape: Direct=135Q, Indirect =125Q) with all significant between both groups ( $P < 0.05$ ).



Nancy Abdo<sup>1</sup>  
 Anthony Macari<sup>1</sup>  
 Lara Nasreddine<sup>2</sup>  
 Joseph Ghafari<sup>1</sup>

<sup>1</sup>Division of Orthodontics and Dentofacial Orthopedics,  
 American University of Beirut  
<sup>2</sup>Department of Nutrition and Food Sciences,  
 Faculty of Agriculture and Food Sciences, American University of Beirut

### Association Between Orthodontic Treatment and Dietary Intake in Adolescent Patients

**Background.** Orthodontic appliances (OA) are claimed to cause nutritional imbalances, and available literature includes short term assessment, with lack of original diet determination.

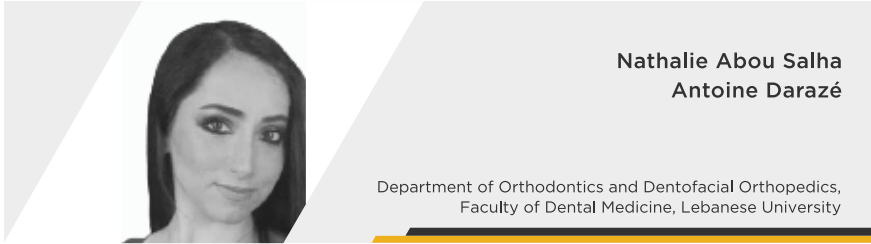**Aims.** Assess short and intermediate term effects of OA and generated pain on body mass index (BMI) and dietary intake, and the reported diet healthiness.

**Methods.** Patients were recruited before orthodontic treatment. BMI was calculated at baseline (B), 1 (M1) and 3 (M3) months. Dietary intake was evaluated through: 1- 24 hours recall at baseline and first week (W1); 2- Food Frequency Questionnaire (FFQ) at B, M1 and M3. Patients rated pain intensity on a visual analogue scale. Nutrients levels were compared to Acceptable Macronutrient Distribution Range (AMDR) and Adequate Intake (AI).

**Results.** BMI was unchanged during the study. Macronutrients changes: At W1: not significant. At M1: significant decrease ( $p < 0.01$ ) in carbohydrate, protein and fiber, with marginal decrease in fat ( $p = 0.058$ ) and obesity. At M3: despite slight increases, levels remained significantly lower relative to baseline measures ( $p \leq 0.01$ ) except for fat along with increase in obesity. The dietary intake reduction correlated negatively with pain ( $-0.3 \leq r \leq -0.5$ ) which decreased significantly between M1 and M3 ( $p < 0.001$ ).

Adolescents originally consumed a high fat diet (fat%=36.87 vs AMDR: 25-35), higher during treatment. However, fiber consumption was initially deficient (males: 31.57g/d vs AI: 38; females: 21.26g/d vs AI: 26) and further decreased after bracket placement.

**Conclusion.** The findings highlight the importance of dietary guidance on food selection before and during orthodontic treatment to prevent nutritional imbalances affecting adolescent growth and oral tissues health.



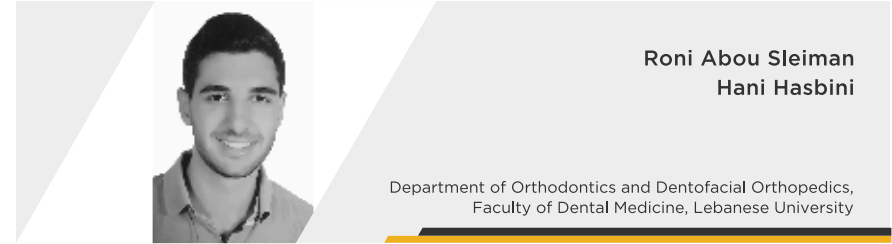## Cephalometric Assessment of Upper Airways among Different Facial Patterns in Lebanese Adults

**Introduction.** Cephalometric evaluation of upper airway space has long been an interest for orthodontists for its causal relationship with some particular craniofacial dysplasia and breathing disorders. Potential factors affecting upper airway dimensions include the facial pattern.

**Objective.** To test the null hypothesis that there is no significant variation in upper airway size among different facial patterns (hypodivergent, normodivergent and hyperdivergent) in Lebanese healthy adults, males and females.

**Materials and methods.** Lateral and frontal cephalograms were recruited from the orthodontic department at the Lebanese university. Subjects were classified into 6 groups based on their facial pattern and gender. The vertical classification was done using a rigorous selection of cephalometric parameters. Upper airway measurements were done at different levels of the pharyngeal space (nasopharynx, oropharynx, and hypopharynx).

**Clinical significance.** Assessing the upper airway dimensions in different vertical patterns is mandatory to avoid orthodontic interventions that could impede on the upper airway space, thus aggravate breathing disorders, especially in obstructive sleep apnea patients. This allows the establishment of individualized orthodontic treatment plan.



## Root Resorption: Is It Truly a Limitation for Orthodontic Treatment?

Root resorption is one of the major problems in dentistry and represent a risk that can affect the stability, longevity, and prognosis of the tooth involved. The causes and mechanisms leading to root resorption are often not clear and are generally said to be of multifactorial origin. Furthermore, displacement of teeth with pre-existing root resorption is riskfull and tend to be avoided by orthodontists. In this case report, we describe the dilemma of orthodontic treatment need for a patient who exhibited a severe generalized root resorption before initiating the orthodontic treatment and how it has been managed.



Abed Al Mowla Abu Merhi  
Kholoud Al Shahine  
Nour El Soussi  
Nahed Attia

Division of Periodontology, Faculty of Dentistry,  
Beirut Arab University

## Free Gingival Graft to Increase Keratinized Tissue in Apical to Gingival Recession – a Case Report

**Background.** Periodontal plastic surgery is the branch of periodontology that focuses mainly on correction or elimination of mucogingival problems linked with lack of attached gingiva, a shallow vestibule and aberrant frenum. Gingival augmentation procedures are indicated mainly to increase an insufficient amount of gingiva and sometimes to pause the progression of gingival recession.

**Aim.** 1- Increase zone of attached gingiva prior to coronally displaced flap as a first step in staged procedure to treat recession; 2- Evaluate changes in amount of keratinized tissue (KT) and in position of the gingival margin after free gingival graft procedure.

**Material and methods.** A patient with Miller class I gingival recession in anterior region was selected for treatment. Autogenous free gingival grafts harvested from the palatal mucosa used to gain the attached gingiva.

**Results.** Initial healing completed in 2 weeks without complication. Clinical variables, including recession depth, amount of KT, and probing depth (PD), were measured at baseline T(0), 3 month after surgery T(1), and analyzed. From T(0) to T(1), the gingival margin shifted coronally 0.6 mm, and KT increased 4 mm.

**Conclusion.** The augmentation of attached gingival tissue using the free gingival graft technique led to gain of attached gingiva in the treated region.



Ammar Alaraji  
Hala Ragab

Division of Operative and Esthetic Dentistry,  
Faculty of Dentistry, Beirut Arab University

## Color Change of Adhesive Resin Cements after Immersion in Three Different Staining Solutions

**Background.** Marginal discoloration of the luting cement may compromise esthetics.

**Objectives.** This study evaluated the color change of three adhesive resin cements after immersion in coffee, ketchup, Coca-Cola.

**Materials and methods.** Three-contemporary dual-cure resin cements of universal shade were tested (3M-RelyX-ultimate®, Bisco-eTheracel®, Tokuyama-ESTECM-plus®). The resin cements were placed in a customized Teflon mold (0.5mm-thick, 6mm-diameter). Mylar-strip was placed on the top surface of the mold to ensure smoothness. LED-light-curing unit (1000 mW/cm<sup>2</sup>) was applied for 15-seconds from both sides. The specimens were divided into 3-groups of 24-specimens from each material. Specimens were then subdivided based on the staining solution (n=8). Specimens were stored in the respective solutions and incubated in 37°C for 1-week before being subjected to color analysis. Color measurement was made on a white background using a spectrophotometer based on CIE-L\*a\*b\*. The color differences (E) was calculated and statistically analyzed using one-way ANOVA.

**Results.** interaction between variables was statistically significant. Regardless of the resin cement type, coffee revealed the highest statistically significant color change. Whereas Coca-Cola showed significantly the lowest color change. Comparison among the tested resin cements revealed significant color difference in coffee. However, no significance was found with ketchup and Coca-Cola.

**Conclusions:** within the limitations of this study, coffee was found to cause the most observable color shift in resin cements.

**Clinical relevance.** Precision in marginal preparation and restoration fit are important factors to protect the cement line and avoid marginal discoloration.



Doha Aldujeili<sup>1</sup>  
Mohamed Ali<sup>2</sup>  
Nayer Aboelsaad<sup>1</sup>

<sup>1</sup>Department of Restorative Sciences, Faculty of Dentistry,  
Beirut Arab University  
<sup>2</sup>Department of Oral Surgical Sciences, Faculty of Dentistry,  
Beirut Arab University

### The Clinical Efficiency of Herbal Gel in Treatment of Gingival Overgrowth and Teeth Sensitivity (Randomized clinical trial)

**Background.** The use of natural herbal products in dental care field continues to be popular and certain plants used in folk medicine serves as a source of therapeutic agent by having antimicrobial and other multi-potential effects. This clinical trial was aimed to evaluate the clinical effects of commercially available gel "Klirich Pro®" gel in the reduction of gingival inflammation and teeth sensitivity in patients with inflammatory gingival overgrowth.

**Methods.** 20 patients diagnosed with gingival hyperplasia were selected and randomly divided equally into two groups: Group A: placebo gel; Group B: Klirich Pro®. Clinical periodontal parameters included Plaque Index (PI), Gingival Index (GI), bleeding on probing index (BOP), probing pocket depth (PPD), and Gingival Overgrowth Index (GOI). Teeth sensitivity was evaluated by using tactile, air-blast, and thermal stimuli. The subject's response was recorded at baseline, one month and 3 months after the application.

**Results.** Klirich Pro® gel showed significant improvement in the investigated clinical parameters as compared to a placebo gel with no adverse reactions to the gel was reported. There was statistically significant difference between two groups at different time intervals.

**Conclusions.** The adjunct use of herbal product "klirich pro" gel may be useful as chemical plaque control agent combined with meticulous oral hygiene that can produce quicker and greater improvement in gingival health and reduction of teeth sensitivity with patients suffering from inflammatory gingival overgrowth.



Ammar Alwaely  
Hala Ragab

Department of Operative and Esthetic Dentistry,  
Faculty of Dentistry, Beirut Arab University

### Surface Roughness Evaluation of Nano Hybrid Composite after Polishing with their Associated Polishing Systems (In Vitro)

**Background.** Yielding the best polished surface on composite restoration is the ultimate goal for clinicians. The manufacturers of composite-resins tend to claim excellent polishing results with their associated polishing systems.

**Aim.** To evaluate surface roughness (Ra) of three-nanohybrid composite resins after they had been polished with their associated polishing system and other systems.

**Methods.** A total of 84-composite resin discs (10mm-diameter, 2mm-thick) were fabricated from three-nanohybrid composites, (FiltekZ250-XT, 3M/ESPE Ceram.x-one, Dentsply/Sirona; Tetric-N-ceram, Ivoclar/Vivadent). Three polishing systems were used (Sof-Lex-spiral-wheel 3M/ESPE; Enhance-PoGo Dentsply/Sirona; OptraPol Ivoclar/Vivadent). Specimens were assigned to four-groups, one per each polishing system and one as control (cured against Mylar-strip and not polished). Specimens were polished by the same operator following manufacturer's recommendations. Ra values were measured using a profilometer (DL SURF DR300). Statistical analysis was performed using three-way ANOVA and Tukey's test for individual comparisons between groups at ( $P \leq 0.05$ ).

**Results.** Statistically significant differences were found between the experimental groups ( $p < 0.005$ ). Sof-Lex spiral wheel polishing system created significantly the lowest (Ra) mean values with the associated composite of the same company as well as with the other two composites tested. The associated polishing systems didn't significantly improve the surface polish with the other two groups and their associated polishing system (Ceram.x-one & Pogo or Tetric-n-ceram & OptraPol).

**Conclusion.** Considering the limitations of this study, it is possible to state that Sof-Lex spiral wheels was the most efficient polishing system and resulted in high surface polish for all composite types tested. As such, it can be clinically recommended for any composite type.



Mirna Baalbaki  
Mounir Doumit

Department of Pediatric Dentistry and Dental Public Health,  
Faculty of Dental Medicine, Lebanese University

## Programme de Prévention pour les Enfants Ayant des Besoins Spéciaux

**Contexte.** Les enfants handicapés représentent une population à “besoins spécifiques” dont la prise en charge en odontologie soulève une problématique de santé publique. Ce poster décrit cette activité de prévention au sein d'un service d'Odontologie Pédiatrique et Communautaire à l'Université Libanaise pour mettre en évidence les difficultés rencontrées et proposer des programmes de prévention.

**Objectifs.** Une étude descriptive a été menée sur 200 enfants ayant des besoins spéciaux fréquentant l'école Al Hadi-Al Mabarrat, suivis dans le cadre du partenariat entre le service d'Odontologie Pédiatrique et Communautaire à l'Université Libanaise et la fondation. Les données collectées à l'aide de “fiches de suivi” renseignent sur l'indice CAOD, étant très élevé au temps zéro.

**Matériels et Méthodes.** Pour les 200 sujets, les séances ont suivi des consultations, des séances d'éducation sanitaire dentaire, des séances d'apprentissage au brossage, des séances de conseils diététiques, et des séances d'application du vernis fluoré. Le matériel utilisé s'est résumé à des compresses et du vernis fluoré (5% sodium fluoride). Les dents ont été nettoyées avec une compresses suivi d'une application de vernis.

**Résultats.** Selon les études précitées, ces même enfants traités avec du vernis fluoré auront une réduction de 40%-50% du taux de caries.



Annie Babakhanian  
Elie Haddad  
Hiba Tannous  
Joseph Ghafari

Division of Orthodontics and Dentofacial Orthopedics,  
American University of Beirut

## Genetics of Excessive Gingival Display

**Background.** Smile esthetics depends on the relations among three anatomic components: gingiva, teeth and lips. When the lip line is more than 2 or 3 mm above the maxillary anterior teeth, the smile is referred to as “gummy” smile and often as unattractive. The etiology of this condition is not properly established. Because it often accompanies the second most inherited facial condition, the “long face syndrome”, we hypothesized that the “gummy” smile may be an inherited characteristic, independent from the existence of this syndrome.

**Aim.** To assess the hereditary component of the gummy smile.

**Methods.** 20 families were recruited from the orthodontic clinics at AUBMC. The inclusion criteria were excessive gingival display, no prior treatment, and no craniofacial anomalies. The familial pedigree including 3 generations was established from a credible member of the family.

**Results.** Among the 20 families, 62 members (42 females and 20 males) were reported with a gummy smile. In 5 families, 4 or more relatives had excessive gingival display, 3 in 4 families, 2 in 8 families and 1 in 2 families. The long face syndrome (related to sustained mouth breathing since childhood) was found in a minority of the members.

**Conclusion.** Excessive gingival display during smile may be inherited. Epidemiologic and genetic studies are needed to identify the probability and mode of transmission.



Mohammad Hassan Bacho  
Balsam El Noueir

Department of Pediatric Dentistry and Dental Public Health,  
Faculty of Dental Medicine, Lebanese University



Carelle Badr<sup>1</sup>  
Carina Mehanna<sup>1</sup>  
Nadim Baba<sup>2</sup>  
Tatiana Zogheib<sup>1</sup>

<sup>1</sup>Department of Restorative and Esthetic Dentistry,  
Faculty of Dental Medicine, Saint-Joseph University

<sup>2</sup>Department of Restorative Dentistry,  
School of Dentistry, Loma Linda University

### Treatment of Non-vital Primary Molars Using Lesion Sterilization and Tissue Repair: A Case Series

**Aim.** The aim of this case series is to evaluate a non-traditional alternative treatment modality for treating non-vital primary molars which is lesion sterilization and tissue repair (LSTR) in place of traditional approaches such as pulpectomies or extractions with provision of a space maintainer. This report includes three clinical cases utilizing LSTR.

**Materials and methods.** An antibiotic mixture containing ciprofloxacin, metronidazole, and clindamycin along with a propylene glycol carrier vehicle and iodoform was introduced to the pulp chamber of non-vital primary molars after removing coronal pulp and enlarging the canal orifices without extirpation of any tissue from the root canals. The molars were then restored with stainless steel crowns after achieving a hermetic seal of the chamber. Follow-up is planned for four to six months consequent to LSTR treatment.

### A Prospective Study Comparing a Nanohybrid Composite Resin to a Flowable Composite Resin: Clinical Behavior

**Objective.** The aim of this prospective in vivo study was to compare the clinical behavior of a flowable composite resin (G-ænial Universal Flo, GC) and a nanohybrid universal composite resin (Tetric Evo Ceram, Ivoclar Vivadent) used in Class I and II direct esthetic restorations in posterior teeth, specifically to evaluate the effect of time on each of the products.

**Material and Methods.** A total of 108 Class I and II direct restorations were performed in patients aged between 20 and 60 years. The originality of this study lies in the fact that both materials were placed in pair, in the same clinical environment. The evaluations were performed at the moment of the restoration and then at 2-week and 3- and 6-months intervals by means of a clinical examination, clinical photographs, and radiologic examination, according to modified USPHS criteria. Statistical analysis was performed using the Fisher exact test and chi-square analysis.

**Results.** At baseline, the universal composite resin showed better esthetic properties. However, with time, its properties regressed significantly while the flowable composite resin kept certain stability.

**Conclusion.** Both flowable and nanohybrid composite resins exhibit acceptable clinical performance after 6 months of evaluation. The behavior of G-ænial Universal Flo was very acceptable and even better than Tetric Evo Ceram. G-ænial Universal Flo has almost the same or slightly less esthetic outcome than Tetric Evo Ceram. Further studies are needed to confirm or contradict those results.



Majed Bakleh  
Lynn Merkabaoui  
Nayer Aboelsaad

Department of Oral Surgical Sciences, Faculty of Dentistry,  
Beirut Arab University

### Diode Laser versus Scalpel in Treatment of Gingival Pigmentation: A Randomized Controlled Clinical Trial

**Background.** Dark intraoral gingival pigmentations play a negative role in a pleasing smile. As people nowadays are more concerned regarding their esthetics, several methods have been employed to manage including scalpel surgery, electrosurgery, bur abrasion and lasers.

**Aim.** The aim was to evaluate the clinical efficiency of diode laser in gingival depigmentation in comparison to the conventional scalpel technique. The clinical parameters included wound healing index, post-operative pain experienced, operation time, and bleeding intra/postoperatively.

**Materials and methods.** This study was conducted as a randomized controlled clinical trial using the split mouth design. It was performed on 15 patients diagnosed with bilateral melanin pigmentation in the anterior part of the upper mucosa that was scored using the Dummet Oral Pigmentation Index (DOPI). Patients voluntarily signed an informed consent. Pain experienced was recorded using the Visual Analog Scale (VAS). Bleeding and wound healing indexes were evaluated at 1 week, 1- and 3-months intervals.

**Results.** The statistical analysis showed that the parameters of experienced pain, and the bleeding index scores for laser showed significant difference ( $P < 0.05$ ) being a more comfortable procedure that is done with significantly reduced bleeding. However, the statistical analysis of the wound healing index only showed significant difference at one week, there was no significant statistical difference at 1 and 3-month follow-up.

**Conclusion.** Both lasers and scalpel surgery are both comparable in achieving pleasing esthetic results, however laser showed quicker postsurgical healing and reduced pain experience can that significantly improve the quality of dental treatment.



Jowelle Barakat Arairo  
Mounir Doumit

Department of Pediatric Dentistry and Dental Public Health,  
Faculty of Dental Medicine, Lebanese University

### Etude Descriptive des Enfants aux Besoins Particuliers qui se trouvent en Institut Al Hadi pour les Déficiences Visuelles et Auditives et les Troubles du Langage et de la Communication

L'état de santé bucco-dentaire chez l'enfant ayant des besoins particuliers est relativement peu documenté. Pourtant, aujourd'hui, plus de 95 millions d'enfants dans le monde sont porteurs d'un handicap. Au Liban, on estime que 10 à 15% de la population libanaise souffre d'un handicap physique, sensoriel, intellectuel ou mental, selon Les données les plus fiables disponibles.

L'institut al Hadi est dédié à l'accueil des enfants et adolescents, porteurs d'une déficience intellectuelle pouvant être associée à des troubles de la personnalité, à des troubles moteurs et/ou sensoriels mais aussi à des déficits graves de la communication.

Un bon état bucco-dentaire passe par une hygiène quotidienne et des contrôles professionnels réguliers, mais le manque d'autonomie de cette population entraîne une implication de tiers. C'est pourquoi nous avons cherché à évaluer la santé bucco-dentaire des enfants en institution en réalisant un dépistage dans l'Institut Al Hadi pour les déficiences visuelles et auditives et les troubles du langage et de la communication. Nous nous sommes ensuite intéressés au ressenti du personnel de soins à leur rôle dans la prise en charge de leurs pensionnaires. L'étude commence par une vue globale sur l'institut al Hadi montrant son rôle important dans la vie des handicapés. Par la suite, un portrait général de l'handicap chez l'enfant au Liban est développé, en exposant sa diversité et sa prise en charge ainsi ses conséquences sur la santé en général. Enfin les relations entre l'handicap et la santé bucco-dentaire sont analysées.



Fady Bou Chebel<sup>1</sup>  
Carina Mehanna Zogheib<sup>1</sup>  
Karim Corbani<sup>1</sup>  
Nadim Baba<sup>2</sup>

<sup>1</sup>Department of Restorative and Esthetic Dentistry,  
Faculty of Dental Medicine, Saint-Joseph University

<sup>2</sup>Department of Restorative Dentistry,  
School of Dentistry, Loma Linda University

### Clinical Comparative Evaluation of Nd:YAG Laser and a New Varnish Containing Casein Phosphopeptides-Amorphous Calcium Phosphate for the Treatment of Dentin Hypersensitivity: A Prospective Study

**Purpose.** To compare the effect of Nd:YAG laser to that of a new varnish: MI Varnish with RECALDENT (GC), for the treatment of dentin hypersensitivity, with a follow-up of 6 months. Dentinal hypersensitivity was evaluated using a new thermal test never before used on dental tissue.

**Materials and Methods.** A split-mouth design was used where teeth on one side received the same type of treatment. Twenty-seven teeth received the Nd:YAG laser treatment, the 27 contralateral teeth received MI Varnish. Five parameters were measured, and the measurements were taken before treatment at baseline, after 1 week, 1 month, 3 months, and 6 months of the application. Air stimulation to obtain the Schiff air score, the score of discomfort according to the visual analog scale (VAS), the tactile score, and the thermal test that determines the minimum cold-stimulating temperature and the maximum heat-stimulating temperature were all used to assess sensitivity. The significance level was set at  $p < 0.05$ .

**Results.** A clear decrease in dentin hypersensitivity for both treatments (Nd:YAG laser and MI Varnish) especially between baseline and 1 week, with maintenance of this state through the 6-month follow-up period. The difference between the two treatments was not significant, comparing, the Schiff air score, the thermal test, and the VAS; however, the tactile score was significantly improved 6 months after the application of MI Varnish compared to the laser ( $p = 0.05$ ).

**Conclusion.** No significant difference between the two treatments, Nd:YAG laser and MI Varnish. Both were effective and reduced dentin hypersensitivity immediately after treatment up to 6 months.



Reina Bou Farraa  
Sami Jade

Department of Oral and Maxillofacial Surgery,  
Faculty of Dental Medicine, Lebanese University

### Guided Bone Regeneration in Implant Surgery: Case Series

**Background.** Crestal bone resorption can occur after extraction. Therefore, guided bone regeneration (GBR) procedure is required to provide patients with successful treatment result regardless the presence of localized bone defects at implant sites. GBR is a surgical procedure that uses barrier membranes with or without particulate bone grafts or/and bone substitutes. There are two approaches of GBR in implant therapy: GBR at implant placement (simultaneous approach) and GBR before implant placement to increase the alveolar ridge or improve ridge morphology (staged approach).

**Material and Methods.** Three cases of GBR are described, in which three patients intended for implant placement presented with insufficient buccal bone after tooth extraction. Bone augmentation was necessary before implant placement in the recipient site. GBR was done for horizontal augmentation in a simultaneous approach, using allograft (Puros®) and xenograft (OCSB®), also in a staged approach, using allografts (Puros®), both covered by a resorbable collagen membrane. A period of four months was required before the placement of the implant in the staged approach using the allograft material.

**Results.** A good interpretation of the CBCT allowed to see the difference in crestal bone before and after GBR which demonstrates the indication of this procedure for a successful placement of the implant in all three dimensions with a good osseointegration and stability.

**Conclusion.** Guided bone regeneration can be attained with or without using bone materials and resorbable or non-resorbable barrier membranes techniques in 1-2 tooth deficiencies that may allow for dental restoration.





Stéphanie Bou Malhab  
Amale Mehanna

Department of Orthodontics and Dentofacial Orthopedics,  
Faculty of Dental Medicine, Saint-Joseph University

## La Perception de L'Esthétique Faciale par les Orthodontistes, Dentistes et Laypeople Suite au Traitement de Classe II Division 1

**Contexte.** Le traitement de la malocclusion de classe II à l'âge adulte varie entre un traitement orthodontique de camouflage nécessitant des extractions dentaires ou bien un traitement chirurgical.

**Objectif.** L'objectif de cette étude est d'analyser la perception des orthodontistes, dentistes et laypeople à l'altération du profil de deux individus : un homme et une femme à la suite d'un traitement d'une classe II division 1. Dans un second temps un objectif supplémentaire s'ajoute, celui de définir la manière par laquelle les orthodontistes agissent vis-à-vis d'un cas limite de classe II division 1.

**Matériel et méthodes.** Deux photos de profil d'un homme et d'une femme ayant une classe II division 1 ont été numériquement modifiées afin d'obtenir pour chaque patient une série de 7 photos : la photo initiale, 3 photos représentant le traitement de camouflage et 3 photos simulant le traitement chirurgical. 30 orthodontistes, 30 dentistes et 30 laypeople ont évalué ces photos.

**Résultats:** Les 3 groupes ont attribué les plus hautes notes aux cas traités chirurgicalement avec une avancée mandibulaire de 7 et 10 mm. La note la plus basse était celle de la photo de départ.

**Conclusion:** L'attractivité du profil est nettement supérieure dans les cas traités par chirurgie orthognatique. Pourtant, traiter un cas limite par des extractions dentaires reste plus favorable que de ne pas le traiter surtout chez les hommes.



Josephine Boueri<sup>1</sup>  
Ramzi Haddad<sup>1</sup>  
Naji Abou Chebel<sup>1,2</sup>

<sup>1</sup>Division of Orthodontics and Dentofacial Orthopedics,  
American University of Beirut

<sup>2</sup>Department of Oral and Maxillofacial Surgery,  
Faculty of Dental Medicine, Lebanese University

## Unilateral Sagittal Split Osteotomy: Effect on Mandibular Symmetry in the Treatment of Class III with Laterognathia

**Background.** While bilateral sagittal split osteotomy (BSSO) is the standard surgery to correct facial asymmetries, unilateral osteotomy (USSO) has been used in specific conditions.

**Aims:** 1-assess facial symmetry following USSO in Class III laterognathia; 2-compare treatment outcomes between USSO and BSSO.

**Methods.** (A)- Frontal facial photographs of four groups were assessed: 1-pre-surgical (n=30) with skeletal asymmetry; 2-post-surgical assessing patients of group 1 two years after USSO; 3-control (n=30) of patients judged to have harmonious facial norms; 4-mirrored images (n=30) in which the control photographs were altered by duplicating the right side half to replace the left half, creating perfectly symmetrical faces. All 120 photographs were evaluated by 40 expert orthodontists who scored facial symmetry using the Visual Analog Scale. (B)- A pilot retrospective study included 18 patients divided into four groups, 1- pre-BSSO, 2- post-BSSO, 3- pre-USSO, and 4- post-USSO. Measurements to compare BSSO vs. USSO were: gonial angle (Co-Go-Me); ramus length (Co-Go); corpus length (Go-Me).

**Results.** (A)- Statistically significant differences were observed between USSO pre-surgical group and each of the post-surgical and control groups (p<0.001). Symmetry scores were similar for control and post-surgical groups (p=0.774). Symmetry scores for the mirrored group were significantly higher than those of the control or post-surgical groups (p<0.001). (B)- Go-Me and mandibular set back were more significant with BSSO post-surgically. Co-Go-Me was not significantly different between groups.

**Conclusion.** When indicated, USSO is dependable for facial asymmetries associated with Class III. BSSO remains indicated in borderline malocclusions where more mandibular AP movements or rotations are needed.



Tony Bouez  
Zoubeida Yahfoufi

Department of Periodontology, Faculty of Dental Medicine,  
Lebanese University

## Veneers after Esthetic Crown Lengthening: A Multidisciplinary Approach

**Background.** Nowadays, esthetic treatment protocols can resolve many problems and guide decisions in a multidisciplinary approach to obtain satisfactory and predictable results. When gummy smile is caused by excessive gingival tissue partially covering the anatomical crown of the teeth, an esthetic crown lengthening is recommended. The etched porcelain restoration offers the advantages of increased strength, color, stability, and biocompatibility for a veneering material using composite merely as a luting agent.

**Aim.** This case report aims to evaluate the esthetic outcome of the combination of esthetic crown lengthening with indirect ceramic veneers.

**Methods.** A 22-year-old female patient complained of a “gummy smile” and disliked the shape, size and color of her maxillary anterior teeth restored with direct composite veneers. After comprehensive clinical and radiological examinations, a crown lengthening surgery was carried out, and teeth were restored by indirect ceramic veneers after 6 months of the surgery.

**Results.** Gingiva maintained its level after 1 year follow-up with a reduction in gingival display. At 6 months follow-up after teeth restoration, ceramic veneers appeared to be an effective clinical solution as they had favorable esthetic and functional properties. The patient reported an esthetic pleasant smile.

**Conclusion.** This clinical report emphasizes the multidisciplinary approach required for comprehensive treatment planning. A thorough knowledge of the relationship between the periodontal tissue and restorative dentistry is critical for ensuring adequate shape, function, esthetics and health of the dental tissues.



Hachem Chebli  
Wahib Hadchiti  
Zoubeida Yahfoufi

Department of Periodontology,  
Faculty of Dental Medicine, Lebanese University

## The Use of Emdogain® in Periodontal Disease

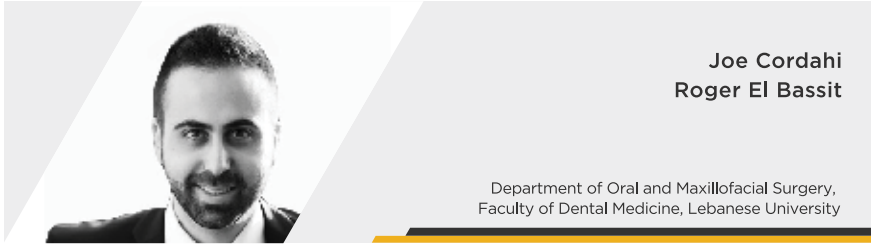**Background.** More than 20 years ago, it was found that enamel matrix proteins (EMPs) could be utilized as a biological agent capable of periodontal regeneration. EMPs are proteins secreted by Hertwig's epithelial root sheet capable of promoting periodontal regeneration. During tooth development, it is deposited on the root surface prior to cementum formation and plays a possible role in cementogenesis. The purified fraction derived from the enamel layer of developing porcine teeth was given the name of enamel matrix derivative (EMD). Several materials have been used in periodontal regeneration and Emdogain® is one of them.

**Aim.** The aim of this study was to evaluate the effect of EMD (Emdogain®) in periodontal tissue regeneration.

**Materials and Methods.** Two patients with chronic periodontitis (1 female and 1 male) received a non-surgical therapy. 2 months after the initial therapy, the infrabony defect was treated with Emdogain® and bovine bone (Bio-Oss®). Plaque Index (PI), bleeding on probing (BOP), pocket depth (PD) and attachment level (AL) were measured at baseline and 6 months after the surgical treatment in addition to radiological examination.

**Results.** All sites showed reduction in PD, BOP, PI and slightly gain of the AL. The periapical radiograph showed that the infrabony defect was partially filled with bone 6 months after the regeneration surgery.

**Conclusion.** Emdogain® facilitates the attachment and proliferation of periodontal ligament cells, influences the early phase of mucosal healing and presents anti-microbial properties and fewer adverse events and postoperative complications than other techniques.



Joe Cordahi  
Roger El Bassit

Department of Oral and Maxillofacial Surgery,  
Faculty of Dental Medicine, Lebanese University

## Edentulous Maxilla Rehabilitation

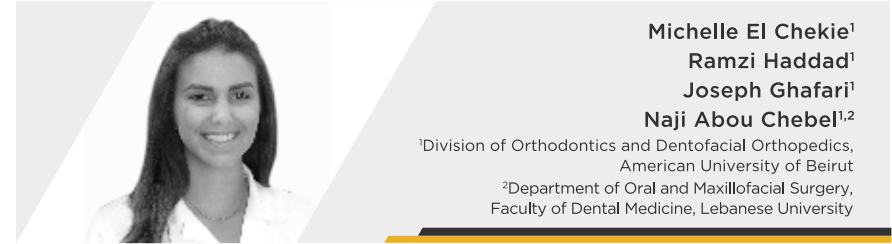**Background.** Treatment of totally and partially edentulous patients with endosseous implants requires a multidisciplinary team approach. This team generally consists of an implant surgeon, a restorative dentist, and a dental laboratory technician. Implant dentistry is a restorative-driven service, and the ultimate success of implant treatment is measured, at least in part, by the aesthetic and functional results as perceived by patients.

**Objectives.** The aim of this case series was to analyze the treatment planning modalities and criteria for an edentulous maxilla considering all the factors for the overall success (medical conditions, implants positioning, maxilla to mandible relationship, prosthesis types, and esthetics...).

**Material and methods.** Three patients with edentulous maxilla were treated at the Department of Oral and Maxillofacial Surgery at the Lebanese University: 2 with Astratech® implants and 1 with Nobel Biocare® implants. All patients had undergone meticulous medical questioning, radiographic examination (CBCT and panoramic radiographs) and clinical examination prior to the treatment.

**Results.** Implant positioning and number changes with the treatment modalities to ensure appropriate biomechanical features and esthetics, a wide range of maneuverability in the prosthesis design (fixed or removable, screwed or cemented...) is present and should lead to the final success.

**Conclusion.** Prosthesis design has a major impact on the number, size, and position of the implant(s) to be used in a particular treatment plan. Treatment planning for implant dentistry must therefore begin with the restorative phase prior to considering the surgical phases of treatment.



Michelle El Chekie<sup>1</sup>  
Ramzi Haddad<sup>1</sup>  
Joseph Ghafari<sup>1</sup>  
Naji Abou Chebel<sup>1,2</sup>

<sup>1</sup>Division of Orthodontics and Dentofacial Orthopedics,  
American University of Beirut

<sup>2</sup>Department of Oral and Maxillofacial Surgery,  
Faculty of Dental Medicine, Lebanese University

## Demographic and Multistage Assessment of Cleft Lip and Palate Treatment

**Background.** Over 100 infants are born with cleft lip and palate (CL/P) annually in Lebanon, but their long-term treatment is not properly established through multidisciplinary craniofacial teams.

**Objectives.** 1- Evaluate demographic characteristics and severity of CL/P patients seeking treatment at the Division of Orthodontics and Dentofacial Orthopedics (AUBMC). 2- Quantify soft tissue changes following naso-alveolar molding (NAM) compared to non-NAM CL/P.

**Methods.** 1- In a cross-sectional evaluation of 106 CL/P, assessment was conducted of the parental socio-demographics, consanguinity and cleft surgeries. Prediction of treatment need was rated from 1 (least severe) to 5 by the modified GOSLON yardstick using pretreatment records of 60 CL/P.

2- Initial (T1), post-NAM (T2) and post-surgery (T3) soft tissue measurements were made on photographs of 2 groups of equal numbers (N=13): G1, treated with the Haddad modified NAM appliance (1.1+2 months); G2, non-NAM treated (6+0.2 months). Measurements were analyzed statistically.

**Results.** 1- Bilateral, unilateral left, and unilateral right CL/P were found in 45%, 34% and 19% of patients respectively. Consanguinity was observed in 37%; 28% of affected families were from the South. The majority of patients (56.14%) had high GOSLON scores (4 to 5). 2- In G1 at T2, nasal symmetry improved significantly, cleft size reduced by 66%, columellar length elongated by 138%. At T3, all soft tissue measurements improved more in G1 than G2.

**Conclusion.** Severity of CL/P probably reflected lack of multidisciplinary management at the early stages of treatment. NAM provided a reliable treatment approach prior to surgery to improve esthetic and functional results.



Sandy El Haddad  
Ibrahim Nasseh

Department of Oral Medicine and Maxillofacial Radiology,  
Faculty of Dental Medicine, Lebanese University

### Comparison of Size Changes in Two Different Graft Materials on CBCT

**Background.** In sinus augmentation procedures, the assessment of size changes of grafted materials is important in the clinical practice.

**Objective.** The aim of this study is to quantitatively assess on CBCT the grey values and graft size changes after external sinus lift using two different graft materials.

**Materials and methods.** 2 external sinus lifts were performed on the same patient using a xenograft and an allograft on the right and left side respectively. Post-operative CBCTs were taken at 1 month, 7 months and 9 months interval for the right sinus lift, and at 1 month and 3 months for the left one, using the same machine and same exposure values. Specific landmarks were used to assess the size of the grafts in different CBCTs.

**Results.** On the right side (xenograft): graft width decreased at 7 and 9 months compared to baseline (1 month) by 27.12% and 29.25% respectively, the length by 22.46% and 23.1% and the height by 4.07% and 4.52%

This decrease was more pronounced in the case of the allograft (left side): the width decreased by 27.48% compared to the baseline (1month), the length by 16.97% and the height by 8.8%. Further studies should be done for a long-term evaluation of these 2 variables.

**Conclusion.** The present retrospective investigation demonstrated a higher bone loss percentage for the allograft.



Melissa El Khoury  
Adib Kassis

Department of Orthodontics,  
Faculty of Dental Medicine, Saint-Joseph University

### Qualité de Vie après Chirurgie Orthognatique

Vu que le succès du traitement orthodontique ou chirurgical ne réside pas uniquement dans le bon alignement dentaire ou le bon engrènement, mais dans le bien être du patient, le but de cette étude portera sur l'évaluation de la qualité de vie des patients Libanais, ayant déjà subi un traitement orthodontique, suivi d'une correction chirurgicale des bases osseuses.

Pour réaliser ceci, un questionnaire basé sur l'OHIP14, sera adressé aux patients. Ce type d'étude permettra de bien reconnaître les besoins des patients, leurs contraintes quotidiennes vécues suite à ce type de traitement dans le but de mesurer le rapport risque/bénéfice de la chirurgie orthognatique pendant la pose du plan de traitement et d'essayer d'améliorer les conditions et d'optimiser les résultats pour garantir au patient le traitement idéal.



Rita El Ozeir  
Badry Meouchy

Department of Periodontology,  
Faculty of Dental Medicine, Lebanese University

### Combined Periodontal and Restorative Treatment of Gingival Recession Associated with Carious Cervical Lesions: A Case Report

**Background.** In clinical practice, it is common to observe multiple gingival recessions (MGRs) associated with carious and non-carious cervical lesions (CCLs and NCCLs).

Main concerns associated to MGRs are accentuated tooth sensitivity, and the appearance of long clinical crown compared to adjacent healthy teeth.

Conventional restorative procedures successfully decrease teeth hypersensitivity but fail to restore initial tooth length.

In most cases a combination of periodontal and restorative treatments provides the best functional and esthetic result.

**Aim.** This 1-year case report helped to focus treatment outcomes and predictability of combined restorative-periodontal approach using subepithelial connective tissue (CT) graft combined with coronally advanced flap (CAF) for the treatment of MGRs associated with CCLs.

**Methods.** A 24-year-old female presented to our department complaining of tooth hypersensitivity, CCLs and displeasing esthetics associated with bilateral class I MGRs.

Before surgery, composite restorations restored the anatomical cemento-enamel junction (CEJ), leaving the remaining exposed root surface to be treated periodontically.

The surgical technique adopted was CAF combined with a subepithelial CT graft from the palate. The CT was positioned at the level of the CEJ, and sutured at the base of the anatomical de-epithelialized papillae. The flap was positioned coronally, providing complete coverage of the CT, and secured 1mm coronal to the CEJ.

**Results.** At 1-year follow-up, complete root coverage was achieved and the patient reported an aesthetically pleasant appearance along with a complete resolution of dental hypersensitivity.

**Conclusion.** The suggested combined restorative-periodontal surgical approach provided successful root coverage and a favorable esthetic outcome in the treatment of MGR associated with CCLs.



Nadine El Sibai  
Elie Azar El Maalouf

Department of Periodontology,  
Faculty of Dental Medicine, Lebanese University

### Full-Arch Maxillary Rehabilitation by Immediate Implant Placement and Immediate Temporization: A Case Report

**Background.** Dental implant offers a long-term solution for replacement of missing teeth with high average life expectancy. During the last decade, conventional implant placement demonstrates a valid therapeutic option in terms of implant success and survival rate. Although this protocol showed predictable results, it provides significant disadvantages: additional surgical procedures, longer treatment time, and discomfort to the patient. Nowadays, immediate implant placement and temporization can resolve these undesirable consequences.

**Aim.** The aim of this report is to describe a case of immediate implant placement with immediate temporary prosthetic rehabilitation, by evaluating implant survival rate, esthetics and bone maintenance.

**Methods.** A 58-year-old systemically healthy female patient reported complaining of teeth mobility and pain in the maxilla. After clinical and radiographic examination, the upper teeth were deemed unrestorable. A full-arch maxillary rehabilitation fixed on eight implants supported prosthesis were selected to be placed. Covered by 0.12% chlorhexidine digluconate, the patient received a nonsurgical periodontal treatment. Two weeks later, teeth extraction, immediate implant placement with immediate provisional crowns were performed at the maxilla. After 4 months, the teeth were prepared to receive a cement-retained zirconia crowns.

**Results.** At 12 months post-loading of the final restorations, all implants were successfully osseointegrated with high implant survival rate, a stable bone maintenance was achieved and patients' esthetic appearance at all stages of treatment was preserved.

**Conclusion.** With appropriate patient selection and careful clinical planning, full-arch maxillary rehabilitation by immediate implant placement with immediate temporization can be a safe and predictable procedure.



Hachimia Fahes  
Edgard Nehmé  
Alexandre Saber  
Antoine Melkane

Department of Oral Pathology, Faculty of Dental Medicine,  
Saint-Joseph University

## The Interest of an Early Diagnosis of Carcinoma in the Dental Office

Oral cavity neoplasms can have similar clinical manifestations, including pain, swelling, asymptomatic white or red lesion and many others. Early diagnosis may be possible during examination of the oral cavity or discovered during dental work-up for another complaint. Studies showed that 90% of oral cavity neoplasms consist of squamous cell carcinomas (SCC). The remaining 10% of malignancies consist of carcinomas of minor salivary glands (3-5%), sarcomas of the soft tissues and the bone, malignant odontogenic tumors, malignant melanomas, non-Hodgkin lymphomas, and metastases from primary tumors located elsewhere in the body.

Many studies have tried to identify a causative role of HPV infection in oral cancers, but no conclusive data could be drawn to this date. Prognostic factors of minor salivary gland MEC and palatal SCC include: age, tumor size, histopathological grade, clinical stage, perineural and vascular involvement, and lymph node or distant metastases.

In this poster, we present two different types cases of oral cancer with a different clinical and histopathological presentation. Early diagnosis resulted in complete minimally-invasive resection of the lesions with no need for extensive reconstruction nor any adjuvant therapy. Consequently, the two cases had excellent oncologic and functional outcomes.



Philippe Farha  
Mona Sayegh Ghossoub

Department of Orthodontics and Dentofacial Orthopedics,  
Faculty of Dental Medicine, Lebanese University

## Stairway to Excellence in Orthodontics: A Case Report

In 1972, Proffit stated: "Close interdisciplinary cooperation is essential to attainment of an optimum treatment result". Adult orthodontics is increasingly trending towards a more interdisciplinary attitude of treatment. Several reasons may explain this fact, they tend to be out of growth, or their bad oral hygiene may have taken a toll on their dental status. Patients are usually unaware of the complexity of their cases, and hence, the patient's chief complaint "is often only the tip of the dental iceberg", according to Melsen. Thus, orthodontists have a vital role in meticulously explaining the most ideal treatment plan, which often do not exclusively include an orthodontic approach, to such patients. The aim of the current case report is to present a complex Class III surgical case that has been treated by the combined efforts of several specialists including orthodontist, prosthodontist, oral surgeon and maxillofacial surgeon. The final result consequently portrays the significance of considering an interdisciplinary approach in the primary treatment plan.



Layal Ghandour  
Ghada Asmar

Department of Orthodontics and Dentofacial Orthopedics,  
Faculty of Dental Medicine, Lebanese University

### Maxillary Sinus Size in Gummy Smile Patients with Vertical Maxillary Excess

**Background.** Etiological factors contributing to gummy smile have been extensively discussed in the literature. Vertical maxillary excess is the main skeletal cause. The gold standard treatment for vertical maxillary excess is a combined surgical orthodontic treatment. Orthodontic treatment with skeletal anchorage has been recently appreciated to be an alternative for surgery. Nevertheless, a comprehensive diagnosis must be reached prior to orthodontic or surgical intervention to meticulously assess root proximity with adjacent anatomical structures specifically the maxillary sinus.

**Aim.** The aim of this study is to assess the dimensions of the maxillary sinuses among Lebanese patients with different facial patterns. Specifically, to study the relation between sinuses' sizes in gummy smile subjects with vertical maxillary excess.

**Materials and methods.** A retrospective descriptive study was conducted on patients who attended the Lebanese University, Department of Orthodontics and Dentofacial Orthopedics for the past 15 years using their photographic and radiographic records. Gummy and non-gummy smile patients with different facial patterns were selected based on inclusion and exclusion criteria.

**Clinical significance.** The anticipated results from our study will highlight the impact of the maxillary sinus size on the vertical maxillary displacement during facial growth and subsequently on the orthodontic treatment approach.



Rayane Ghorayeb  
Chloé Karen Abboud  
Sérine Assi  
Edgard Nehmé

Department of Oral Pathology,  
Faculty of Dental Medicine, Saint-Joseph University

### L'Ostéonécrose Chimique des Maxillaires Due aux Bisphosphonates : Présentation de Cas Cliniques

Compte tenu de leur mode d'action, les Bisphosphonates servent à traiter diverses pathologies osseuses bénignes dont essentiellement l'ostéoporose et la maladie de Paget ainsi que des pathologies malignes tel que les métastases osseuses et les myélomes multiples dans le cadre d'un protocole plus général de chimiothérapie anticancéreuse. Il existe trois générations de Bisphosphonates de puissance croissante, de la première jusqu'à la troisième génération. La complication majeure de cette molécule est l'ostéonécrose des maxillaires, évoquée pour la première fois par Marx en 2003. L'AAOMS recommande en 2014 de modifier la nomenclature de « Bisphosphonate-Related Osteonecrosis of the Jaw » (BRONJ) en « Medication-Related Osteonecrosis of the Jaw » (MRONJ). Ce changement est effectué afin de tenir compte du nombre croissant de cas d'ostéonécroses chimiques impliquant le maxillaire et la mandibule associées à d'autres molécules médicamenteuses comme le Denosumab. Plusieurs facteurs de risque favorisent l'apparition de cette pathologie. Citons à titre d'exemple la puissance de la molécule, la voie d'administration (per os ou intraveineuse), la dose, la durée et la fréquence du traitement. Le but de ce poster est d'illustrer quelques cas cliniques d'ostéonécrose médico-induite par les Bisphosphonates, ainsi que la prise en charge, au cas par cas, et les recommandations à suivre.



Hiba Haidar  
Elie Sidnaoui

Department of Oral and Maxillofacial Surgery,  
Faculty of Dental Medicine, Lebanese University

### Lateral Approach Using Different Bone Substitute: Difference between Histological and Radiological Study

**Background.** Bone tissue atrophy may constitute a relative contraindication for implantation. Thus, sinus lift surgery is a form of pre-prosthetic surgery for increasing the quality and quantity of bone in the posterior region of the maxilla.

**Objectives.** The aim of this study was to evaluate, both qualitatively and quantitatively, the new bone formation either with allograft or xenograft substitutes before implant placement.

**Materials and methods.** Four patients were selected, their age ranging from 50 to 70 years. A panoramic and CBCT radiographs were taken at baseline. A lateral window was done and for 2 patients xenograft (Bio-Oss®) were used, allograft (Puros®) was used for the third patient, and another type of xenograft (OCS®) was added to the fourth patient. For the patients where xenografts were used, 9 months later osseous carot biopsy using the trephines was taken before implant placement. On the other hand, for the patients where allografts were used, the same biopsy of bone was taken at 4 months. A histological analysis was performed for all biopsies.

**Results.** Despite the similarity between the histological and radiological study based on CBCT, CBCT gives an overview about the quality of the bone and mainly the CT and the Micro CT.

**Conclusion.** Indeed, there are many artefacts can be happened during the CBCT. Nevertheless, radiology can help us around 80% about the quality of bone. In fact, Micro CT and CT are more accurate than CBCT in determining the quality of bone more.



Rami Hamdan  
Fadi El Hajj

Department of Periodontology,  
Faculty of Dental Medicine, Lebanese University

### Crestal Sinus Floor Elevation for a Residual Bone Height of Less than 4mm

**Background.** Inadequate bone volume is a frequent problem found during the rehabilitation of the edentulous ridge using implants, especially in the posterior maxilla. In 1980, Boyne and James described a lateral access to the sinus to create a space between the Schneiderian mucosa and the sinus bone floor that was filled by a biomaterial for bone regeneration. A less invasive surgical approach to the sinus through the ridge was proposed in 1986 by Tatum and subsequently refined by Summers in 1994, using osteotomes. This surgical technique was originally indicated where the sub-sinus residual bone height (RBH) is 5–6 mm; when less, it affected the success rate of implants (ISR).

**Aim.** Through these case reports, we aim to describe and evaluate the use of the crestal approach where the RBH is less than 4mm when a lateral approach is normally indicated.

**Materials and methods.** After administrating an analgesic solution and the elevation of a full-thickness flap, we started drilling (pilot then twist drills) 1mm below sinus floor. which was directly infractured by the final osteotome without interposition of the graft material between the osteotome and the sinus floor. Xenograft was progressively condensed using an osteotome until the membrane is lifted till 11-12mm in order to place a 4.1 diameter implant of a length of 10mm simultaneously.

**Results.** ISR was 100% for all the cases, with a good clinical and radiographic stability over the years.

**Conclusion.** The crestal approach using osteotomes is a predictable technique even in cases with RBH less than 4mm.





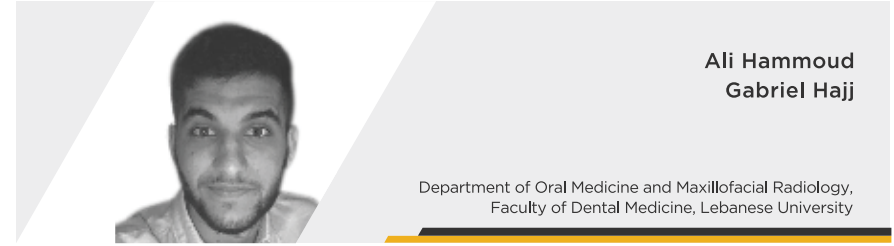### Full Arch Implant Screw-Retained Fixed Prosthesis using the PEEK Framework: A Case Report

**Background.** Rehabilitation of fully edentulous jaws using screw-retained implant-supported restorations has become widespread usually using metal or zirconia frameworks. A new metal-free esthetic and less rigid material PEEK (Polyether ether ketone) is available to clinicians and patients. This new material avoids having a rigid and bulky framework.

**Case description.** A 59 years old female had a full upper arch reconstruction on 6 bone level implants using this PEEK material. PEEK framework milled from CAD/CAM blanks was performed/fabricated. The framework was designed to receive monolithic zirconia crowns with pink composite serving as gingiva.

The patient noticed the low weight of the restoration as well as its esthetics. The fit of the framework on insertion and the chewing comfort expressed by the patient support the use of such new material. The overall result was maintained at one month follow up.

**Conclusion.** PEEK material is a new metal-free restorative treatment option that may be suitable for complex implant-supported restorations in edentulous jaws.



### Simple Bone Cyst: An Unusual Clinical Presentation

The simple bone, an uncommon lesion of the jaws, belongs to the category of “pseudocyst” because its lack of lining epithelium membrane. Most simple bone cysts are diagnosed in young patients, with a peak in the second decade. It is asymptomatic and most often diagnosed during routine radiological examination. The body of the mandible is the most common site of the jaw. This article is a case of a simple bone cyst with unusual chief complaint. The initial symptom of the lesion was numbness of the left lower lip and the chin. The lesion was explored surgically. The numbness disappeared after 3 months. The lesion was followed up after 6 months with complete healing.



## Innovation in Selective Barriers

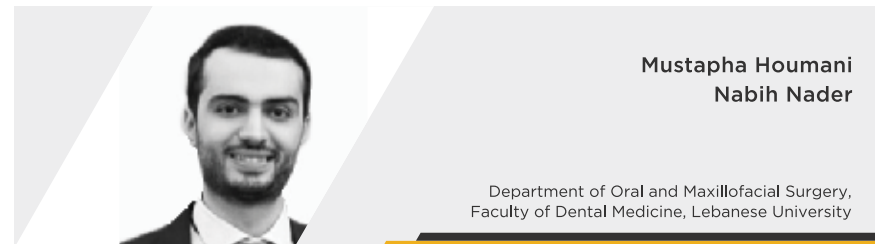
During the last decade, different surgical procedures have been advanced in the regeneration of the main structural tissues of the periodontium. A variety of surgical approaches have been used in guided tissue regeneration and bone regeneration using different kinds of barrier membranes with or without osteoconductive/inductive bone graft material.

These physical barriers can be divided into two main groups: non-resorbable and resorbable membranes. The drawback of non-resorbable membranes is mainly the need of a second surgical procedure for their removal, which lead to the development of resorbable barrier membranes. However, these resorbable barriers also present some disadvantages like poor mechanical properties and rapid degradation leading to a shortened functional period.

The development of biomaterials for periodontal regenerative applications is a challenge from the engineering and biological perspectives. Extensive research has been carried out over the past few decades to develop some novel biomaterial options.

Cellular and molecular events during periodontal regeneration are important to be understood in order to optimize the indications of the barrier membrane needed for regeneration. The biological and biomechanical properties of the barrier material should be well conceived in order to recognize the integrity of each membrane and its function.

The future of periodontal repair/regeneration seems promising with doors wide open for researchers to use new and emerging technologies. The aim of this review is to present different physical barriers that have proven their significant role in periodontal regeneration mechanisms and to review their evolution and current developments.



## Alveolar Socket Preservation: Punch Technique of Soft and Hard Tissues: A Case Series

**Background.** Preservation of the residual alveolar socket at the time of tooth extraction has been proved to be very useful.

Having an optimal bone for a good support of the implant occurs by grafting the socket by materials that involve bone proliferation. In addition, coverage of the grafted extraction site with wound dressing materials may enhance wound stability.

**Objectives.** The aim of this case series is to demonstrate the augmentation with autologous punch formed of soft and hard tissue as effective in socket preservation techniques.

**Material and Methods.** Four patients between 45 and 63 years of age are presented in this case series. All patients suffered from damage in a tooth that must be extracted. One patient serve as a control with normal healing and three patients as experimental group where residual sockets were filled with a punch of hard and soft tissue. Clinical and radiographical data were collected at T0 (surgery time) and 6 months when an implant placement is decided. The tissue cylinders harvested during implant preparation were prepared for histological analysis.

**Results.** Clinically, after 6 months there was noted a decrease in socket depth in both groups and more decrease in buccolingual width in the control group. Radiographically, the difference in socket height, residual ridge, and width was lower than the control group. Histological sections showed well-formed mature bone with cortical as well as cancellous bone.

**Conclusion.** Ridge preservation technique using the punch technique resulted in greater stability in the horizontal and vertical dimensions after 6 months.



Zeinab Idriss  
Samia Farha

Department of Pediatric Dentistry and Dental Public Health,  
Faculty of Dental Medicine, Lebanese University

### Comparison of Instrumentation Time and Quality of Obturation Using Hand Files and Rotary Single File (Xp-Endo Shaper) for Root Canal Preparation in Primary Teeth

**Background.** Pulpectomy is the treatment of choice in pulpally involved primary teeth. Appropriate root canal shaping and obturation are predictors of endodontic treatment success. Recently, various bio-mechanical preparation techniques with rotary files have been proposed to replace the standardized manual techniques.

**Aim.** The aim of this study was to compare root canal instrumentation time and quality of obturation using manual technique versus rotary single file system (XP-endo Shaper) in primary molars pulpectomy.

**Materials and methods.** A total of 40 primary root canals from 10 second primary mandibular molars presenting symptomatic irreversible pulpitis and requiring pulpectomy were selected. The sample population age was between 4 and 8 years old and was divided into two groups: Group I consisted of 20 root canals that were instrumented with Hedström files and Group II of 20 root canals that were instrumented with XP-endo Shaper single rotary file. For each canal, instrumentation time and quality of obturation were assessed. Statistical analysis was done using Chisquare and ANOVA tests.



Julien Issa  
Nayer Aboelsaad

Department of Oral Diagnostic Science, Faculty of Dentistry,  
Beirut Arab University

### Rare Presentation of Large Bony Multilocular Radiolucent Lesion: A Case Report

A 22-year-old male came to Beirut Arab University clinics complaining from pain in the lower jaw and was not able to sleep for the past three days after getting kicked on his chin, with presence of crowded teeth and seeking of orthodontic treatment as solution. Upon taking patient's history: "Patient had a motorcycle accident 3 years ago and he had lower jaw pain, he did not consult any physician due to his low socioeconomic status."

After an extraoral examination that revealed no detectable abnormality, intraoral examination showed a detectable tooth drifting and severe crowding in anterior region. A radiographic examination included a panoramic X-ray and a cone beam computed tomography (CBCT), that revealed a large radiolucent lesion with irregular scalloping margins that extends from the distal surface of 36 to the distal surface of 47 with root resorption and an impacted tooth at the inferior right border of the mandible. Aspiration biopsy was taken and reveal blood. The differential diagnosis based on radiographic examination included traumatic bone cyst.

A marsupialization was surgically performed with extraction of the following teeth 36,35,32,31,41,45,46 and placement of temporary prosthodontic bridge for esthetics and function. After six months follow up, a new bone formation has been noticed on a panoramic X-ray at the site of the previous lesion. Then after one year, and upon checkup appointment using (CBCT) more bone deposition was recorded.



Eliane Jabbour<sup>1</sup>  
Chadi Torbay<sup>1</sup>  
Prasanna Neelakantan<sup>2</sup>  
Hani Ounsi<sup>1</sup>

<sup>1</sup>Department of Restorative and Esthetic Dentistry and Endodontics,  
Faculty of Dental Medicine, Lebanese University

<sup>2</sup>Faculty of Dentistry, University of Hong Kong



Joulia Jouni  
Nayer Aboelsaad

Department of Oral and Surgical Sciences, Division of periodontology,  
Faculty of Dentistry, Beirut Arab University

## Hydrodynamics in Endodontics

Root canal anatomy is a complex space with irregularities that may contain tissues remnants and microorganisms that cannot be approached by instruments. This highlights the importance of the irrigant and to which extent it can reach non-instrumented areas. Hence, irrigation dynamics has gained insight in endodontics as it deals with how irrigants behave within the root-canal space. As it turns out, the mode of delivery is as important during endodontic disinfection as the antibacterial characteristics of the irrigants. Some of the goals of fluid dynamics studies in endodontics are to improve needle-tip design for effective and safe delivery of the irrigating solutions and to optimize the rheological properties of the root canal space to improve irrigation efficiency.

## The Effectiveness of Systemic Antioxidant in Treatment of Periodontitis (Randomized Control Double-Blinded Clinical Study)

**Background.** Antioxidants are substances that can prevent or slow damage to cells caused by free radicals, unstable molecules that the body produces as a reaction to environmental and other pressures. Chronic periodontitis is biologically characterized by increase in oxidants levels. There is debate on whether antioxidant-rich foods or supplements have anti-disease activity.

**Aim.** The aim of this study was to evaluate the efficiency of systemic antioxidants (pomegranate and lycopene) in treating stage II periodontitis patients.

**Materials and methods.** Forty middle aged healthy patients, with mild to moderate chronic periodontitis were selected to participate in this randomized double-blinded clinical trial. After IRB approval. Following scaling and root planning sessions, clinical parameters were recorded including: probing depth, clinical attachment levels, plaque index and gingival index. Venous blood was collected in plain tubes for antioxidant blood serum level assessment serum. Each patient was used as the unit of analysis before and after treatment. Patients were divided to 4 groups: Group A took pomegranate 250mg supplements, Group B took lycopene 30mg, Group C took both and Group D took a placebo as control. All clinical parameters were reassessed after three months.

**Results.** All study groups showed improvement in clinical parameters, Group C showed more favorable results, and there was no statistically significant difference between Groups A and B. The clinical results coincided with the lab results (antioxidant serum levels).

**Conclusion.** The adjunctive use of antioxidants to the line of treatment for treating stage II periodontitis patients in adjunct to scaling and root planning have been proven to be effective and successful.



Ali Jrady  
Hala Ragab

Division of Operative and Esthetic Dentistry,  
Faculty of Dentistry, Beirut Arab University

### Color Stability of Bleached Shade Resin Composites after Immersion in Different Drinks

**Aim.** The aim of this study was to evaluate the color change of 6 different bleached shade composite resin restorative materials after exposure to different commonly consumed drinks; water, coffee, and pomegranate.

**Materials and methods.** 21 disk-shaped specimens (3x2mm) of contemporary bleached shade composite resins: Filtek-Z250 B1 (microhybrid), Charisma-Diamond BLXL, Charisma-Diamond BLL, Tetric-EvoCeram BXL, Tetric-N-Ceram bleach-N (nanohybrid), and Durafill SSL (microfill), were prepared. The specimens were divided into 3-groups of 7 specimens each and immersed in three solutions for one-week in an incubator (37°C). Color of the specimens was measured with a spectrophotometer using CIELAB color space before and after immersion and color difference ( $\Delta E$ ) was calculated. Data were analyzed by one-way analysis of variance (ANOVA) and Turkey's-HSD Test.

**Results.** According to the statistical analysis, the restorative material, the staining solution, and their interaction were found to play a statistically significant role ( $P < 0.05$ ). Among the different solutions, water did not show any statistical significant color change with all tested groups and have revealed the lowest  $\Delta E$ . However, coffee showed the highest  $\Delta E$  among the tested groups. In terms of comparison among the five restorative materials, Charisma-Diamond BLXL was observed to manifest the highest color change followed by Tetric-N-Ceram Bleach-N, Tetric-EvoCeram BXL, Filtek-Z250 B1, charisma-Diamond BLL, and Durafill SSL consecutively.

**Conclusion.** Regardless to the composition and chemistry of all bleached shade composite resins, significant color change was recorded after immersion in the staining solutions. Microfilled composites had the least tendency to stain when compared to microhybrid or nanohybrid composite resin restorative materials.



Adib Kassis<sup>1</sup>  
Nada Osta<sup>1</sup>  
Joseph Ghoubril<sup>1</sup>  
Lana Osta<sup>1</sup>  
Stéphanie Tubert-Jeannin<sup>2</sup>  
Martine Hennequin<sup>2</sup>

<sup>1</sup>Faculty of Dental Medicine, Saint-Joseph University  
<sup>2</sup>Centre de Recherche en Odontologie Clinique, Clermont University

### Cross-Cultural Adaptation and Validation of the Child Perceptions Questionnaire (CPQ 14-11) among Children in Lebanon

**Background.** The aim of this study was to assess the reliability, reproducibility, convergent and discriminant validity of the Child Perceptions Questionnaire (CPQ)11-14 in a group of 11 to 14-year-old Lebanese children.

**Methods.** This was a cross-sectional study. Children were recruited from five schools in Beirut. Data were collected from self-administered questionnaires and a clinical intraoral examination was conducted. In addition to the CPQ11-14, the questionnaires included socio-demographic characteristics, questions about each child's perception of oral and general health status and of dental aesthetics, satisfaction with the dental conditions and the need for dental treatment. The oral examination included DMFT, the number of missing teeth and an orthodontic assessment of malocclusion using the Dental Aesthetic Index (DAI).

**Results.** The final number of included children was 693 and their mean age was 13.1430.82 years. The mean CPQ score was 15.60314.55. Cronbach's alpha of the global CPQ score was 0.880. The reproducibility of the overall CPQ score was important, as was the CPQ score for each of the four domain scores ( $ICC > 0.682$ ;  $p < 0.001$ ). Higher CPQ scores were found for children with self-perceived poor general health ( $p < 0.001$ ), unsatisfactory oral health ( $p < 0.001$ ), needs for dental treatment ( $p < 0.001$ ) and perception of dental aesthetic problems ( $p < 0.001$ ). Multiple linear regression models show that the recruitment, the DMFT index and the DAI were significantly associated with the CPQ global score ( $p = 0.004$ ).

**Conclusion.** The Lebanese version of the CPQ11-14 showed excellent psychometric properties and was able to distinguish children with different oral conditions.



Micheline Katramiz  
Mona Nahas Gholmieh

Department of Pediatric Dentistry and Dental Public Health,  
Faculty of Dental Medicine, Lebanese University

### Sleeping Disorders in Children: The Importance of Awareness and Early Intervention for the Child Quality of Life

**Background.** Sleep is a vital physiological function for the maintenance of health and quality of life by resting the body and restoring its energy levels. In fact, sleep is as important as food and water. However, some children have sleep disordered breathing (SDB) that can disturb their normal sleep and affect the quality of their lives.

**Aims.** 1- Evaluate the proportion of children at high risk of presenting obstructive sleep apnea (OSA) among 1000 children chosen randomly from in North of Lebanon; 2- Evaluate the impact of SDB on quality of life in these children and the benefits of an early diagnosis; 3- Highlight the importance of the contributions of pediatric dentists in the assessment and treatment of OSA in children.

**Material and methods.** This study was conducted in two steps. First, pediatric patients aged 3 to 12 years with suspected OSA were identified in 5 schools chosen randomly in North and Mount Lebanon. The quality of sleep was evaluated using the Pediatric Sleep Questionnaire that included questions concerning 3 prominent symptom-complexes: snoring, excessive daytime sleepiness, and inattentive/hyperactive behavior. Second, parents of children included in the study were convened to an individual meeting and urged to undergo a complete physical exam specially polysomnography.

**Results.** In progress. (We will have the results within 2 weeks).

**Conclusion.** This is the first study in Lebanon discussing SDB and its impact on children behavior. Inadequate sleep in children has been shown to be associated with obesity, poor academic performance, behavioral problems.



Alain Khairallah  
Hitaf Nasseh

Department of Pediatric Dentistry and Dental Public Health,  
Faculty of Dental Medicine, Lebanese University

### Fiberglass Prefabricated Crowns on Deciduous Incisors: A Case Series

**Background.** A major component while restoring anterior teeth is esthetic, especially in children as it affects their self esteem and confidence.

**Aim.** The aim of this case series is to describe and evaluate the usefulness of prefabricated fiberglass crowns for deciduous incisors.

**Materials and methods.** Three young children were diagnosed with early childhood caries, previous trauma or deep cavities in the anterior region, and primary central incisors were restored using prefabricated fiberglass crowns "Figaro crowns®" after endodontic treatment. Prior to treatment, radiographs and intraoral photographs were taken to evaluate the appropriateness of treatment.

**Results.** Our findings indicate that fiberglass crowns may be appropriate to successfully restore deciduous teeth with good esthetic results, appropriate gingival contour and good mechanical retention and properties. Further long-term clinical studies are required to clarify the usefulness of this restorative method.



**Stephany Khalaf  
Elie Azar El Maalouf  
Sami Mouwakdié**

Department of Periodontology,  
Faculty of Dental Medicine, Lebanese University

### Correction of Altered Passive Eruption: A Case report

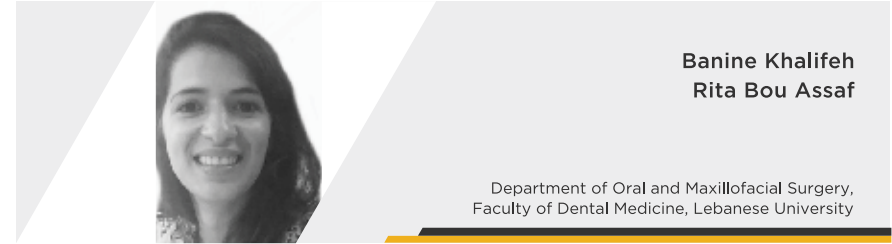**Background.** Smile plays an important role in determining a person's first impression and becomes unpleasant where more than 2 mm of gingiva is visible upon smiling. This is referred to as a gummy smile, and its etiology might be periodontal (as in an altered passive eruption), dento-alveolar, osseous or cutaeno-mucosal.

**Aim.** The aim of this work was to describe a crown lengthening procedure to treat a gummy smile of a periodontal origin. We were particularly interested at reducing gingival exposure and increasing the length of clinical crowns, while transforming square teeth with blunted papillas into triangular teeth with scalloped papillas.

**Materials and Methods.** A 22-year-old patient presented with an excessive gingival exposure. Clinical intra-oral and extra-oral examination and peri-apical radiographs were carried out, and the diagnosis was type 1 subcategory b altered passive eruption, according to the classification of Coslet et al. The treatment consisted of gingivectomy, osteotomy, in addition to osteoplasty where needed.

**Results.** The overall mean gain in clinical crown length was approximately 1.75mm per tooth, and the average percentage of gingival exposure reduction was 37%.

**Conclusion.** Aesthetic crown lengthening alone resulted in a clinical important decrease in gingival exposure. Moreover, the increase in the crown's height led to a more triangular tooth shape with better scalloped papillas. Nonetheless, clinical and radiographical examination are crucial to ensure a proper diagnosis and an adequate management of each case.



**Banine Khalifeh  
Rita Bou Assaf**

Department of Oral and Maxillofacial Surgery,  
Faculty of Dental Medicine, Lebanese University

### Osteotome Sinus Floor Elevation with Simultaneous Implant Placement: A Case Report

An edentulous upper posterior maxilla generally presents bone reduction both in height and width of the alveolar process due to atrophy and to the pneumatization of the maxillary sinus after loss of the teeth, making an immediate implant placement impossible. To overcome these obstacles, a maxillary sinus elevation procedure is used to augment the available bone volume vertically.

Residual bone height is considered fundamental in deciding which augmentation technique can be used to obtain an adequate bone volume. When more than 5mm of residual bone height is available, an osteotome SFE approach could be indicated in order to reduce the morbidity and the invasivity of the treatment compared to lateral approach in which is used when less than 4-5mm of residual bone height is present.

The current study presents a case of a 57-year-old woman with a 4.4mm of the residual bone height and width in the upper-right first Molar. The implant placed using OSFE without bone grafting.

The aim of the study was to evaluate the implant's success and intrasinus radiographical bone gain after functional loading.



Farah Khalifeh  
Bilal Koleilat

Department of Orthodontics and Dentofacial Orthopedics,  
Faculty of Dental Medicine, Lebanese University



Sarah Khamis  
Makram Ammouri  
Kinan Zeno  
Joseph Ghafari

Division of Orthodontics and Dentofacial Orthopedics,  
American University of Beirut

## Second Molar Extraction. A Case Report

Molar extractions are not a recent practice in orthodontics. Several authors recommended the extraction of the second molar for the correction of Class II and III malocclusions. Second molar extraction in itself is not a definitive treatment for orthodontic problems, although it may be useful to eliminate the surgical procedures and complications involved in the removal of impacted third molars. This case report portrays a patient who presented with Class II division 2 in which the treatment plan was to distalize the upper dentition using micro-implants. On the left side, the second molar was extracted and the distalization was remarkably faster than the extraction of third molar on the right side. Second molar extraction can shorten treatment time and simplify treatment mechanics. This clinical case proves that it is a choice to consider.

## A Finite Element Comparison of Surgical Techniques for Acceleration of Tooth Movement

**Background.** Adjunctive corticotomy techniques are advocated to reduce the duration of orthodontic treatment, but their effectiveness remains controversial. **Objectives:** To compare the stresses and displacements generated by distalization of maxillary teeth against miniscrews with adjunctive decortication and micro-perforation.

**Methods.** A 3D model of the maxilla containing its components (teeth, cortical and trabecular bone, PDL) was prepared for finite element analysis (FEA), using first ScanIP™ 7.0 software (Simpleware Ltd., UK) to construct the model and later ABAQUS 6.13 for mechanical modeling. Buccal segment distalization was simulated with a direct force (150 grams) from a miniscrew placed between the 2nd premolar and 1st molar to the canine bracket. Decortication (DC, continuous vertical line) and micro-perforations (MP, n=6) techniques were introduced distal to the canine. Initial canine displacement and stress distribution on the PDL were recorded and compared.

**Results.** The highest Von Mises stress values were observed on the distal surface of the canine with both DC and MP, close to the area of surgical cut and perforation. Higher stress values were observed with MP than DC. The latter were equal to control.

**Conclusions.** The findings indicate that the number of microperforations was equivalent to the corticotomy within the thickness of the cortical bone, leading to similar results. A preliminary clinical implication is that MP may result in similar results with greater number of perforations.





Hassan Khafer  
Bassel Doughan

Department of Pediatric Dentistry and Dental Public Health,  
Faculty of Dental Medicine, Lebanese University

## Caries Index in Children with Special Needs in Lebanon at Special Need School

**Background.** Good oral health is an important component of overall health and implies that teeth, gums, and oral mucosal tissues are intact and free of disease. Children with developmental disabilities, including conditions that affect behavior and cognition, often have limitations in their abilities to perform activities of daily living including oral care for prevention of dental caries.

**Aim.** This study aims to assess the caries index among children with hearing loss, vision disability, autism, mental handicapped and educational difficulties.

**Materials and Methods.** The study was conducted in a school for disabled children between April 2017 and June 2018. 624 children (3 to 23 years of age) were included in the study (395 M, 229 F) of which 127 with hearing loss and deafness (62 F,65 M),76 with vision disability (34 F,42 M), 80 with autism (14 F, 66 M),194 with mental retardation (75 F,119 M), and147 with educational difficulties (44 F,103 M). Trauma prevalence was assessed following WHO criteria.



Sara Khazaka<sup>1</sup>  
Joseph Ghafari<sup>1</sup>  
Ramzi Haddad<sup>1</sup>  
Naji Abou Chebel<sup>1,2</sup>

<sup>1</sup>Division of Orthodontics and Dentofacial Orthopedics,  
American University of Beirut

<sup>1,2</sup>Department of Oral and Maxillofacial Surgery,  
Faculty of Dental Medicine, Lebanese University

## Facial Characteristics of Patients with Unilateral Condylar Hyperplasia

**Background.** Unilateral condylar hyperplasia (UCH) is a rare bone disease characterized by the increased growth of one mandibular condyle that results in an asymmetric facial deformity, with associated alteration of the dental occlusion (unilateral crossbite or open bite). Diagnostic methods include nuclear imaging (Technetium-99) to determine the bony growth activity.

**Aims.** To evaluate the differences between the affected and none affected sides of the mandible in patients with UCH.

**Methods.** Pretreatment panoramic radiographs and postero-anterior cephalograms of 18 UCH patients (ages 15-26 years) seeking orthodontic treatment were analyzed using the Grummons and Delaire analyses. Specific measurements were compared between the affected and non-affected sides using the t-test. Both sides were also compared to population averages to determine the extent of changes from normal values.

**Results.** Statistically significant differences were observed, particularly in the size of the condyle, ramus, and mandibular body. The non-affected side deviation from the norms was related to the severity of the deviation on the affected side. The extent of the malocclusion was related to the amount and duration of mandibular growth. CHS was more severe in males, possibly because of the longer period of growth. The onset of UCH was similar to that reported in the literature (mid to late teens).

**Conclusion.** The time of onset of UCH and age of the patient are associated with the amount and severity of ensuing mandibular deviation. Scintigraphy is necessary to determine condylar activity before surgery, regardless of the asymmetry between affected and non-affected sides.



Christian Khoury  
Antoine Berberi

Department of Oral and Maxillofacial Surgery,  
Faculty of Dental Medicine, Lebanese University



Joumana Lahoud  
Nisrine Wheibe  
Wafaa Nahle  
Aline Rizk

Department of Orthodontics and Dentofacial Orthopedics,  
Faculty of Dental Medicine, Lebanese University

## Evaluation of Third Molar Impaction Distribution and Patterns in a Lebanese Population

Impaction is defined as the failure of a tooth to develop or erupt into its functional position, which is most frequently seen in upper and lower third molars. With the surgical extraction of wisdom teeth being the most common surgery done in dental practice, classifications based on panoramic radiographs such as Pell and Gregory and winter are an essential part of strategical extraction allowing better understanding of third molar position, depth and bone coverage. The aim of the study was to classify upper and lower wisdom teeth in a Lebanese population according to angulation, depth, bone coverage and other criteria, and compare the data to results from other local and international studies. Panoramic radiographs of 71 patients that attended the Department of Oral Surgery at the Lebanese University were analysed, 27 males and 44 females, with a total of 181 third molars. Concerning the upper third molars, the highest angulation type was distoangulated (47.76%) and the Pell and Gregory class C (61.19%) the highest depth of impaction. As for the lower third molars, mesioagulation was the highest type of angle seen (44.73%), type B the highest type of impaction (63.15%) and type II the most frequent relation to the ramus (67.54%). The results allowed a representation of the characteristics of wisdom teeth in the Lebanese population for better predictability of impaction type and surgical interventions.

## How to Choose Retention in Orthodontics

Retention is a challenging, indispensable step that is crucial after every orthodontic treatment in order to stabilize the final perfect occlusion. Relapse happens not only because of the periodontal fibers around the teeth that pull the teeth back into their initial position, but also because multiple factors like normal changes caused by the aging process or functional problems that persist. Different retention protocols exist, but their efficacy and wearing duration differs. Currently, invisible retainers are being used instead of removable retainers, and more often lifelong retention is used instead of retention for a limited duration of time. In a wide variety of different types of retention, choosing the right retention can be challenging, taking into account the initial position of teeth, compliance and acceptance of the patient and the clinician's experience and knowledge in this subject.



Roudy Matar  
Habib Abi Aad

Department of Prosthodontics,  
Faculty of Dental Medicine, Lebanese University

### Esthetic and Mechanical Outcome of Three Different Techniques of Zirconia Single Crowns

**Background.** High translucency zirconia has become worth considering for single esthetic crowns. Zirconia-based ceramics are highly attractive for clinicians, since they fulfill the biomechanical requirements, namely, chemical and dimensional stability, high mechanical strength related to transformation toughening and fracture toughness. The introduction of high strength oxide ceramics as a core material improved the aesthetic properties of zirconia-based crowns with a higher chipping rate of the veneering ceramics. To overcome the veneer cracking problem, non-veneered full contoured, monolithic zirconia restorations can be used. However, the creation of acceptable esthetic result with monolithic zirconia restorations is challenging due to their mono-layered structure.

**Cases description.** Three clinical cases involving different indications are presented in order to illustrate different layering techniques of zirconia restorations used for patients with aesthetic problems related to enamel defects, discoloration and previous porcelain fused to metal restorations. The three techniques are: porcelain fused zirconia or layered zirconia, facial cutback zirconia and full contour zirconia. At three years follow up, no fracture or chipping of the restorations were recorded. The esthetic demands of the patients were fulfilled. Esthetic outcomes are intimately related to the zirconia core used and the type of the underlying preparations.

**Conclusion.** Zirconia restorations may be considered the restoration of choice in case of esthetic problems. However a long term follow up is needed.



Martin Moubarak  
Cynthia Al Bitar  
Wassim El Sayyed

Department of Orthodontics and Dentofacial Orthopedics,  
Faculty of Dental Medicine, Lebanese University

### Frontal Sinus Morphology and Skeletal Maturity: Is there a Link?

The importance of skeletal maturity and growth potential has been established as a major effector in orthodontic treatment planning. To date, there are a myriad of different techniques to locate patients on the growth curve, among which the most popular are hand-wrist-based, cervical vertebral-based, and tooth-based methods. In addition, with the advent of 3D imaging, these techniques have been expanded and new ones appeared such as spheno-occipital synchondrosis analysis. However, the postero-anterior cephalogram elements have been poorly explored in the literature let alone their correlation with skeletal maturity. One of its eminent components, the frontal sinus, has been reported to develop concurrently with growth. On these terms, the size and morphology of the frontal sinus can be a possible tool for skeletal maturity assessment. The objective of this poster is to review the various approaches for growth potential determination and their probable correspondence with frontal sinus morphology as viewed on a frontal cephalometric radiograph.



Mona Naim  
Fatmé Mouchref Hamasni

Department of Periodontology,  
Faculty of Dental Medicine, Lebanese University

### Advanced Combined Bone Loss Treatment Using Guided Tissue Regeneration Technique: A -3Year Follow-up Case Report

**Background.** Given the increasing popularity and clinical success of dental implants, there is a tendency to believe that they are as good as natural teeth, even better in certain clinical situations. There is a dilemma faced when the presence of an advanced periodontitis (severe bone and attachment loss) jeopardizes the decision to take: Guided Tissue Regeneration (GTR), a critical option related to long term stability.

**Aim.** A case report with 3-year follow-up describes the credibility of the GTR technique in case of an advanced vertical bone resorption on maxillary upper incisors.

**Case presentation.** A healthy 50-year-old male patient presented with localized discomfort on the upper left incisor. Clinical and radiographical examinations revealed an advanced attachment loss and bone destruction. A "GTR" technique using bovine xenograft (Bio-Oss®) and resorbable collagen membrane (Bio-Gide®) was performed. The case was followed over 3 years.

**Results.** A significant amount of hard tissue regeneration was noted radiographically with a decrease in probing depth and an improvement of all soft tissue parameters of a healthy periodontium.

**Conclusion.** GTR using a barrier membrane is the treatment of choice in a case of vertical bone loss with remarkable long term stability.

Malak Nasser  
Riad Bacho

Department of Pediatric Dentistry and Dental Public Health,  
Faculty of Dental Medicine, Lebanese University

### Selective Caries Removal to Soft Dentin: An Alternative to Pulpotomy

**Background.** With all the improvement in the dental, focusing on conservative dental treatment remains a main issue to preserve the tooth vitality. Caries are classified according to hardness as: soft, leathery, firm and hard. Selective caries removal to soft dentin can prevent pulp exposure. However, there are no enough studies to evaluate the long-term success of this procedure.

**Materials and Methods:** 10 primary teeth were chosen according to the following criteria: absence of clinical and radiological pathological signs, deep decay that will cause pulp exposure if totally removed and caries involving only one or two sides. The patient should be cooperative, and the age ranging from 5 to 9 years. For the selected teeth, the decay was totally removed at the periphery, while soft caries at the pulp proximity were kept and covered with bioactive material (MTA). Resin enforced glass ionomer was placed over MTA followed by permanent composite restoration. Patients were followed up after 1 month, 3 months and 6 months to evaluate the appearance of radiological and clinical pathological signs. The purpose behind this procedure is to avoid pulpotomy that affects pulp integrity, reduces tooth life span and increases economical coast in case of treatment failure.

It is hoped this study will succeed through the absence of clinical and radiological signs after 6 months and provide a promising alternative to pulpotomy.



Farah Sabbagh  
Fidel Nabbout

Department of Orthodontics and Dentofacial Orthopedics,  
Faculty of Dental Medicine, Lebanese University

## Correlation between Mandibular Third Molars Development and Skeletal Age

**Background.** Skeletal age determination is the key factor in deciding the optimal timing for treatment in dentofacial orthopedics. Although growth of jaw bones is known to be more correlated with skeletal age than dental or chronological ages, some authors indicate a “moderate relationship” between dental maturity and skeletal age. Third molars offer the advantage over other teeth due to their longer periods of development that last till late adolescence: an age range including most of the orthodontic patients. It was reported that root formation can also be influenced by many factors such as space available in the retromolar area and the axial inclination of the tooth itself, thus affecting the sought-after correlation with the skeletal age.

**Aim.** This study will highlight the correlation between third molar stage formation and skeletal age, considering the axial inclination of the bud and its available space on root development.

**Material and methods.** Records including panoramic and hand wrist x-rays were collected from the Orthodontic and Dentofacial Orthopedics Department in the Lebanese University. Skeletal age was determined using Greulich and Pyle method, and Nolla’s classification was used for third molars calcification stages. Third molars angulation and available space were evaluated on the panoramic radiographs.

**Conclusion.** The evaluation of mandibular third molar development on panoramic radiographs only could be sufficient and potentially used as growth predictor in different skeletal patterns, preventing the need for any additional radiological exposure.



Samer Salameh  
Charbel Choubaya

Department of Oral and Maxillofacial Surgery,  
Faculty of Dental Medicine, Lebanese University

## Computer-Guided Implant Surgery

**Objectives.** Recently, computer-guided surgery has been making its way onto the surgical files, due to the development of new technologies and softwares capable of combining 3D imaging with intraoral scanning giving an exact digital replica of all the anatomical structures, thus the possibility of having the perfect prosthetically-driven implant position. The aim of this study was to test these techniques.

**Material and methods.** A total of 3 cases were treated. The first case included a full lower arch implant extraction, immediate placement of 8 implants and immediate loading. The second case consisted of placing 2 implants in the region of teeth # 46 and 47. The third case was a completely edentulous mandible. It was decided that 4 implants would be placed for a future all on 4 full arch hybrid prosthesis. All the implants were Straumann® bone level implants.

**Results.** All 3 cases were successfully treated, since all templates were accurately fitted and there was no need for adjustments. All implants were positioned exactly as the predetermined protocol and there were no complications during the surgeries.

**Conclusion.** Computer-guided implant surgery is becoming more and more reliable with the advancement of the technology, becoming even more precise with complicated cases. However, there is always a need for improvement, since this technique has a big learning curve, needs a lot of presurgical planning, and is much more expensive compared to the non-guided implant surgery.



Corine Samaha<sup>1</sup>  
Jason Amatoury<sup>2</sup>  
Joseph Ghafari<sup>1</sup>

<sup>1</sup>Division of Orthodontics and Dentofacial Orthopedics,  
American University of Beirut

<sup>2</sup>Department of Biomedical Engineering, Maroun Semaan  
Faculty of Engineering and Architecture, American University of Beirut

## Craniofacial Characteristics of Young Adults with Obstructive Sleep Apnea: Case studies

**Background.** Obstructive sleep apnea (OSA) is a chronic disorder characterized by repeated episodes of partial or total closure of the upper airway during sleep. Obesity, male gender and age are primary risk factors, but young non-obese adults, particularly females, are underdiagnosed. Craniofacial factors are suspected to be the primary cause of their OSA.

**Aims.** To explore the anatomical differences between young adults with and without OSA.

**Methods.** Cephalometric and photographic records of patients with OSA were evaluated. Inclusion criteria were age ranging from 18 to 45 years, AHI (apnea-hypopnea index)  $\leq 5$  events/hr, normal BMI ( $<25$  kg/m<sup>2</sup>) and non-smoking habits. Patients were matched to healthy controls. Cephalometric measurements included craniofacial characteristics such as mandibular anteroposterior position, and upper and lower airway sagittal dimensions. Results. Within one year, 8 (2 females, 6 males; ages 22-45 years) out of 15 patients met the inclusion criteria and were diagnosed with mild ( $5 \leq \text{AHI} < 15$ ) to moderate ( $15 \leq \text{AHI} < 30$ ) OSA. All patients commonly featured mandibular retrognathism and reduced upper and lower pharyngeal dimensions when compared with healthy individuals. Following mandibular forward positioning with an OSA appliance, the patients reported improved quality of sleep and reduced daily fatigue and sleepiness. AHI was reduced in 2 patients who had post-appliance polysomnography.

**Conclusion.** While a less explored risk factor, mandibular retrognathism may be the predominant OSA risk factor in young individuals, particularly those lacking any of the common factors (obesity, gender, age, and smoking). Research is warranted on large samples to gauge the association between mandibular retrognathism and younger age.



Chadi Torbey<sup>1</sup>  
Eliane Jabbour<sup>1</sup>  
Prasanna Neelakantan<sup>2</sup>  
Hani Ounsi<sup>1</sup>

<sup>1</sup>Department of Restorative and Esthetic Dentistry and Endodontics  
Faculty of Dental Medicine, Lebanese University

<sup>2</sup>Faculty of Dentistry, University of Hong Kong

## A new Era in Endodontics: Adaptive Instruments

Root canal therapy is based on disinfecting a complex biological system. Until very recently, all endodontic instruments, whether stainless steel or NiTi, were simply based on the principle of drilling inside the canal space to create a conical shape that would allow for cleaning. However, this concept was not always capable of cleaning the anatomical intricacies of canal systems. Adaptive instrumentation is capable of more comprehensive shaping of the root canal preparation while improving disinfection. Paired with the cold hydraulic obturation technique, these instruments could pave the way for true minimally invasive endodontics.



Nancy Traboulsi  
Nahed Attia

Division of Periodontology, Faculty of Dentistry,  
Beirut Arab University

### Modified Palatal Roll Flap Technique for Peri-Implant Mucosa Reconstruction at Second-Stage Implant Surgery: Two Case Reports

**Introduction.** Main challenges after implant placement are bone and soft tissue loss with implant's abutment display. Correcting peri-implant soft tissue shrinkage in second stage surgery masked underlying minor to moderate ridge defects. Procedures as palatal roll flap, pouch roll and vascular inter-positional graft augmented soft tissues. Palatal roll flap modulation favored primary rather than secondary intention healing, reduced pain, bleeding and morbidity linked to palatal grafts.

**Material and methods.** Two cases were referred for second stage implant surgery at BAU specialty clinics. The first exhibited bony defect labial to an implant in zone of 13. While the second showed thin biotype and a narrow zone of buccal attached gingiva facing implants related to 23, 24 and 26. After anesthesia, 15c blade was used palatal to previously placed implant(s). An initial sharp epithelial incision preceded a bluntly reflected sub-epithelial connective tissue which was rolled and fixed under labial flap. An outer "trap door" was held by 5-0 resorbable PGA sutures. Recalls were done at one, four and eight weeks.

**Results.** No labial depression was clinically seen in first case. Thicker buccal keratinized tissues were formed in the second case. No post-surgical problem was noted. From an occlusal view, labio-palatal ridge width increased at first and fourth weeks with no marked difference between weeks four and eight.

**Conclusion.** Modified palatal roll flap is a minimally invasive connective tissue pedicle graft method that stabilizes reconstructed tissue volume around healing abutments and minimizes pink prosthetic camouflage.



Omar Zein  
Mohammad Badra  
Youssef Khatib  
Mohamed Shokry

Division of Oral Surgery, Faculty of Dentistry,  
Beirut Arab University

### A Recent Update for Oro-Antral Fistula Closure (Systematic Review)

Oro-antral fistula (OAF) is a pathological communication between the oral cavity and the maxillary sinus.

Patient complains of regurgitation of liquid from the nose, nasal resonance, cannot suck through straw, nasal discharge, bad taste in the mouth and whistling sound while speaking. At a later stage, we may have an antral polyp visible through the defect. Patient may experience pain in the molar area or it may be asymptomatic.

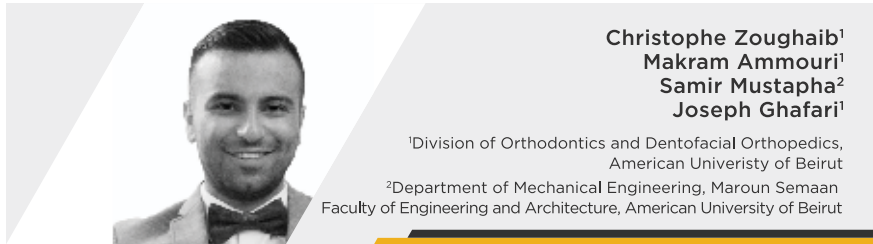
Clinically, a large fistula is easily seen on inspection. However, diagnosis of small defect can be made by the nose blowing test.

It originates either from iatrogenic complications during extraction of maxillary posterior teeth due to the proximity of the roots to the sinus (48%) or removal of maxillary cysts or tumor in the posterior region (18.5%) or from dental infection, osteomyelitis, radiation therapy, trauma (7.5%) following implant failure, osteoradionecrosis, flap necrosis and sometimes as a complication of the Caldwell-Luc procedure.

Defects less than 3 mm in width and without epithelization might heal spontaneously in the absence of infections. Communication wider than 5 mm require the intervention surgically to provide closure.

The most widely used types of flaps for the closure of an OAF are: buccal advancement flap, palatal pedicle flap and buccal fat pad flap. Alternative recent techniques are used in the management of OAF to be discussed.

This study is a systematic review, aimed to describe and compare the most reliable surgical techniques with the least complications used for the management of OAF explaining advantages and disadvantages of each.



#### Four Maxillary Posterior Intrusion Modalities: A finite Element Analysis

Orthodontic intrusion of over-erupted maxillary molars is facilitated when anchored on mini-implants (MIs), but the actual mechanics involved for predictable outcomes are not fully elaborated.

**Aims.** Evaluate through finite element analysis (FEA) the stresses generated by various intrusion modalities on the intruded and adjacent maxillary teeth.

**Methods.** In a 3D simulated model of the maxilla, four modalities of intrusion of posterior teeth were tested through FEA:

Model1: 1 buccal(B), 2 palatal(P)/ Model2: 2B, 1P/ Model3: 2B, 2P with force applied on brackets/ Model4: 2B, 2P with force applied on archwire. Variation in bone stiffness was introduced based on a prior study in 11 specimens, which were meshed in a specialized software (Simpleware®), then processed through the ABAQUS® 6.13 software. Intrusion forces were set at 400gms; stress levels were measured at the molar and adjacent teeth.

**Results.** Highest stress was concentrated on the root surface of the first premolar in all four modalities (1.2730.22 Pa), occurring more on its mesial aspect (1.3130.22 Pa); the least stress was on the second molar (0.4730.06 Pa). In model 4, stress was greatest (1.46 Pa) at the canine, reflecting the closeness of the load to the canine bracket. Stress patterns in the PDL varied with stiffness and differed significantly ( $p < 0.05$ ) among all sides of the teeth and across models.

**Conclusion.** The first premolar withstands the highest stresses, possibly because of its size and position in the arch. Compact bone stiffness affects the pattern of intrusion.

	Booth	Company
Ground Floor	A1	AEEDC
	A2	Picodente
	A3	Saad Medical Trading
	A4	GSK / Sensodyne
	A5	IBL Bank
	A6	Nepco / Colgate
	A7	Pharmacol
	A8	Dima Health Care
	A9	Richa Dental Store
	A10	Droguerie Tamer
	A11	Pierre Fabre Oral Care
	A12	Transmed
	A13	SDRC
	B3	Société Georges et Antoine Gannage
	B4	HCMMEDICA
	B5	Advanced Impco
	B6	Columbus / Listerine
	B8	Comeco
	B9	Hage Medical
	B10	Libateknica
B11-13	DMS	
B14-15	Prodent	
B16	Medicals International	
Underground Floor	C1	ADDUL
	C2	Dental News
	C3	Frankfurt University
	C7	Trident
	C11	Hachem Dental Care
	C17	Droguerie de l'Union
	C 19	Nashawy group
	C20	Assy Trading